

## SHORT COMMUNICATION

A Novel 5-bp Deletion Mutation in *AAGAB* Gene in a Chinese Family with Punctate Palmoplantar KeratodermaMing Li<sup>#</sup>, Xunyi Dai<sup>2#</sup>, Ruhong Cheng<sup>1</sup>, Lijia Yang<sup>2</sup>, Zhirong Yao<sup>1</sup> and Jiangbo Liu<sup>3</sup>Departments of Dermatology, <sup>1</sup>Xinhua Hospital, Shanghai Jiaotong University School of Medicine, 1665, Kongjiang Road, Shanghai 200092, <sup>2</sup>Wuxi No. 2 People's Hospital, Wuxi and <sup>3</sup>Bao'an Maternal and Child Health Hospital, Shenzhen, Guangdong, China. E-mail: aypyslm@163.com, liujiangbo126@126.com Accepted Jul 25, 2013; Epub ahead of print Oct 25, 2013<sup>#</sup>These authors contributed equally to this paper and should be considered as first authors.

Punctate palmoplantar keratoderma (PPPK, OMIM 148600), also known as Buschke-Fischer-Brauer's disease, is a rare autosomal dominant disorder. It is characterised by multiple tiny punctate keratoses on the surface of the palms and soles (1). The lesions usually start to develop in late childhood to adolescence, but even as late as middle age (2). PPPK can be associated with malignancies, such as lung cancer, Hodgkin's disease, breast cancer and prostatic carcinoma (3). In 2003, Martinez-Mir et al. (4) mapped the PPPK gene on chromosome 15q22–q24. Zhang et al. (5) performed the genome-wide linkage study in 2 Chinese families and identified 8q24.13–8q24.21 locus for PPPK in 2004. Gao et al. (6) and Mamaï et al. (7) refined localisation of a PPPK gene to a region at 15q22.2–15q22.31 and a locus to only 0.967 Mb at chromosome 15, respectively. Recently, pathogenic mutations of *AAGAB* and *COL14A1* genes in PPPK pedigrees have been reported (8–11).

## CASE REPORT

In this study, we investigated a 4-generation family from Jiangsu province of China comprising 44 individuals, including 7 with

typical PPPK features (Fig. 1a). It showed an autosomal dominant inheritance pattern with full penetrance. The proband (III:12 in the pedigree) of this family is a 48-year-old woman. She developed asymptomatic punctate keratoses on the surface of palms and soles at the age of 18 years old. The lesions gradually increased in diameter with age and coalesced with each other (Fig. 1b, c). All affected individuals in this family had the similar manifestation. No abnormalities in the nails, teeth and eyes were noted in all affected individuals. The patients in this family could not be associated with malignancy.

After informed consent, genomic DNA was extracted from the patient's peripheral blood lymphocytes. We analysed *AAGAB* and *COL14A1* genes of this family by direct sequencing using primers and reaction conditions as previously described (8, 11). In addition, samples from 100 unrelated population-matched controls were sequenced for mutation to exclude the possibility that it is polymorphism in the *AAGAB* gene. Mutation was identified by comparing with the reported cDNA reference sequence (GenBank accession number: NM\_024666.3). This study was approved by the Ethics Committees of Shanghai Jiaotong University School of Medicine and conducted in accordance with the principles of the Declaration of Helsinki.

Sequencing results revealed a novel frameshift mutation c.313\_317delTGGTT in exon 3 of *AAGAB*, which results in the mutation of p.Trp105Thrfs\*2 (Fig. 1d, e). This mutation segregated clearly with the disease phenotype within the family members, and it was not detected in 100 unrelated, healthy Chinese individuals (200 alleles).

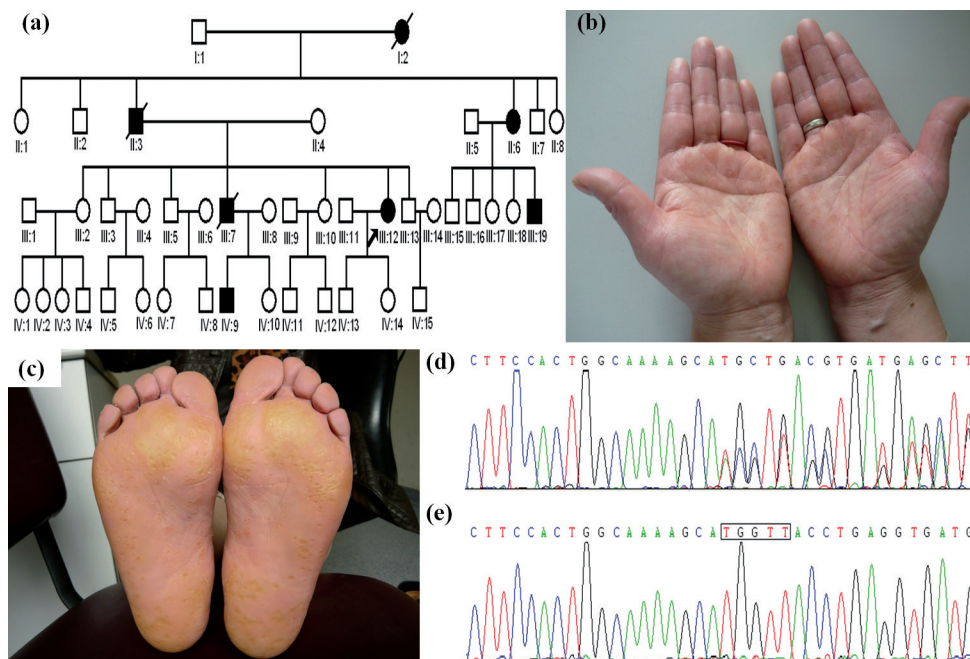


Fig. 1. Clinical characteristics of the proband and mutation of *AAGAB* gene. (a) Pedigree of a Chinese family with punctate palmoplantar keratoderma. Arrow marks the proband. (b) Multiple punctate keratoses over the surface of the palms of proband. (c) Multiple punctate keratoses over the surface of the soles of proband. (d) Heterozygous transition mutation c.313\_317delTGGTT resulting in frameshift mutation p.Trp105Thrfs\*2. (e) Part of the normal sequence from exon 3 of *AAGAB* gene. The box indicates the 5-bp deletion in this family.

## DISCUSSION

*AAGAB* gene spans 53.7 kb and contains 10 exons. It encodes  $\alpha$ - and  $\gamma$ -adaplin binding protein p34. It is composed of 315 amino acid residues. Protein p34 contains two functional domains: Rab-like GTPase domain in its N-terminal half and adaplin-binding domain in its C-terminal half. They are located in exons 2–4 and exons 5–10, respectively (11, 12). Rab-like GTPase domain might play an important role in membrane trafficking as a chaperone (10–12). The adaplin-binding domain of the  $\alpha$ - and  $\gamma$ -adaplin binding protein p34 is located in the coding region between amino acids 157 and 294, which is approximately 43% of the full length of the protein, and functions as the binding site with NH<sub>2</sub>-terminal domains of  $\alpha$ - and  $\gamma$ -adaplin (11, 12).

To date, 12 *AAGAB* mutations have been reported in European, African and Asian populations (9–11). Four mutations are in the Rab-like GTPase domain, 3 mutations are within the adaplin-binding domain and 4 mutations lie upstream of the Rab-like GTPase domain. In the current study, we identified a novel heterozygous frameshift mutation c.313\_317delTGGTT (p.Trp105Thrfs\*2) of the *AAGAB* gene. This mutation leads to a premature termination at amino acid position 106. The predicted mutant protein includes half of the Rab-like GTPase domain, but loses the entire adaplin-binding domain, which should be an inactive  $\alpha$ - and  $\gamma$ -adaplin-binding protein p34. Pohler et al. (11) reported protein p34 expression in skin and HaCaT cells. They speculated that PPPK might be caused by haploinsufficiency of the  $\alpha$ - and  $\gamma$ -adaplin-binding protein p34 activity and protein p34 deficiency may lead to increased signalling and cellular proliferation (11). Giehl et al. (10) reported that  $\alpha$ - and  $\gamma$ -adaplin-binding protein p34 plays an important role in skin integrity. These results supported a role for *AAGAB* in the pathogenesis of PPPK.

## ACKNOWLEDGEMENTS

We thank all subjects for their ongoing participation in this study. This study was funded by a grant from Shanghai Municipal Natural Science Foundation (#12ZR1420000).

## REFERENCES

1. Stevens HP, Kelsell DP, Leigh IM, Ostlere LS, MacDermot KD, Rustin MH. Punctate palmoplantar keratoderma and malignancy in a four-generation family. *Br J Dermatol* 1996; 134: 720–726.
2. Emmert S, Küster W, Hennies HC, Zutt M, Haenssle H, Kretschmer L, et al. 47 patients in 14 families with the rare genodermatosis keratosis punctata palmoplantaris Buschke-Fischer-Brauer. *Eur J Dermatol* 2003; 13: 16–20.
3. Ena P, Cottoni F, Cerimele D, Saccabusi S, Retanda G. Association of keratoderma punctata palmaris et plantaris with other morbid conditions (early grayness, carcinoma of the colon). Study of 3 families. *G Ital Dermatol Venereol* 1986; 121: 45–54.
4. Martinez-Mir A, Zlotogorski A, Londono D, Gordon D, Grunn A, Uribe E, et al. Identification of a locus for type I punctate palmoplantar keratoderma on chromosome 15q22-q24. *J Med Genet* 2003; 40: 872–878.
5. Zhang XJ, Li M, Gao TW, He PP, Wei SC, Liu JB, et al. Identification of a locus for punctate palmoplantar keratoderma at chromosome 8q24.13-8q24.21. *J Invest Dermatol* 2004; 122: 1121–1125.
6. Gao M, Yang S, Li M, Yan KL, Jiang YX, Cui Y, et al. Refined localization of a punctate palmoplantar keratoderma gene to a 5.06-cM region at 15q22.2-15q22.31. *Br J Dermatol* 2005; 152: 874–878.
7. Mamaï O, Boussofara L, Adala L, Amara A, Ben Charfeddine I, Ghariani N, et al. Reduction of palmoplantar keratoderma Buschke-Fischer-Brauer locus to only 0.967Mb. *J Dermatol Sci* 2012; 67: 210–212.
8. Guo BR, Zhang X, Chen G, Zhang JG, Sun LD, Du WD, et al. Exome sequencing identifies a COL14A1 mutation in a large Chinese pedigree with punctate palmoplantar keratoderma. *J Med Genet* 2012; 49: 563–568.
9. Li M, Yang L, Shi H, Guo B, Dai X, Yao Z, et al. Loss-of-function mutation in *AAGAB* gene in Chinese families with punctate palmoplantar keratoderma. *Br J Dermatol* 2013; 169: 168–171.
10. Giehl KA, Eckstein GN, Pasternack SM, Praetzel-Wunder S, Ruzicka T, Lichtner P, et al. Nonsense mutations in *AAGAB* cause punctate palmoplantar keratoderma type Buschke-Fischer-Brauer. *Am J Hum Genet* 2012; 91: 754–759.
11. Pohler E, Mamaï O, Hirst J, Zamiri M, Horn H, Nomura T, et al. Haploinsufficiency for *AAGAB* causes clinically heterogeneous forms of punctate palmoplantar keratoderma. *Nat Genet* 2012; 44: 1272–1276.
12. Page LJ, Sowerby PJ, Lui WW, Robinson MS. Gamma-synergisin: an EH domain-containing protein that interacts with gamma-adaplin. *J Cell Biol* 1999; 146: 993–1004.