

## SHORT COMMUNICATION

## Apocrine Hidrocystoma of the Urethral Meatus: A Case Report

Drew Taylor<sup>1</sup>, Mark E. Juhl<sup>2\*</sup>, Aleksandar L. Kronic<sup>1</sup>, Michael Sidiropoulos<sup>3</sup> and Pedram Gerami<sup>3</sup><sup>1</sup>Department of Dermatology, <sup>2</sup>College of Medicine, The University of Illinois, 1853 W. Polk St., Chicago, IL 60612, and <sup>3</sup>Department of Dermatopathology, Northwestern University, Chicago, USA. \*E-mail: mark.e.juhl@gmail.com

Accepted Jun 30, 2014; Epub ahead of print Jun 30, 2014

Apocrine hidrocystomas (cystadenomas) are cystic cutaneous neoplasms derived from apocrine sweat glands (1, 2), and they most often present in adults as solitary (rarely multiple) lesions involving the head, eyelids and neck (3). They are also reported infrequently in the apocrine gland bearing areas like axillae, areola of the nipple, periumbilical, anal, and genital areas (3, 4). We present a rare case of apocrine hidrocystoma located at the urethral meatus of a 16-year-old male.

## CASE REPORT

A 16-year-old male presented to our clinic with a slowly growing lesion located on the glans penis. The patient had no significant past medical history, and was otherwise asymptomatic. On physical examination, he had an 8 mm wide bluish translucent cyst at the ventral urethral orifice (Fig. 1). The lesion was excised under local anesthesia with an uneventful post-operative course. Pathologic evaluation revealed a dilated cystic structure with compact fibrous stroma and lined by cuboidal epithelial cells showing apocrine decapitation secretion with an outer layer composed of flattened myoepithelial cells (Fig. 2a). Hyperplasia of the inner lining of the cyst wall with papillary projections and folding was also noted (Fig. 2b). Secretory cells were positive by immunohistochemistry for androgen receptor and gross cystic disease fluid protein 15 (GCDFP-15) (Fig. 2c) and the myoepithelial layer was positive for p63. A DPAS stain was positive for granules in secretory cells. S-100 protein was negative. The findings were consistent with a benign apocrine hidrocystoma.

## DISCUSSION

Apocrine hidrocystomas are benign tumors most often seen in adults aged 30 to 70 and rarely during childhood or adolescence. They are generally single, but can also

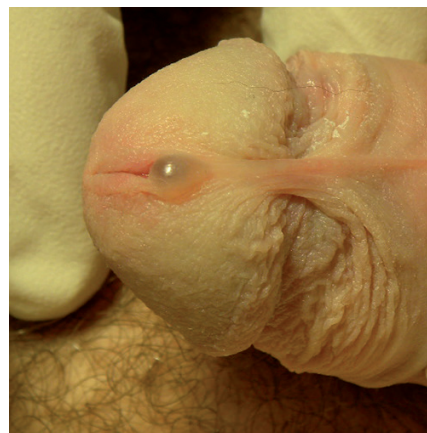

Fig. 1. An 8 mm wide bluish cystic lesion at the urethral meatus.

appear as multiple lesions (1, 5). The clinical presentation is a dome-shaped, solitary, clear cystic nodule with a smooth surface (1). Ranging in size from 5 to 20 mm, the lesions tend to be asymptomatic and follow a gradual course until a certain size is reached (1, 5).

Genital localization (penis, scrotum, and labia majora) is very rare with only a few cases reported in the literature (6–9). This is the second reported case of this lesion at the urethral meatus (8, 9).

In the genital region, they most likely derive from ectopic apocrine gland tufts (5, 7–9). Histologically, they are unilocular or multilocular with an inner cyst wall composed of one to two layers of secretory cuboidal-columnar epithelium lying on an outer myoepithelial cell layer. Papillary projections and decapitation secretion typical of normal apocrine glands is regularly seen. Histochemically, apocrine hidrocystomas have periodic

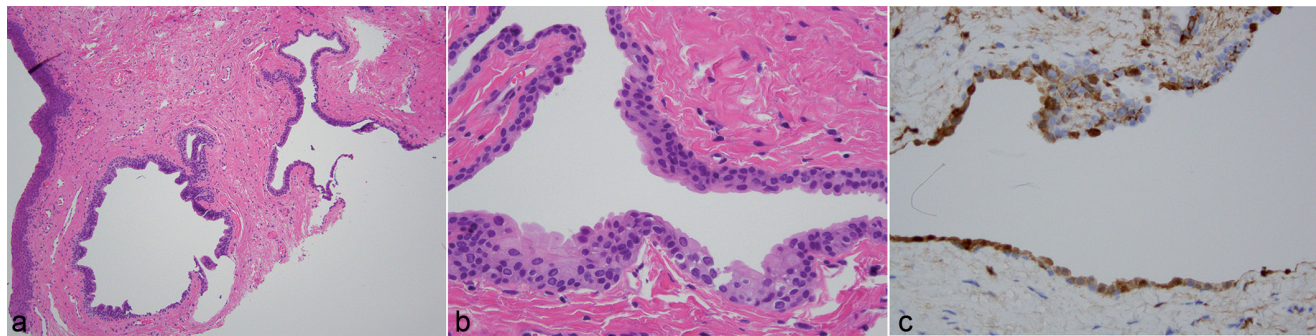


Fig. 2. Low power view demonstrating multilocular cystic spaces situated within the dermis (a) ( $\times 10$ ). Cystic space lined by flattened myoepithelial cells and tall columnar cells with abundant eosinophilic cytoplasm and decapitation secretion (b) ( $\times 20$ ). The outer secretory cells express gross cystic disease fluid protein 15 (GCDFP-15) consistent with apocrine hidrocystoma ( $\times 40$ ) (c).

acid-Schiff positive granules and are S100 protein negative (1).

When lesions are in the genital area the differential diagnosis includes eccrine hidrocystoma, congenital cysts of the median raphe, and lymphangioma (7). Eccrine hidrocystomas can present in an identical fashion but are considered true retention cysts and usually lack secretory epithelium and papillary projections. Histochemically they lack periodic acid-Schiff positive granules and are S100 protein positive (1, 5, 7–9). Congenital cysts of the median raphae are generally asymptomatic until after puberty and usually became apparent secondary to trauma or infection (7). The cysts are lined by a pseudostratified columnar epithelium with no decapitation, although a mixture of epidermoid and glandular histology has also been reported (7, 10). Acquired lymphangioma occurs after alteration in deep lymphatic drainage and usually appears as multiple small vesicles or blebs filled with clear fluid or blood. Histologically, it has multiple dilated lymphatic channels in the superficial dermis (7).

Treatment of single apocrine hidrocystomas typically is surgical excision with narrow margins due to the benign nature of the lesion (7, 9). The location at the urethral meatus with possible extension into the urethra and interference with the urination, as well as lower risk of recurrence rendered surgical removal the best option for our patient. Alternative therapies include electrodesiccation, incision and drainage, simple puncture, topical 1% atropine or scopolamine creams, or carbon dioxide

laser vaporization. However, these alternative methods may be followed by higher recurrence rates (1, 6, 8, 9).

## REFERENCES

1. Sarabi K, Khachemoune A. Hidrocystomas – a brief review. *MedGenMed* 2006; 8: 57.
2. Vani D, Dayananda TR, Shashidhar HB, Bharathi M, Kumar HR, Ravikumar V. Multiple apocrine hidrocystomas: a case report. *J Clin Diagn Res* 2013; 7: 171–172.
3. Housholder AL, Plotner AN, Sheth AP. Multiple axillary papules in an infant: multiple apocrine hidrocystomas. *Pediatr Dermatol* 2013; 30: 491–492.
4. Saga K. Structure and function of human sweat glands studied with histochemistry and cytochemistry. *Prog Histochem Cytochem* 2002; 37: 323–386.
5. Anzai S, Goto M, Fujiwara S, Da T. Apocrine hidrocystoma: a case report and analysis of 167 Japanese cases. *Int J Dermatol* 2005; 44: 702–703.
6. Lopez V, Alonso V, Jorda E, Santonja N. Apocrine hidrocystoma on the penis of a 40-year-old man. *Int J Dermatol* 2013; 52: 502–504.
7. Mataix J, Banuls J, Blanes M, Pastor N, Betlloch I. Translucent nodular lesion of the penis. Apocrine hidrocystoma of the penis. *Arch Dermatol* 2006; 142: 1221–1226.
8. Liu YS, Wang JS, Li TS. A 25-year-old man with a dome-shaped translucent nodule on the glans penis. *Dermatologica Sinica* 2010; 28: 177–178.
9. Samplaski MK, Somani N, Palmer JS. Apocrine hidrocystoma on the glans penis of a child. *Urology* 2009; 73: 800–801.
10. Shao IH, Chen TD, Shao HT, Chen HW. Male median raphe cysts: serial retrospective analysis and histopathologic classification. *Diagn Pathol* 2012; 7: 121.