

## SHORT COMMUNICATION

Darier's Disease: A novel *ATP2A2* Missense Mutation at One of the Calcium-binding ResiduesKana Kaibuchi-Noda<sup>1</sup>, Kazumitsu Sugiura<sup>1</sup>, Takuya Takeichi<sup>1</sup>, Shunsuke Miura<sup>2</sup>, Shinji Kagami<sup>2</sup>, Hiromichi Takama<sup>3</sup>, Haruko Hino<sup>2</sup> and Masashi Akiyama<sup>1\*</sup>Departments of Dermatology, <sup>1</sup>Nagoya University Graduate School of Medicine, 65 Tsurumai-cho, Showa-ku, Nagoya 466-8550 and <sup>2</sup>Kanto Central Hospital, Setagaya-ku, Tokyo, and <sup>3</sup>Takama Dermatology Clinic, Kasugai, Japan. \*E-mail: makiyama@med.nagoya-u.ac.jp  
Accepted Jun 30, 2014; Epub ahead of print Jun 30, 2014

Darier's disease (DD) is a rare autosomal dominantly inherited skin disorder caused by a heterozygous mutation in *ATP2A2*, which is expressed in both the skin and the brain and encodes for type 2 sarcoendoplasmic reticulum Ca-ATPase (SERCA2) (OMIM 124200). Gain of function due to Ca<sup>2+</sup> leakage was suggested as the mechanism behind how the mutations cause DD (1). DD sometimes shows neuropsychiatric manifestations. Herein, we report a Japanese patient with DD, who has a novel mutation in one of the Ca<sup>2+</sup>-binding residues (CBR) in the endoplasmic reticulum (ER) membrane. A review of the literature on *ATP2A2* mutations in CBR and DD phenotypes suggested differences between the mutations in terms of the accompanying symptoms.

## CASE REPORT

A 40-year-old woman with no familial history of DD or other serious comorbidities was admitted. Physical examination showed reddish papules on her back and breast (Fig. 1A, B). Histopathology of the papule on the back revealed suprabasal acantholysis with corps ronds and grains (Fig. 1C). Treatment with etretinate effectively resolved the skin lesions.

Following ethical approval, informed written consent was obtained from the patient in compliance with the Declaration of Helsinki guidelines. The coding regions including exon-intron boundaries of *ATP2A2* were amplified from genomic DNA by PCR as described elsewhere (2). Direct sequencing of the patient's PCR products revealed the heterozygous missense mutation c.2721A>C (p. Glu907Asp) (Fig. 1D). The glutamine residue at 907, which plays an important role in Ca<sup>2+</sup> transportation, was confirmed to be highly conserved in

*ATP2A2* from diverse mammalian species (Fig. S1A<sup>1</sup>). c.2721A>C was not detected in any of the 200 control alleles (100 control individuals) (data not shown). Thus, the patient was diagnosed as having DD with the heterozygous *ATP2A2* mutation.

## DISCUSSION

SERCA2 normally pumps Ca<sup>2+</sup> from the cytoplasm to the ER. SERCA2 has 2 splice forms: SERCA2a and

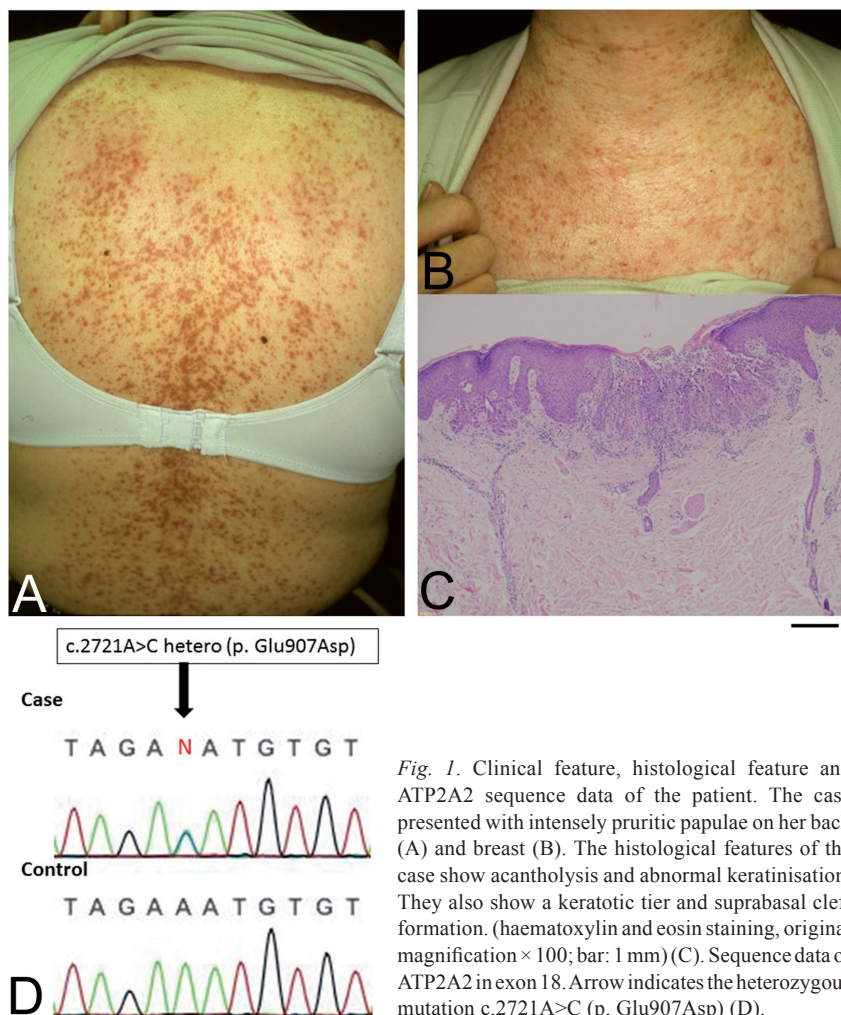
<sup>1</sup><http://www.medicaljournals.se/acta/content/?doi=10.2340/00015555-1927>

Fig. 1. Clinical feature, histological feature and *ATP2A2* sequence data of the patient. The case presented with intensely pruritic papulae on her back (A) and breast (B). The histological features of the case show acantholysis and abnormal keratinisation. They also show a keratotic tier and suprabasal cleft formation. (haematoxylin and eosin staining, original magnification  $\times 100$ ; bar: 1 mm) (C). Sequence data of *ATP2A2* in exon 18. Arrow indicates the heterozygous mutation c.2721A>C (p. Glu907Asp) (D).

SERCA2b. SERCA2a is restricted to the slow-twitch skeletal and cardiac muscles, whereas SERCA2b is ubiquitously expressed, and expressed especially highly in keratinocytes. SERCA2b has 11 ER transmembrane domains (TM) and 10 CBR. CBR is necessary for Ca<sup>2+</sup> transport (Fig. S1B<sup>1</sup>, Table SI<sup>1</sup>). Each CBR seems to have different levels of importance for Ca<sup>2+</sup> transport (3).

Three mutations causing amino acid alterations of 2 CBR (p.Asn767 and p.Asn795) have been reported (Table SI<sup>1</sup>) (4–7). p.Asn767Ser was found in 4 cases of severe DD accompanied by neuropsychiatric symptoms or haemorrhages in the skin lesions, which suggests severe dysfunction of SERCA2 by the mutation. However, p.Asn767Asp is found in DD without accompanying symptoms. p.Asn795Ser was found in a DD patient whose phenotype was not described in detail. p.Glu907Asp, found in the present case, was the fourth mutation at CBR to be reported in the literature.

In conclusion, the present case and previous cases suggest that even missense *ATP2A2* mutations at CBR do not always cause severe DD with accompanying symptoms. This may be because each CBR differs in its importance to Ca<sup>2+</sup> transport.

## REFERENCES

1. Kaneko M, Desai BS, Cook B. Ionic leakage underlies a gain-of-function effect of dominant disease mutations affecting diverse P-type ATPases. *Nat Genet* 2014; 46: 144–151.
2. Sakuntabhai A, Ruiz-Perez V, Carter S, Jacobsen N, Burge S, Monk S, et al. Mutations in *ATP2A2*, encoding a Ca<sup>2+</sup> pump, cause Darier disease. *Nat Genet* 1999; 21: 271–277.
3. Sugita Y, Ikeguchi M, Toyoshima C. Relationship between Ca<sup>2+</sup>-affinity and shielding of bulk water in the Ca<sup>2+</sup>-pump from molecular dynamics simulations. *Proc Natl Acad Sci U S A* 2010; 107: 21465–21469.
4. Ruiz-Perez VL, Carter SA, Healy E, Todd C, Rees JL, Steijlen PM, et al. *ATP2A2* mutations in Darier's disease: variant cutaneous phenotypes are associated with missense mutations, but neuropsychiatric features are independent of mutation class. *Hum Mol Genet* 1999; 8: 1621–1630.
5. Jacobsen NJ, Lyons I, Hoogendoorn B, Burge S, Kwok PY, O'Donovan MC, et al. *ATP2A2* mutations in Darier's disease and their relationship to neuropsychiatric phenotypes. *Hum Mol Genet* 1999; 8: 1631–1636.
6. Ikeda S, Mayuzumi N, Shigihara T, Epstein EH, Jr., Goldsmith LA, Ogawa H. Mutations in *ATP2A2* in patients with Darier's disease. *J Invest Dermatol* 2003; 121: 475–477.
7. Ren YQ, Gao M, Liang YH, Hou YX, Wang PG, Sun LD, et al. Five mutations of *ATP2A2* gene in Chinese patients with Darier's disease and a literature review of 86 cases reported in China. *Arch Dermatol Res* 2006; 298: 58–63.