

SHORT COMMUNICATION

Cutaneous Cryptococcosis Mimicking Pyoderma Gangrenosum: A Report of Four Cases

Nobuyuki Kikuchi, Tomoko Hiraiwa, Masato Ishikawa, Tatsuhiko Mori, Shohei Igari, Yuka Hanami, Takako Miura, Mikio Ohtsuka and Toshiyuki Yamamoto

Department of Dermatology, Fukushima Medical University, Hikarigaoka 1, Fukushima 960-1295, Japan. E-mail: nobuyuk@fmu.ac.jp

Accepted May 27, 2015; Epub ahead of print Jun 3, 2015

Cryptococcosis is a fungal infection caused by *Cryptococcus neoformans*, and frequently presents with meningitis, pneumonia, and cutaneous eruptions in immunocompromised patients. Clinical features of cutaneous cryptococcosis vary; thus, it is necessary to suspect the disease and perform a skin biopsy in order to make an early and accurate diagnosis. We herein report 4 cases of cutaneous cryptococcosis presenting with pyoderma gangrenosum-like appearance.

CASE REPORT

Case 1. An 85-year-old woman was admitted to hospital, complaining of fever, as well as ulcers on the face, neck, and upper extremities. She had been suffering from erythroderma and was treated with prednisolone (20 mg/day) for the previous year. Physical examination revealed deep irregular ulcers with necrosis on the upper extremities (Fig. 1a) and nodular lesions with crusts on the neck. In addition, erythema and hemorrhagic blisters were found on the left lower leg. Laboratory examination showed leukocytosis (10,400/ μ l), elevated C-reactive protein (CRP) (4.21 mg/dl) and β -D-glucan (56.1 pg/dl: normal 0–11) levels, and positive *C. neoformans* antigen. Histological examination revealed granulomatous inflammation infiltrated with lymphocytes and histiocytes, and degeneration of the dermis and subcutaneous fat tissues. Numerous rounded fungal bodies positively stained by PAS and Grocott were found in the subcutaneous fat tissue. Microbiological culture from ulcer exudate showed *C. neoformans*. Examination by computed tomography (CT) revealed pneumonia, and a cerebral abscess was detected by magnetic resonance imaging (MRI). The ulcers healed after intravenous administration of fluconazole (200 mg/day), however the patient died of sepsis.

Case 2. A 74-year-old woman presented with an ulcer on the right lower leg that had appeared 6 months previously. She had been treated at an internal medicine clinic, but the ulcer deteriorated. She was also suffering from diabetes mellitus, chronic kidney disease and bronchial asthma. Physical examination revealed irregular ulcers with necrosis on the right lower leg (Fig. 1b). Laboratory examination showed a normal white blood cell count (7,500/ μ l), elevated CRP (0.97 mg/dl) and β -D-glucan (12.4 pg/dl) levels, and positive *C. neoformans* antigen. Histological examination revealed inflammatory infiltrates of lymphocytes and histiocytes in the dermis, and a number of fungal bodies stained with PAS, Grocott, and mucicarmine were found in the dermis (Fig. 2). Culture from ulcer exudates as well as blood verified *C. neoformans*. Chest CT revealed pneumonia, and two weeks after administration, she died of respiratory failure.

Case 3. A 93-year-old woman was hospitalized, complaining of redness and swelling of the thighs for the previous month. She had been treated without response with antimicrobial drugs. Physical examination revealed irregular deep ulcers with necrosis on the right thigh (Fig. 1c). Laboratory examination showed leukocytosis (11,680/ μ l), elevated CRP (4.24 mg/dl) level, normal β -D-glucan (<0.6 pg/dl) levels, and positive *C. neoformans* antigen. A biopsy specimen revealed dense granulomatous inflammation infiltrated with a number of neutrophils and lymphohistiocytic cells in the dermis and subcutaneous fat tissues. Fungal bodies stained with PAS and Grocott were mainly found in the dermis and subcutaneous fat tissues. Culture of ulcer exudates revealed *C. neoformans*. The patient was treated with intravenous fluconazole (100 mg/day), and the ulcer on the right thigh healed. However, during treatment, she developed pneumonia and died.

Case 4. A 79-year-old woman presented with an ulcer on the left lower leg of two months' duration. She had been treated at a clinic, but the ulcer spread. She was also suffering from rheumatoid

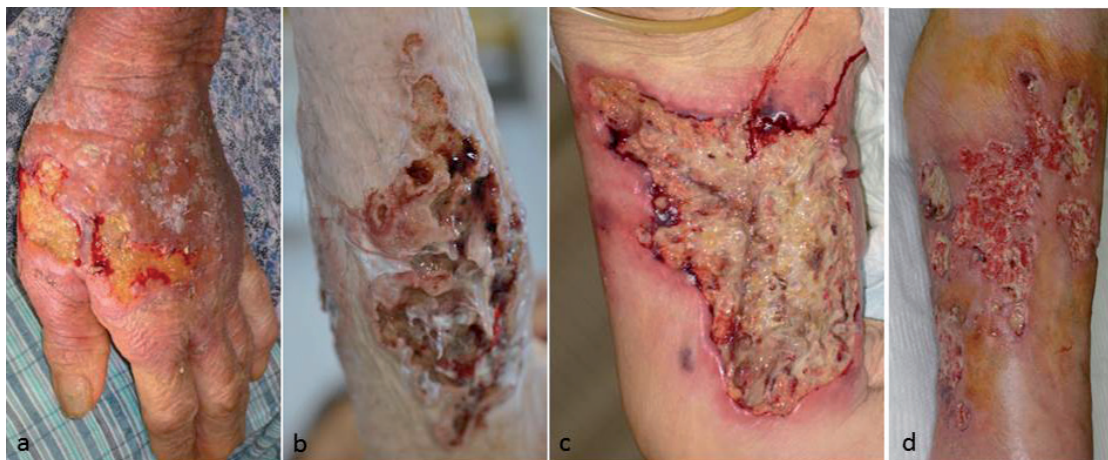

Fig. 1. Deep ulcerations on the (a) dorsa of the hand (Case 1), (b) lower leg (Case 2) (c) thigh (Case 3) and (d) lower leg (Case 4).

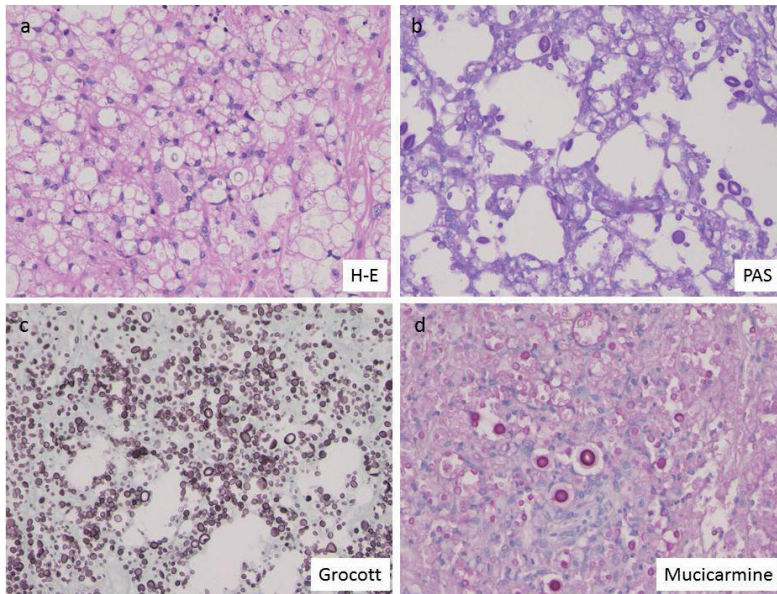


Fig. 2. Biopsy specimen from Case 2 showed a number of spores with thick-walled capsules (a) (haematoxylin-eosin, $\times 200$), which were positive for PAS (b) ($\times 200$), Grocott (c) ($\times 200$), and mucicarmine (d) ($\times 200$).

arthritis, for which she received methotrexate and prednisolone, and diabetes mellitus. Physical examination revealed irregular ulcers with necrosis on the left lower leg. Laboratory examination showed leukocytosis (11,600/ μ l), elevated CRP (0.43 mg/dl), normal β -D-glucan (< 0.6 pg/dl) levels, and positive *C. neoformans* antigen (1:1024 (latex agglutination test)). Histological findings of the ulcer revealed inflammatory infiltrates of neutrophils in the dermis. A number of fungal bodies stained with PAS, Grocott, and mucicarmine were found in the dermis. Culture of skin ulcer exudates and the blood yielded *C. neoformans*. Pneumonia was detected by CT, but improved along with the ulcers after initiation of intravenous fluconazole (400 mg/day).

DISCUSSION

Cutaneous cryptococcosis presents with various clinical symptoms such as papules, pustules, nodules, granulomas, abscesses, subcutaneous swelling, cellulitis-like erythema, erysipelas, and ulcers. To date, only a few cases with clinical features mimicking pyoderma gangrenosum have been reported (1, 2). In one of those cases, a 33-year-old man with ulcerative colitis developed pyoderma gangrenosum-like lesions on the shoulder, chest, arm, and thigh (1). However, cultures from those lesions all yielded *C. neoformans*. By contrast, another case showed a granulomatous lesion on the dorsum of hands (2). However, the ulceration was neither deep nor undermined (2). Our cases presented with multiple deep ulcers on the upper and lower extremities. These cases had been misdiagnosed as erythroderma, cellulitis, and initially skin ulcers, and treated in other hospitals. In our hospital, the diagnosis of cryptococcosis was made using histological and mycological examination. Cryptococcus infection primarily involves the lung by in-

halation, and sometimes involves the skin (10–20%) as well as the central nervous system, and is therefore life-threatening especially in immunocompromised individuals. Multiple organs were infected in our cases, and antimycotic therapies resulted in failure in 3 out of the 4 cases. Only Case 4 survived following early initiation of systemic treatment.

Cutaneous cryptococcosis is an opportunistic infection, and occasionally involves immunocompromised hosts, such as patients with HIV infection, hepatitis C virus infection, lymphomas, systemic lupus erythematosus, and transplant recipients receiving immunosuppressive therapies (3–7). Case 1, who had been suffering from erythroderma, and was immunosuppressed with systemic prednisolone therapy. Case 2 had diabetes mellitus and chronic renal failure, and Case 3 was elderly. Case 4 had been suffering from rheumatoid arthritis and diabetes mellitus, and was also in

an immunosuppressive state under treatment with systemic prednisolone and methotrexate. None of our patients had a known history of contact with pigeons. Cryptococcosis should be taken into consideration as one possible differential diagnosis of refractory deep ulcers, especially in immunosuppressed patients.

The authors declare no conflict of interest.

REFERENCES

1. Massa MC, Doyle JA. Cutaneous cryptococcosis simulating pyoderma gangrenosum. *J Am Acad Dermatol* 1981; 5: 32–36.
2. Jasch KC, Hermes B, Scheller U, Harth W. Pyoderma gangrenosum-like primary cutaneous cryptococcosis. *Acta Derm Venereol* 2008; 88: 76–77.
3. Murakawa GJ, Kershmann R, Berger T. Cutaneous cryptococcosis infection and AIDS: report of 12 cases and review of literature. *Arch Dermatol* 1996; 132: 545–548.
4. Romano C, Taddeucci P, Donati D, Miracco C, Massai L. Primary cutaneous cryptococcosis due to *Cryptococcus neoformans* in a woman with non-Hodgkin's lymphoma. *Acta Derm Venereol* 2001; 81: 220–221.
5. Ueno T, Kume H, Mitsuishi T, Morimoto K, Kikuchi I, Kawana S. Systemic lupus erythematosus-associated cutaneous cryptococcosis treated successfully with an intermittent 3-day on/off cycle of itraconazole. *J Dermatol* 2008; 35: 778–781.
6. Van Griek SA, Dupont LJ, Van Raemdonck DE, Van Bleyenbergh P, Verleden GM. Primary cryptococcal cellulitis in a lung transplant recipient. *J Heart Lung Transplant* 2007; 26: 285–289.
7. Miura T, Kawakami Y, Otsuka M, Hachiya M, Yamanoi T, Ohashi K, et al. Cutaneous cryptococcosis in a patient with cirrhosis and hepatitis C virus infection. *Acta Derm Venereol* 2010; 90: 106–107.