

CLINICAL REPORT

A Retrospective Study of Treatment of Squamous Cell Carcinoma *In situ*

Meri ÖVERMARK, Sari KOSKENMIES and Sari PITKÄNEN

Department of Dermatology, Skin Cancer Unit, Helsinki University Central Hospital, Helsinki, Finland

Squamous cell carcinoma *in situ* is an intra-epidermal malignancy of the skin with potential to progress to invasive carcinoma. Commonly used treatments are surgical excision, cryotherapy, photodynamic therapy, laser ablation, curettage with cautery, radiotherapy, topical 5-fluorouracil, and topical imiquimod. The efficacies of these different treatment modalities are compared in this retrospective study of 239 patients with squamous cell carcinoma *in situ* diagnosed and treated at our hospital during a period of 1 year. A total of 263 histologically confirmed *in situ* lesions were followed up for approximately 8 years. The overall recurrence rate was 6.5%. Surgical excision had the lowest recurrence rate, at 0.8%. Recurrence rates with the less-invasive treatment modalities were markedly higher; cryotherapy 4.7% and photodynamic therapy 18%. Of all recurrences, 65% were carcinoma *in situ* and 35% squamous cell carcinomas. Twenty-three patients had actinic keratosis in the area treated, but these were not counted as recurrences. In conclusion, excisional surgery is the gold standard treatment for squamous cell carcinoma *in situ*, although it has limitations. Less invasive methods may sometimes be preferred. **Key words: squamous cell carcinoma *in situ*, Bowen's disease; cryotherapy; photodynamic therapy; imiquimod; retrospective study.**

Accepted Jun 11, 2015; Epub ahead of print Jun 15, 2015

Acta Derm Venereol 2016; 96: 64–67.

Meri Övermark, Department of Dermatology, Skin Cancer Unit, Helsinki University Central Hospital, FIN-00029 Helsinki, Finland. E-mail: meri.overmark@hus.fi

Squamous cell carcinoma *in situ* (carcinoma *in situ*, Bowen's disease), an intraepidermal malignancy of the skin, usually presents as a well-demarcated growing erythematous patch or plaque with a scaly or crusted surface. Carcinoma *in situ* lesions can be pigmented or verrucous, and are not constantly ulcerated. Clinically the lesions may be difficult to distinguish from actinic keratosis, superficial basocellular carcinoma (BCC), squamous cell carcinoma (SCC), psoriasis, or nummular eczema. Histological findings in carcinoma *in situ* are hyperkeratosis and parakeratosis with full-thickness atypia of epidermal keratinocytes; histologically, it does not

invade through the basement membrane into the dermis. No differential diagnosis can be made between carcinoma *in situ* and invasive SCC if the biopsy from the lesion is too superficial or does not represent the tumour's invasive part. The risk of progression of any *in situ* lesion into an invasive SCC ranges from 3% to 5% (1). In the Caucasian population, carcinoma *in situ* is very common, with an incidence of 14.9–27.8 per 100,000 (2, 3). In Finland, carcinoma *in situ* is not included in the National Cancer Registry, and therefore the incidence in our population is unknown. Finnish people are Caucasians, the most common skin type is Fitzpatrick type III (60%), 30% are types I and II and 10% type IV.

In Finland approximately 1,600 new SCCs occur annually (4). The major aetiological factors in the development of SCC and carcinoma *in situ* of the skin are ultraviolet (UV) radiation and accumulation of UV radiation over time. Additional risk factors are fair skin, exposure to arsenic, and immunosuppression (5). According to the literature, 30–50% of patients with carcinoma *in situ* have a history of non-melanoma skin cancer, and 37% have concurrent skin cancers including BCC, invasive SCC, or both (6).

The treatment protocols for carcinoma *in situ* vary. Most commonly used are surgical excision, cryotherapy, photodynamic therapy (PDT), 5-fluorouracil, and imiquimod (7). Surgical excision offers the advantages of margin control and confirmation of diagnosis. Only a few studies have evaluated the efficacy of surgery for carcinoma *in situ*, and most of these do not mention the excision margins (2). In the USA a 4–6-mm margin is advised for low-risk SCC, but margins for carcinoma *in situ* are not specified (3). The best option in many cases is surgical excision, but less invasive treatment options are also needed, because the cutaneous lesions may be multiple or occur at sites that are less suitable for surgical removal. In elderly patients, in particular, co-morbidities may preclude an aggressive treatment modality. Few randomized clinical trials elucidate success rates of different treatments in carcinoma *in situ*, and most of the studies performed have concentrated on comparison of the efficacy of PDT, cryotherapy and 5-fluorouracil, and/or imiquimod (8–10). Moreover, the follow-up periods in the studies are mostly short, up to 24 months, but, for PDT, 50 months' follow-up data are also available (1, 11).

The present study evaluated the efficacy of different treatment modalities used in SCC *in situ*, including surgery. The follow-up period was 8 years. This is a clinical study based on routine practice used at our hospital and not on randomization of the patients between the different treatment modalities.

MATERIALS AND METHODS

In Finland carcinoma *in situ* is treated mainly by surgical excision, cryotherapy or methyl aminolevulinate (MAL)-PDT. 5-fluorouracil is not used routinely because the drug is only available on special permission. Imiquimod is not officially approved for treatment of carcinoma *in situ*, although it is used in certain cases. This is a retrospective study of patients with carcinoma *in situ* diagnosed and treated at the Department of Dermatology, Skin Cancer Unit, Helsinki University Central Hospital, Finland over a period of one year (January to December 2006). All lesions were histologically confirmed. Patients whose diagnosis according to biopsy was carcinoma *in situ*, but which, after total excision, was changed into invasive skin malignancy (1 carcinoma verrucosus, 9 SCC) were excluded. Three patients with 5 lesions refused treatment and were also excluded from the study. The research team gained approval for this retrospective study from the clinical research committee.

The patient's characteristics that were recorded for the study were age, gender of patient, immunosuppressive therapy, anatomical site of lesion, other skin cancers before and at the time of biopsy, choice of treatment, recurrence after treatment and duration of follow-up. When surgery was carried out, histological margins were evaluated. Data were collected by reviewing patient medical and histological records and pictures.

Our treatment protocols for carcinoma *in situ* and the follow-up are generally standardized. When surgery is used the recommended histological excision margins are minimum 2 mm. Cryotherapy is performed after curettage in 2 freeze-thaw cycles using liquid nitrogen with 5-mm margins and 1-min margin thawing time. In PDT we use MAL. Before cream application the lesion is carefully curettaged. After an incubation time of at least 3 h the lesion is exposed to red light (630 nm) for 8 min at a mean light dose of 75 J/cm². Two PDT treatments are given, 7–14 days apart. The response to treatment is controlled at least once, 6 months after treatment. Thereafter, follow-up is normally arranged by the general practitioner, who re-admits the patient to our clinic if recurrence or new lesions appear. Possible recurrence was also checked from the patients' histological records which are shared by other university hospital clinics and general healthcare centres.

RESULTS

A total of 263 SCC *in situ* lesions in 239 patients were observed. The mean patient age was 77 years (range 35–97 years), 43% (103) were male and 57% (136) female. Many of the patients were elderly and 124 patients died during this almost 8-year follow-up period. In all cases the cause of death was unrelated to the skin cancer. Eighteen percent (44/239) had immunosuppression, 7% (17) of whom were organ transplant recipients. The other reasons for immunosuppressive therapy were rheumatoid arthritis ($n=11$), systemic lupus ($n=1$), dermatomyositis ($n=1$), polymyositis

($n=2$), polymyalgia rheumatica ($n=2$), idiopathic pulmonary fibrosis ($n=1$), hepatic disease due to cholangitis ($n=1$), temporal arteritis ($n=1$), psoriasis or psoriatic arthritis ($n=5$), amyloidosis ($n=1$) and haemolytic anaemia ($n=1$). Four patients had a history of arsenic exposure and 1 had epidermodysplasia verruciformis.

Most patients had signs of skin damage due to abundant exposure to the sun, and 57% (136) patients had previously had one or several premalignant or malignant skin cancers; 44% (106) had a history of actinic keratosis, 28% (68) carcinoma *in situ*, 13% (30) SCC, 36% (85) BCC, and 4% (10) malignant melanoma. At the time of biopsy 61% (146) had other skin malignancies or premalignant lesions.

In the present material the head and neck were most often affected (70%). Males more often had lesions on the earlobes (14% vs. 1%) and on the scalp (15% vs. 1%), whereas females more often had lesions on the cheeks (33% vs. 15%). In both males and females the trunk (10%), upper (11%) and lower (10%) extremities were less frequently affected than the head and neck.

Surgery was the treatment of choice in the majority of lesions (48%) (Fig. 1). Other treatment modalities included cryotherapy (24%) and PDT (28%). Surgery was used on the trunk (65%) more often than on other body sites. If the lesion was located on the lower extremities PDT was most often used (54%). It is also likely that larger and more indurated lesions in this area were treated with PDT due to contraindications to surgery and cryotherapy. The mean duration of follow-up was 66 months (range 2–93 months). Recurrences appeared 6–92 months (mean 64 months) after treatment.

The overall recurrence rate was 6.5%. Of all recurrences 65% were carcinoma *in situ* and 35% SCCs (Table I). Patients with immunosuppressive treatment had only a slightly higher overall recurrence rate than immunocompetent patients (11% vs. 6.2%). Twenty-three patients had actinic keratosis in treated areas, which were not counted as a recurrence.

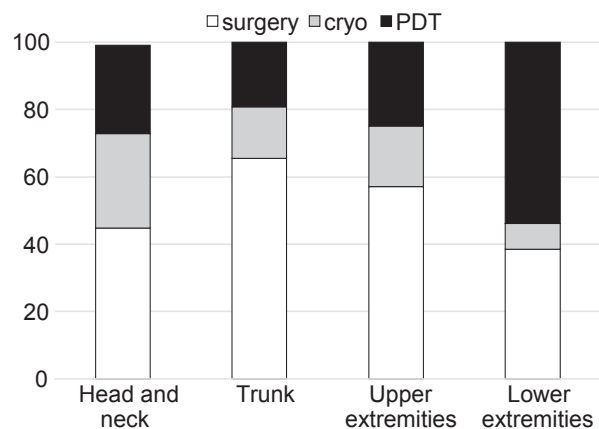


Fig. 1. Treatment modalities (%) in relation to tumour localisation.

Table I. Recurrences after different treatment modalities

Initial treatment	n/total (%)	Carcinoma <i>in situ</i>	Squamous cell carcinoma
Excision	1/125 (0.8)		1
Cryotherapy	3/64 (4.7)	1	2
Photodynamic therapy	13/74 (18)	10	3
Total, n/total (%)	17/263 (6.5)	11/263 (4.2)	6/263 (2.3)

When analysing recurrence rates after different treatment modalities, surgical excision had the lowest recurrence rate (0.8%). Excision margins varied between 0 and 5 mm. In 53 cases the margins were less than the recommended 2 mm, but there were no recurrences in these cases. Only 2 actinic keratoses occurred in operated areas, 15 and 51 months after operation. When recommended margins were used, there was one recurrence of SCC lesion.

Recurrence rates with the less invasive treatment modalities were higher; cryotherapy 4.7% ($n=3$) and PDT 18% ($n=13$). Following these less invasive methods 11 carcinomas *in situ* appeared (1 after cryotherapy and 10 after PDT) and 5 SCCs (2 after cryotherapy and 3 after PDT). All the recurrent carcinomas *in situ* and SCCs were histologically confirmed. There were also 21 actinic keratoses in the treated area (12 after cryotherapy and 9 after PDT). Of recurrent SCCs (6) 5 were excised and 1 patient died before treatment. Treatments for recurrent carcinoma *in situ* (11) were surgery in 5 cases, imiquimod in 3 cases, PDT in 2 cases, and cryotherapy in 1 case.

DISCUSSION

The lack of quality data about surgery and other treatments, together with many patient-dependent factors, affect therapeutic choice and make it difficult to perform a study on gold standard treatment. This is the first national retrospective study of SCC *in situ* in Finland, with 239 patients and 263 lesions.

In present study surgery had the lowest recurrence rate (0.8%). There is no clear consensus about the excision margin for carcinoma *in situ*. In our clinic the recommended histological excision margins are 2 mm, although in the study material margins were often less. The reason why re-excision was not always carried out was mostly patient-dependent, e.g. the patients had comorbidities and were hospitalized for other reasons or died before re-treatment. However, after surgery with less than the recommended margins there were no recurrences of carcinoma *in situ* or SCC, only 2 actinic keratoses were documented. On the other hand, in one case in which excisional margins were much wider than recommended (4.5 mm) a SCC appeared. We still suggest 2-mm histological excision margins and, in cases in which the margins are too narrow and re-excision is not an option, other treatment modalities around the scar or careful follow-up should be carried out.

Recurrence rates with cryotherapy and PDT were higher (4.7% and 18%, respectively) than after surgery (0.8%). It is possible that there was still underlying carcinoma *in situ* or SCC on the treated area, which appeared after superficial treatment and impaired the treatment outcome. A biopsy specimen represents only a small area of the lesion and does not always exclude invasive carcinoma. Ten patients with a diagnosis of carcinoma *in situ* according to biopsy, which was changed to invasive skin malignancy after total excision, were not included in the surgical group.

A randomized placebo-controlled study comparing the efficacy of PDT, cryotherapy and 5-fluorouracil for treatment of carcinoma *in situ* found recurrence rates of 15%, 21% and 17%, respectively, 12 months after the final treatment, while spontaneous healing had occurred in 50% of the placebo group (8). In this study the diagnosis of recurrence was clinical and actinic keratoses were also regarded as recurrences. In our study the recurrence rate with actinic keratosis following cryotherapy was similar, but much higher following PDT (30% vs. 15%). This may be due to our longer follow-up time and the selection of larger lesions in the PDT group because our study was not randomized. Our study is not comparable to randomized PDT studies because it is a retrospective study and treatment regimens will modify treatment results.

We could confirm previous observations that carcinoma *in situ* lesions are typically located on sun-exposed areas. In our material 57% of patients had previously had a premalignant or malignant skin cancer, which is higher than the published proportion of 30–50% (10). At the time of biopsy 61% of patients had other malignant or premalignant lesions. We did not report actinic keratosis as recurrence of carcinoma *in situ*. Most of our patients had sun-damaged skin with numerous premalignant lesions and field cancerization, and it was highly probable that new actinic keratoses would appear during the 8-year follow-up. Carcinoma *in situ* and SCC are more likely to be true recurrences after treatment of carcinoma *in situ*.

Retrospective studies have limitations because the choice of treatment is influenced by several factors. At present, no treatment modality is clearly superior, and the choice of treatment depends on location, size, thickness, and number of lesions; thick and small lesions are more often treated by surgery or cryotherapy and large thinner ones, especially on the face or lower limbs, by PDT. In addition, the patient's characteristics, clinician's expertise, availability of therapy, and the institutional experience are important in selection of the therapeutic approach (11). All thick and chronically ulcerative carcinomas *in situ* should be operated, because of the possibility of underlying SCC. Although surgery is the first-line treatment for carcinoma *in situ*, less invasive treatment modalities are needed for

multiple, very large carcinomas *in situ* or those located at sites that heal poorly after operation. In some cases combination treatment could be helpful, especially for large carcinomas *in situ*, e.g. operating first on deeper lesions and then treating the residual area with PDT. In addition, in some cases the cosmetic result after PDT is better than after surgery (8, 12). In elderly patients co-morbidities may preclude an aggressive treatment modality. Thus the advantages and disadvantages of each treatment method should be considered on an individual case basis.

The authors declare no conflicts of interest.

REFERENCES

1. Morton C, Birnie A, Eedy D. British Association of Dermatologist's guidelines for the management of squamous cell carcinoma in situ (Bowen's disease) 2014. *Br J Dermatol* 2014; 170: 245–260.
2. Shimizu I, Gruz A, Chang K, Dufresne R. Treatment of squamous cell carcinoma in situ: a review. *Dermatol Surg* 2011; 37: 1394–1411.
3. Westers-Attema A, van den Heijkant F, Lohman B, Nelemans P, Winnepeninckx V, Kelleners-Smeets N, et al. Bowen's disease: a six-year retrospective study of treatment with emphasis on resection margins. *Acta Derm Venereol* 2014; 94: 431–453.
4. Pitkänen S, Jeskanen L, Ylitalo L. [Basal cell carcinoma, squamous cell carcinoma and premalignant skin lesions-how to treat?] *Duodecim* 2014; 130: 643–653. (in Finnish).
5. de Berker D, McGregor J, Hughes B. Guidelines for the management of actinic keratoses. *Br J Dermatol* 2007; 156: 222–230.
6. Reizner G, Chuang T, Elpern D, Stone J, Farmer E. Bowen's disease (squamous cell carcinoma in situ) in Kauai, Hawaii. A population-based incidence report. *J Am Acad Dermatol* 1994; 31: 596–600.
7. Cox N, Eedy D, Morton C. Guidelines for management of Bowen's disease: 2006 update. *Br J Dermatol* 2007; 156: 11–21.
8. Morton C, Horn M, Leman J, Tack B, Bedane C, Tjioe M, et al. Comparison of topical methyl aminolevulinate photodynamic therapy with cryotherapy or fluorouracil for treatment of squamous cell carcinoma in situ: results of a multicenter randomized trial. *Arch Dermatol* 2006; 142: 729–735.
9. Lehmann P. Methyl aminolaevulinate-photodynamic therapy: a review of clinical trials in the treatment of actinic keratoses and nonmelanoma skin cancer. *Br J Dermatol* 2007; 156: 793–801.
10. Salim A, Lehman J, McColl J, Chapman R, Morton C. Randomized comparison of photodynamic therapy with topical 5-fluorouracil in Bowen's disease. *Br J Dermatol* 2003; 148: 539–543.
11. Cavicchini S, Serini SM, Fiorani R, Girgenti V, Ghislanzoni M, Sala F. Long-term follow-up of methyl aminolevulinate (MAL)-PDT in difficult-to-treat cutaneous Bowen's disease. *Int J Dermatol* 2011; 50: 1002–1005.
12. Bath-Hextall F, Matin R, Wilkinson D, Leonardi-Bee J. Interventions for cutaneous Bowen's disease. *Cochrane Database Syst Rev* 2013; 6: CD007281.