

SHORT COMMUNICATION

Disseminated *Mycobacterium chelonae* Infection Identified by Repeated Skin Sampling and Molecular Methods in a Patient with Rheumatoid ArthritisReiko Tsutsumi¹, Nanako Yamada¹, Yuichi Yoshida¹, Kazue Nakanaga², Norihisa Ishii² and Osamu Yamamoto¹¹Division of Dermatology, Department of Medicine of Sensory and Motor Organs, Faculty of Medicine, Tottori University, 36 Nishi-cho, Yonago 683-8504, and ²Leprosy Research Center, National Institute of Infectious Diseases, Tokyo, Japan. E-mail: r-ttm@med.tottori-u.ac.jp

Accepted Jun 25, 2015; Epub ahead of print Jun 30, 2015

Mycobacterium chelonae is a rapidly growing mycobacteria that commonly affects the skin. In an immunocompromised host, the infection can disseminate haematogenously with a fatal outcome. For accurate diagnosis and management, it is necessary to collect specimens and to culture pathogens appropriately. Molecular methods allow for more decisive diagnosis. We report here a rare case of haematogenously-disseminated *M. chelonae* infection with atypical cutaneous lesions, bloody blisters, and pulmonary lesions in a patient with rheumatoid arthritis.

CASE REPORT

A 75-year-old woman presented with a 2-month history of multiple nodules, pustules and ulcers on her extremities. She had been taking prednisolone, 7.5 mg daily, for 7 years because of rheumatoid arthritis. Two months previously, multiple abnormal shadows with cavitation were observed in her bilateral lungs on computed tomography (CT), and she was admitted to the clinic of internal medicine. The CT findings raised suspicion of fungal or mycobacterial infection, lung cancer, rheumatoid nodules or interstitial pneumonia associated with rheumatoid arthritis. Blood tests revealed a slightly elevated white blood cell count (10,200/mm³; normal 3,300–8,800/mm³) and elevated C-reactive protein (9.33 mg/dl; normal 0–0.2 mg/dl). *Candida*, *Aspergillus* and cryptococcal antigen, β -glucan and QuantiFERON[®]-TB Gold assay were all negative. Sialylated carbohydrate antigen KL-6 and serum tumour markers, such as carcinoembryonic antigen and cytokeratin subunit 19 fragment, were also negative. Bronchoscopy was performed 3 times and thoracentesis 5 times. However, no pathogens were cultured from the sputum, bronchial

washings, bronchoscopic biopsy specimens or thoracentesis fluid. In addition, there were no abnormal histopathological findings indicating malignancy or granuloma. Thoracoscopy lung biopsy was considered to be extremely risky for the patient. Although she was treated with vancomycin and linezolid, the pulmonary lesions became worse.

Physical examination revealed bloody blisters, up to 3.0 cm in diameter, with pustules and ulceration, on the left lower leg and foot (Fig. 1a). Varicella was suspected and aciclovir was administered intravenously for 10 days. However, the response was poor. Furthermore, the skin lesions extended to her upper legs, hip and upper extremities. A skin biopsy specimen from the lesion on the right leg showed non-specific mixed cellular infiltration. Neither bacilli nor fungi were found by periodic acid-Schiff, Grocott's or Ziehl-Neelsen's staining on histological sections or in culture from the skin lesions. Two months later, she presented with newly developed nodules on her left lower leg. A second skin biopsy from the lesion revealed abscess and granuloma composed of histiocytes, multinucleated giant cells, neutrophils and lymphocytes (Fig. 1b). Although Ziehl-Neelsen's staining was negative, we suspected mycobacterial infection from histopathological findings. Mycobacterium infection was demonstrated by polymerase chain reaction (PCR) using universal primers of mycobacterium, *hsp65* and *rpoB* genes, and the 16S-23S spacer region (Fig. S1¹) (1). Visible colonies were identified after one week of incubation and were subsequently confirmed as being *M. chelonae* by sequencing of the 16S *rRNA*, *hsp65*, and *rpoB* genes and the 16S-23S spacer region (not shown). Thus, a diagnosis of cutaneous *M. chelonae* infection was finally made. A combination of rifampicin (450 mg/day), clarithromycin (800 mg/day) and levofloxacin

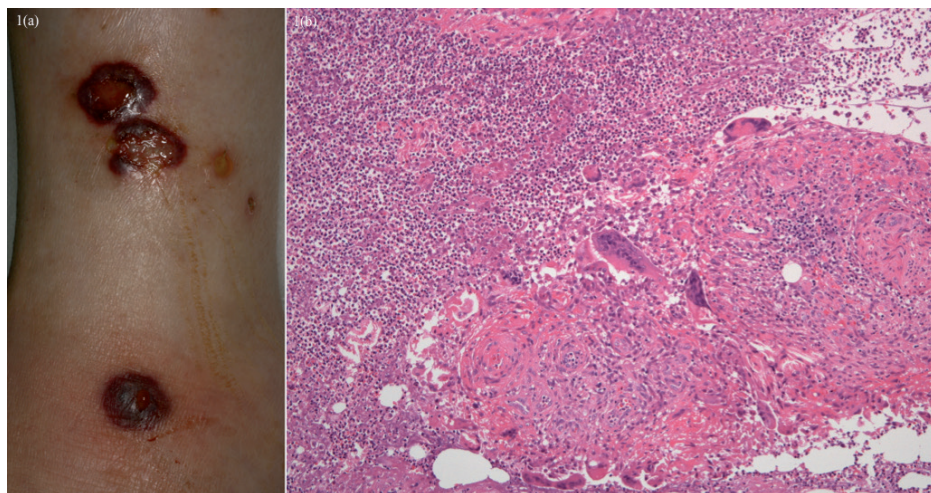
¹<http://www.medicaljournals.se/acta/content/?doi=10.2340/00015555-2188>

Fig. 1. Clinical features on admission. (a) Bloody blisters, 0.5–3.0 cm in diameter, with pustules and ulceration, on the left lower leg and foot. (b) A second skin biopsy from the left lower leg revealed abscess and granuloma composed of histiocytes, multinucleated giant cells, neutrophils and lymphocytes (haematoxylin-eosin stain) (original magnification $\times 100$).

(500 mg/day) was administered orally. A drug susceptibility test later showed sensitivity to only clarithromycin (minimum inhibitory concentration (MIC) of 8 µg/ml), amikacin (MIC of 16 µg/ml) and levofloxacin (MIC of 32 µg/ml). The skin lesions disappeared after 1 month. The pulmonary nodules also improved dramatically after treatment (Fig. S2a, b¹). However, regrettably, the patient died from sudden respiratory arrest after 6 months.

DISCUSSION

M. chelonae is one of the rapidly growing mycobacteria that commonly affect the skin (2). Localized cutaneous infections usually occur after traumatic injury or a surgical procedure (2). In an immunocompromised host, infection with *M. chelonae* can be disseminated haematogenously and follows a fatal course (3, 4). The clinical features of haematogenous dissemination to the skin consist of multiple recurring lesions in the extremities (5). Cutaneous *M. chelonae* infection presents with a variety of skin eruptions, including nodules, papules, pustules, ulcers and abscesses (6). However, bloody blisters have never been reported. Furthermore, pulmonary infection with *M. chelonae* is rare and shows diverse lesions on CT, such as bronchiectasis, nodules and cavities, in middle-aged and older women (7, 8). In our case, there was no definite evidence indicating infection with *M. chelonae* from respiratory specimens. However, not only the cutaneous lesions, but also the pulmonary lesions, were probably associated with *M. chelonae* infection in consideration of the drastic improvement in both lesions with multi-drug therapy. In addition, the lack of history of trauma and the widespread distribution of cutaneous lesions suggested that pulmonary lesions were primary and cutaneous lesions were the result of haematogenous dissemination.

Identification of *Mycobacteria* to the species level is necessary for adequate therapy because therapeutic responses are species-specific (6). Conventional identification techniques based on culture and biochemical characteristics of acid-fast isolates are the most commonly used. *M. chelonae* grows at 28–30°C in Löwenstein–Jensen medium with sodium citrate (9). However, the procedures need appropriate conditions and consume much time (6). The development of molecular methods, such as PCR, PCR restriction enzyme analysis and gene sequencing, has speeded up sensitive identification of mycobacteria (9).

Treatment of *M. chelonae* infection is often difficult because of its drug resistance (2). Standard anti-tuberculous drugs have little effect against rapidly growing mycobacteria (2, 6). Previous *in vitro* MIC studies on *M. chelonae* isolates have suggested susceptibility to clarithromycin, tobramycin, linezolid, imipenem, amikacin, clofazimine and doxycycline (7). However,

in vitro susceptibility does not consistently predict the effectiveness of treatment (6). Multi-drug therapy is recommended for *M. chelonae* (10). It has been suggested that clarithromycin combined with linezolid, tobramycin, imipenem, or tigecycline for 2–8 weeks might be effective in serious disseminated *M. chelonae* infection (6).

In conclusion, dermatologists should consider *M. chelonae* infection in cases of intractable skin lesions, and should collect specimens and culture pathogens appropriately and, if necessary, repeatedly. Furthermore, molecular methods allow for more decisive diagnosis; these procedures are less invasive than visceral biopsy in immunocompromised hosts and are essential for accurate diagnosis and management of disseminated *M. chelonae* infection.

REFERENCES

1. Nakanaga K, Hoshino Y, Yotsu RR, Makino M, Ishii N. Laboratory procedures for the detection and identification of cutaneous non-tuberculous mycobacterial infections. *J Dermatol* 2013; 40: 151–159.
2. Kane CL, Vincent AL, Greene JN, Sandin RL. Disseminated cutaneous *Mycobacterium chelonae* infection. *Cancer Control* 2000; 7: 181–184.
3. Wallace RJ Jr, Brown BA, Onyi GO. Skin, soft tissue, and bone infections due to *Mycobacterium chelonae*: importance of prior corticosteroid therapy, frequency of disseminated infections, and resistance to oral antimicrobials other than clarithromycin. *J Infect Dis* 1992; 166: 405–412.
4. Ingram CW, Tanner DC, Durack DT, Kernodle GW Jr, Corey GR. Disseminated infection with rapidly growing mycobacteria. *Clin Infect Dis* 1993; 16: 463–471.
5. Cooper JF, Lichtenstein MJ, Graham BS, Schaffner W. *Mycobacterium chelonae*: a cause of nodular skin lesions with a proclivity for renal transplant recipients. *Am J Med* 1989; 86: 173–177.
6. Kothavade RJ, Dhurat RS, Mishra SN, Kothavade UR. Clinical and laboratory aspects of the diagnosis and management of cutaneous and subcutaneous infections caused by rapidly growing mycobacteria. *Eur J Clin Microbiol Infect Dis* 2013; 32: 161–188.
7. Griffith DE, Aksamit T, Brown-Elliott BA, Catanzaro A, Daley C, Gordin F, et al. An official ATS/IDSA statement: diagnosis, treatment, and prevention of nontuberculous mycobacterial diseases. *Am J Respir Crit Care Med* 2007; 175: 367–416.
8. Hazelton TR, Newell JD Jr, Cook JL, Huitt GA, Lynch DA. CT findings in 14 patients with *Mycobacterium chelonae* pulmonary infection. *AJR Am J Roentgenol* 2000; 175: 413–416.
9. Calado Nogueira de Moura V, Gibbs S, Jackson M. Gene replacement in *Mycobacterium chelonae*: application to the construction of porin knock-out mutants. *PLoS One* 2014; 9: e94951.
10. Wallace RJ Jr, Dukart G, Brown-Elliott BA, Griffith DE, Scerpella EG, Marshall B. Clinical experience in 52 patients with tigecycline-containing regimens for salvage treatment of *Mycobacterium abscessus* and *Mycobacterium chelonae* infections. *J Antimicrob Chemother* 2014; 69: 1945–1953.