

## SHORT COMMUNICATION

## Borderline Lepromatous Leprosy: Cutaneous Manifestation and Type 1 Reversal Reaction

Mai Hattori<sup>1#</sup>, Sei-ichiro Motegi<sup>1#\*</sup>, Hiroo Amano<sup>1</sup>, Norihisa Ishii<sup>2</sup> and Osamu Ishikawa<sup>1</sup><sup>1</sup>Department of Dermatology, Gunma University Graduate School of Medicine, 3-39-22 Showa, Maebashi, Gunma 371-8511, and <sup>2</sup>Leprosy Research Center, National Institute of Infectious Diseases, Tokyo, Japan. E-mail: smotegi@gunma-u.ac.jp

Accepted Sep 30, 2015; Epub ahead of print Oct 6, 2015

<sup>#</sup>These authors contributed equally to this work.

Leprosy is a chronic granulomatous infection of the skin and peripheral nerves by an acid-fast bacillus, *Mycobacterium leprae*. Leprosy reactions involve spontaneous fluctuations in the clinical features, and T-cell reactivity to mycobacterial antigens. Type 1 reversal reactions (T1R) occur in cases of borderline leprosy, and 30% of patients with borderline leprosy are at risk of experiencing T1R (1). T1R can occur at any time, but frequently appears after starting multiple drug therapy (MDT).

We report here a case of borderline lepromatous leprosy with T1R. It was difficult to confirm the diagnosis in this case because T1R without neurological symptoms overlapped with the cutaneous manifestation of borderline leprosy before MDT.

## CASE REPORT

A 35-year-old Japanese-Brazilian woman was referred to our hospital in June 2014 with a 15-month history of facial ery-

thema, arthralgia and intermittent mild fever. She was born in Sao Paulo and had never visited any other cities in Brazil. She moved to Japan at the age of 22 years, and had never visited any other countries. Her medical history included bronchial asthma from the age of 2 years. She noticed a butterfly rash-like erythema of the face in March 2013, which spread to the chest and forearms. She was examined at a dermatological clinic, where she was diagnosed with atopic dermatitis and administered oral prednisolone, 20 mg/day, from September 2013. The skin lesions and fever improved temporarily with almost complete resolution, but recurred after the prednisolone dose was decreased. At another dermatological clinic, she was suspected of having systemic lupus erythematosus (SLE). Physical examination revealed a high fever and pale-reddish oedematous erythema with telangiectasia around the eyebrows, cheeks, ear lobes, chest and forearms (Fig. 1A, B). No madarosis of the eyebrows/eyelashes was observed. Abnormal laboratory results included only C-reactive protein level (1.13 mg/dl; normal <0.1 mg/dl). Tests for the antinuclear antibody and rheumatoid factor were negative. Thickened peripheral nerves were not detected (2). In addition, peripheral neurological symptoms, including motor, sensory and autonomic nerve disturbance were not

detected based on a neurological assessment that included light touch, pin-prick test, thermal sensory test, manual muscle strength test and monofilament test (3). Because of the localized eruptions to the sun-exposed area, we first suspected a photosensitivity reaction. However, the minimal erythema dose was normal. Histological examination of the facial erythema revealed oedema of the upper dermis and perivascular infiltration of lymphocytes, histiocytes, neutrophils and a small number of multinuclear giant cells. Although granulomas and foamy macrophages were absent, we strongly suspected leprosy because of the presence of histiocytes and multinucleated giant cells (Fig. 1C, D). No specific microorganisms were identified by Ziehl-Nielsen and Fite-Faraco staining. Immunohistochemical staining with anti-phenolic glycolipid I antibody was also negative. However, acid-fast bacilli were detected by the slit-skin smear test of the left cheek and ear lobe (bacterial index, cheek: 1+, ear: 1+). In addition, the *M. leprae*-specific

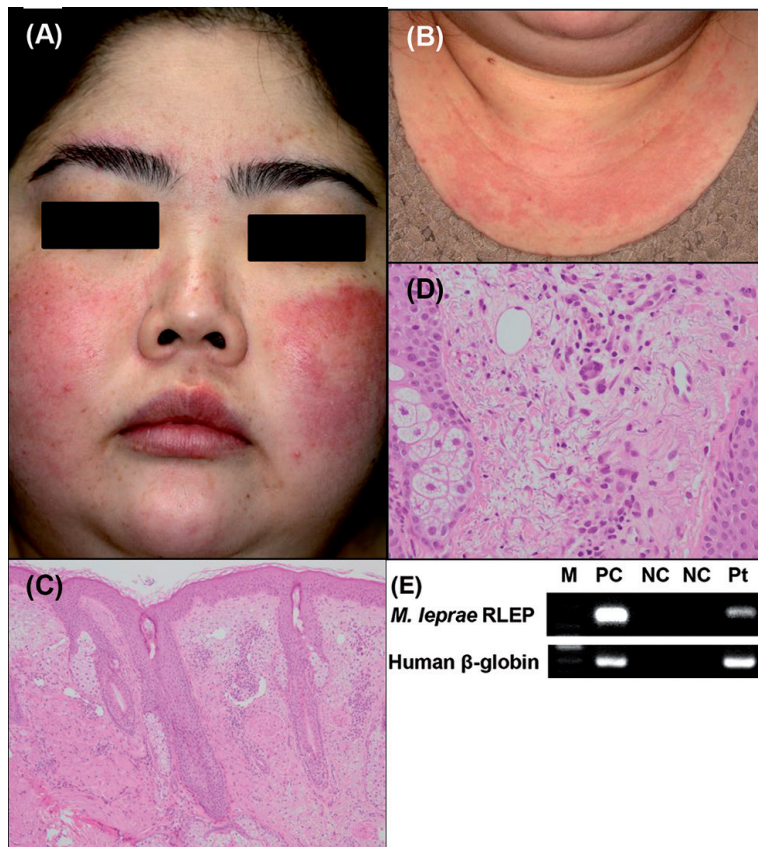


Fig. 1. (A, B) Pale-reddish oedematous erythema with telangiectasia around the eyebrows, cheeks and chest. (C, D) Histological examination of facial erythema. Oedema of the upper dermis and perivascular infiltration of lymphocytes, histiocytes, neutrophils and a small number of multinuclear giant cells. (Haematoxylin and eosin (H&E): original magnification C:  $\times 100$ , D:  $\times 400$ ). (E) *M. leprae*-specific repetitive element (RLEP) was detected from the skin sample by nested PCR. M: marker, PC: positive control, NC: negative control, Pt: patient's skin sample. A written permission is given by the patient to publish this photo.

repetitive element (RLEP) was detected from a skin sample by nested PCR (Fig. 1E) (4). Based on these findings, a diagnosis of multibacillary, borderline lepromatous (BL) leprosy with T1R was established. In addition to prednisolone (10 mg/day), multidrug therapy (MDT), rifampicin (600 mg/month), clofazimine (300 mg/month and 50 mg/day) and dapsone (100 mg/day) was administered from August 2014, and resulted in an improvement in the skin lesions after 6 months. Dapsone resistance is associated with missense mutations in the *folP1* gene encoding dihydropteroate synthase (5). Rifampicin resistance is associated with mutations in a small region of *rpoB* encoding the RNA polymerase  $\beta$  subunit (6). We did not detect these mutations based on the PCR assay results. When prednisolone was tapered to 7.5 mg/day, T1R with fever and facial erythema recurred, but were controlled by increasing the prednisolone dose to 15 mg/day.

## DISCUSSION

Leprosy is a chronic granulomatous infection caused by *M. leprae*. Based on the immunological response of the host to *M. leprae*, leprosy is classified into 5 major types: TT (tuberculoid), BT (borderline tuberculoid), BB (borderline), BL (borderline lepromatous) and LL (lepromatous) according to the Ridley-Jopling scale (7). Patients with the TT type have a vigorous cellular immune response to the mycobacterium, resulting in a low bacillary load and only a few skin lesions, such as hypopigmented macules. Those with the TT type also experience reduced sensation resulting from considerable peripheral nerve damage. Alternatively, patients with the LL type have a high bacillary load and many diffuse skin lesions without loss of sensation. Patients with borderline states, including BT, BB and BL, have symptoms of both the TT and LL forms. The borderline types are immunologically unstable and can be complicated by reversal reactions. The formation of small granulomas is characteristic of borderline leprosy, and the granulomas become more diffuse from BT to BL. In our case, a small number of multinuclear giant cells were observed histologically. *M. leprae* was detected from the skin by the slit-skin smear test and PCR. In addition, our patient showed multiple erythematous lesions with no sensation loss or sensory, motor and autonomic dysfunctions of the peripheral nerves. These findings support the classification of our case as BL leprosy. The differential diagnosis were mainly SLE, dermatomyositis, erysipelas, sarcoidosis, granuloma annulare and cutaneous tuberculosis. We excluded these diseases based on the clinical and histological features and genetic analysis.

Borderline leprosy cases produce skin lesions that are intermediate between the 2 polar forms, such as macular, papulonodular, plaque and annular appearances (1). Telangiectasia is an uncommon feature of leprosy. The early form of the rare diffuse lepromatous leprosy (Latapi's lepromatosis) has been reported to cause telangiectasia (8). Madarosis of the eyebrows/

eyelashes is a late sign of Latapi's lepromatosis, and was not observed in our patient.

Leprosy reactions, including T1R and type 2 reaction (erythema nodosum leprosum), are induced by the host immune responses to *M. leprae*, and may occur before, during or after MDT. T1R is accompanied by the exacerbation of pre-existing skin lesions or the development of new skin lesions, with oedematous erythema. Neurological dysfunction is found in 50% of patients with T1R (9). In our patient, the oedematous erythema of the face was resolved after prednisolone treatment, but recurred after the prednisolone dose was reduced. Histologically, we observed the oedema of the upper dermis and the perivascular infiltration of the lymphocytes. Based on these findings, we diagnosed the patient with leprosy with T1R. However, it took 2 months to establish the correct diagnosis because of the T1R without neurological symptoms. Furthermore, the skin lesions might have been modified by the administration of prednisolone before MDT. In Japan, leprosy is very rare and occurs only in immigrants from endemic countries. Our case is an unusual presentation of BL leprosy and the imported nature of the case. Awareness of unusual clinical features of leprosy and leprosy reactions is important and may enable clinicians to make an early diagnosis and initiate appropriate treatment, especially in non-endemic countries.

*The authors declare no conflicts of interest.*

## REFERENCES

1. Britton WJ, Lockwood DN. Leprosy. *Lancet* 2004; 363: 1209–1219.
2. Khadiolkar SV, Yadav RS, Soni G. A practical approach to enlargement of nerves, plexuses and roots. *Pract Neurol* 2015; 15: 105–115.
3. Brandsma JW, Wagenaar I, Post E, Nicholls P, Richardus JH. Reliability of clinical nerve function assessment in peripheral neuropathies. *Lepr Rev* 2014; 85: 29–35.
4. Donoghue HD, Holton J, Spigelman M. PCR primers that can detect low levels of *Mycobacterium leprae* DNA. *J Med Microbiol* 2001; 50: 177–182.
5. Kai M, Matsuoka M, Nakata N, Maeda S, Gidoh M, Maeda Y, et al. Diaminodiphenylsulfone resistance of *Mycobacterium leprae* due to mutations in the dihydropteroate synthase gene. *FEMS Microbiol Lett* 1999; 177: 231–235.
6. Honore N, Cole ST. Molecular basis of rifampin resistance in *Mycobacterium leprae*. *Antimicrob Agents Chemother* 1993; 37: 414–418.
7. Ridley DS, Jopling WH. Classification of leprosy according to immunity. A five-group system. *Int J Lepr Other Mycobact Dis* 1966; 34: 255–273.
8. Rea TH, Jerskey RS. Clinical and histologic variations among thirty patients with Lucio's phenomenon and pure and primitive diffuse lepromatosis (Latapi's lepromatosis). *Int J Lepr Other Mycobact Dis* 2005; 73: 169–188.
9. Van Brakel WH, Khawas IB, Lucas SB. Reactions in leprosy: an epidemiological study of 386 patients in west Nepal. *Lepr Rev* 1994; 65: 190–203.