

CLINICAL REPORT

Verapamil is Less Effective than Triamcinolone for Prevention of Keloid Scar Recurrence After Excision in a Randomized Controlled Trial

Patricia L. DANIELSEN^{1,3}, Suzanne M. REA^{1,2,6}, Fiona M. WOOD^{1,2,6}, Mark W. FEAR^{1,6}, Helena M. VIOLA⁴, Livia C. HOOL^{4,5}, Thilanee U. GANKANDE¹, Mansour ALGHAMDI¹, Andrew W. STEVENSON^{1,6}, Mitali MANZUR^{1,6} and Hilary J. WALLACE^{1,6}
¹Burn Injury Research Unit, School of Surgery and ⁴School of Anatomy, Physiology and Human Biology, The University of Western Australia, ³Burns Service of Western Australia, Fiona Stanley Hospital, Western Australia, Australia, ²Department of Dermatology, Bispebjerg University Hospital, Copenhagen, Denmark, ⁵Victor Chang Cardiac Research Institute, New South Wales, and ⁶Fiona Wood Foundation, Western Australia, Australia

A double-blind randomized controlled trial with a paired split-scar design compared verapamil, an L-type Ca²⁺ channel antagonist, and triamcinolone for prevention of keloid recurrence after excision. Ca²⁺ channel blocking activity of verapamil in keloid cells was explored. One keloid was excised per subject and each wound half randomized to receive intralesional injections of triamcinolone (10 mg/ml) or verapamil (2.5 mg/ml) at monthly intervals (4 doses). Interim analysis was performed after 14 subjects were completed. Survival analysis demonstrated significantly higher keloid recurrence with verapamil compared to triamcinolone 12 months post-surgery (log-rank test, $p=0.01$) and higher overall risk of recurrence with verapamil (hazard ratio 8.44, 95% CI 1.62–44.05). The study was terminated early according to the stopping guideline ($p<0.05$). Verapamil is safe but not as effective as triamcinolone in preventing keloid recurrence after excision. Further study is necessary to determine if clinical response to verapamil is linked to modulation of intracellular Ca²⁺. Key words: keloid; verapamil; triamcinolone; calcium channels; randomized controlled trial.

Accepted Feb 24, 2016; Epub ahead of print Feb 26, 2016

Acta Derm Venereol 2016; 96: 774–778.

Hilary J. Wallace, Burn Injury Research Unit, School of Surgery, University of Western Australia, M318, 35 Stirling Highway, Crawley, Western Australia 6009, Australia. E-mail: hilary.wallace@uwa.edu.au

Keloid scarring is a severe wound healing disorder characterized by benign fibroproliferative lesions extending beyond the original wound boundaries (1). Patients experience pruritus, pain, paraesthesia, functional impairment and serious cosmetic concerns (2, 3). Unlike hypertrophic scars, keloid scars do not regress and commonly recur after surgical excision (4). Diagnosis is based on clinical features, and histopathology is characterized by haphazardly arranged hyalinized collagen bundles and a tongue-like advancing edge in the papillary dermis (5). The mechanism of keloid disease remains unclear but it is most often initiated by skin trauma (6), with the most common areas involved being the chest, shoulder, upper back, neck and earlobes.

In vitro, keloid fibroblasts show increased collagen synthesis, altered extracellular matrix remodelling and resistance to apoptosis compared to normal skin or hypertrophic scar fibroblasts (7). Enhanced responses to growth factors and altered cytokine expression have also been demonstrated and several studies report altered keratinocyte-fibroblast interactions (8, 9).

Treatment of keloid scarring is extremely challenging and there is no single effective treatment regimen. There is a lack of high quality evidence from randomized controlled trials. Surgical removal alone has an unacceptable recurrence rate of 45–100% (4). International guidelines recommend intralesional therapy with corticosteroids or surgical excision combined with corticosteroid injections (4). Triamcinolone acetonide is the most commonly used corticosteroid (10 to 40 mg/ml) and is injected intralesionally after surgical excision at intervals of 4 to 6 weeks for several months (10–14). Five-year recurrence rates for surgical excision plus triamcinolone acetonide are reported to be between 8% and 50% (4). However, treatment with corticosteroids can be associated with local and systemic adverse effects including delayed wound healing, hypopigmentation, dermal atrophy, telangiectasia, widening of the scar (15–17) and Cushing's syndrome (18).

Verapamil is an L-type Ca²⁺ channel blocker widely used in the treatment of cardiac arrhythmias, hypertension and angina. *In vitro* studies of verapamil have demonstrated anti-fibrotic activity suggesting its potential for treatment or prevention of keloid scarring. Alterations in fibroblasts that have been proposed include reorganization of actin filaments (19), inhibition of collagen synthesis (20), increased secretion of matrix metalloproteinase-1 (collagenase) (21), decreased production of interleukin-6 and vascular endothelial growth factor, reduced cell proliferation and increased apoptosis (22). Importantly, verapamil has a superior safety profile compared to corticosteroids that permits longer and more intense treatment.

Positive *in vivo* effects of verapamil have been reported in clinical trials and it is now included as an alternate treatment in European guidelines for intralesional treatment of keloids (23). Two randomized studies compared intralesional verapamil with triamcinolone (24, 25). Verapamil reduced height, vascularity, and pliability of keloid scars in these studies, but was slower than triamcinolone. The

use of verapamil as an adjunct to surgical excision has been investigated in 2 single-arm studies (26, 27) and one randomized study that compared verapamil combined with topical silicone to topical silicone alone (28). These studies reported a wide range of keloid recurrence rates with verapamil (1.4–48%) and found it to be a safe treatment. No studies to date have directly compared verapamil to triamcinolone for prevention of keloid recurrence after surgical excision.

This randomized controlled trial was undertaken to test the equivalence and safety of verapamil and triamcinolone as treatments for the prevention of keloid recurrence after surgical excision. The putative mechanism of anti-fibrotic activity of verapamil via the antagonism of L-type Ca^{2+} channels in keloid fibroblasts and keratinocytes was also explored by measuring Ca^{2+} influx in real time through changes in ratio of the fluorescence intensity (340/380 nm) of the Ca^{2+} -sensitive fluorescent dye, Fura-2.

METHODS

Subjects and study design

Thirty adult patients with a keloid scar for excision were scheduled for recruitment (one keloid scar per patient). The study was a randomized controlled trial with a paired split-scar design (ClinicalTrials.gov NCT01720056). One half of the suture line was randomly allocated to receive triamcinolone; the other half to receive verapamil. Subjects were withdrawn if they experienced side-effects or when the primary outcome was reached (keloid recurrence). A conservative stopping guideline of $p < 0.05$ (log-rank test) for benefit on the primary outcome was used.

Study protocol

Treatments were injected intradermally into the wound edges immediately post-operatively and 1, 2 and 3 months after keloid excision: triamcinolone acetonide (Kenacort A10[®] Injection, Aspen, Australia) 2 mg/cm, maximum total dose 10 mg (reduced to 1 mg/cm, maximum total dose 5 mg, after safety review); verapamil hydrochloride (Isoptin[®] Injection, Abbott, Australasia) 0.5 mg/cm, maximum total dose 2.5 mg.

Assessments and outcome measurements

Fitzpatrick skin type (29) and clinical details were recorded. Scars were assessed at 1, 2, 3, 6 and 12 months post-surgery by clinical examination and the modified Vancouver Scar Scale (mVSS) (30). Side-effects (local and systemic) were monitored. Subjects rated each scar half using the patient scale of the Patient and Observer Scar Assessment Scale v2.0 (POSAS) (31). Pigmentation and vascularity were quantified with the DermaLab Combo[®] (Cortex Technologies, Denmark): Melanin Index % (MI%) and Erythema Index % (EI%), respectively (32). The primary outcome was time to keloid recurrence (>2 mm height, lateral growth into uninvolved skin and symptoms of pain or pruritis). Secondary outcomes were local side-effects, mVSS score, POSAS patient scale, vascularity (EI%) and pigmentation (MI%).

Functional assessment of L-type Ca^{2+} channels – Intracellular Ca^{2+} assays

Primary cultures of fibroblasts ($n = 7$) and keratinocytes ($n = 6$) were established from the excised keloid tissues (33).

Intracellular Ca^{2+} was monitored using Fura-2 AM (34), with ratiometric 340/380 nm fluorescence recorded before and after exposure to the L-type Ca^{2+} channel agonist, 2 μM BayK(-) (Bay K8644, Sigma), or the antagonist, 1 μM verapamil hydrochloride (Isoptin[®] Injection, Abbott, Australasia). Pre-treatment 340/380 nm fluorescence was assigned a value of 1.0.

Data analysis

Keloid recurrence-free survival in the treatment groups was compared using Kaplan-Meier survival curve analysis (log-rank [Mantel-Cox] test and hazard ratio [HR]). Secondary outcomes by treatment in subjects with and without keloid recurrences were analysed by the Wilcoxon sign rank test and side-effects were compared qualitatively. The 340/380 nm fluorescence after exposure to BayK and verapamil hydrochloride was analyzed within patients using the Mann Whitney test; responses between treatment groups were compared qualitatively. Graph-Pad Prism Ver. 5.0 was used for statistical analysis and the level of statistical significance was $p < 0.05$. For full methodological details see Appendix S1¹.

RESULTS

Fourteen subjects (6 females and 8 males) were recruited and followed up for one year or until keloid recurrence from September 2012 to January 2014. The mean age of the subjects was 32.1 years (range 18–53 years) and the mean scar duration was 12 years (range 1–36 years). Subject and keloid characteristics are described in Table S1¹ and photographs illustrating the clinical variability of representative keloid scars are shown in Fig. S1¹.

An interim analysis was performed after the 14 subjects were followed up for 12 months. The flow of subjects and each treated scar half through the study is outlined in Fig. S2¹. One subject withdrew voluntarily and 4 subjects experienced side-effects (atrophy) in the steroid-treated half of the scar and were withdrawn from the study at that point. The steroid dose was subsequently halved to 1 mg/cm (maximum total dose 5 mg) for new and on-going subjects. No side-effects were observed in the steroid-treated half thereafter. No subjects experienced side-effects in the verapamil half of the scar.

Six subjects had a recurrence of the keloid in the verapamil-treated half of the scar (3 subjects at 2 months post-surgery; 2 subjects at 3 months post-surgery; 1 subject at 6 months post-surgery) and no keloid recurrences were observed in the steroid-treated halves. Three subjects continued in the study to the 12-month follow-up free of keloid recurrence in either half of the scar. Photographs illustrating representative keloids at the time of recurrence or the 12-month follow-up are shown in Fig. S4¹ (the same keloids as depicted in Fig. S1¹). Kaplan-Meier survival curve analysis demonstrated a significantly higher recurrence rate in the verapamil-treated half of the scar at 12 months post-surgery (log-rank [Mantel-Cox] test; $p = 0.01$) and a

¹<http://www.medicaljournals.se/acta/content/?doi=10.2340/00015555-2384>

higher overall risk of recurrence with verapamil (hazard ratio [HR] 8.44, 95% CI 1.62–44.05). The study was terminated early according to the predetermined stopping guideline ($p < 0.05$) and the remaining 16 patients were not recruited (Fig. 1).

The secondary scar outcomes by treatment in subjects with and without keloid recurrences are summarised in Fig. 2. At the time of keloid recurrence in the 6 subjects there was a significantly greater median total mVSS score and POSAS score (patient scale) in the half of the scar treated with verapamil ($p < 0.05$, Wilcoxon sign rank test). There was no significant difference in scar colour as measured by MI% and EI%. In the 3 subjects who did not experience keloid recurrence there was no significant difference between the treatments in terms of median mVSS score, POSAS score (patient scale) or colour (pigmentation or vascularity) at the 12-month follow-up.

Fibroblasts were cultured from 7 keloids: 5 that recurred, 2 that did not recur. Functional assessment of L-type Ca^{2+} channels in these cells showed that there was a significant influx of Ca^{2+} after 20 min exposure to the L-type Ca^{2+} channel agonist [BayK(-)] in 4/7 subjects (Fig. 3A). There was no relationship observed between the response to BayK(-) and keloid recurrence, with the 340/380 nm fluorescence levels in fibroblasts from keloids which did recur nested within 340/380 nm fluorescence levels in fibroblasts from keloids which did not recur. There was no reduction in baseline 340/380 nm fluorescence levels with exposure to verapamil in any of the cultured keloid fibroblasts (Fig. 3A).

Keratinocytes were also cultured from 6 of the 7 keloids above: 4 that recurred, 2 that did not recur. Functional assessment of L-type Ca^{2+} channels in keratinocytes showed that there was a significant influx of Ca^{2+} after 20 min exposure to the L-type Ca^{2+} channel agonist [BayK(-)] in the same 4 subjects which showed an influx of Ca^{2+} in fibroblasts (Fig. 3B). Again, there was no clear relationship observed between the response to BayK(-) and keloid recurrence, with the 340/380 nm fluorescence levels in keratinocytes from keloids which recurred overlapping with the 340/380 nm fluorescence levels in keratinocytes from keloids which did not recur.

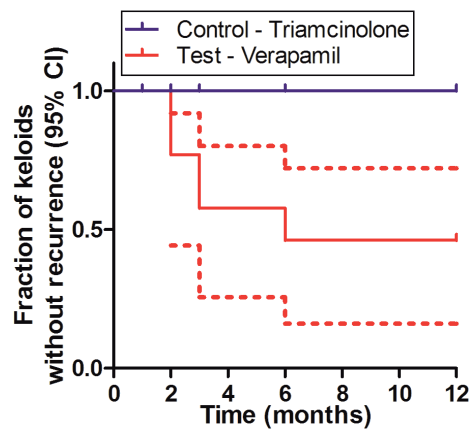


Fig. 1. Comparison of keloid recurrence-free survival between scar halves treated with triamcinolone and verapamil: Kaplan Meier survival curve analysis (solid line = median; hatched line = 95% CI).

There was no significant reduction in baseline 340/380 nm fluorescence levels with exposure to verapamil in any of the cultured keloid keratinocytes (Fig. 3B).

DISCUSSION

This double-blind randomized controlled study had a paired split-scar design enabling a precise comparison between two different treatments within the same patient. Verapamil, an L-type Ca^{2+} channel antagonist, was not as effective as triamcinolone for the prevention of keloid recurrence after surgical excision at the dose tested (0.5 mg/cm linear scar, at monthly intervals for 4 doses). The exploratory *in vitro* experiments did not demonstrate L-type Ca^{2+} channel blocking activity in keloid fibroblasts or keratinocytes by 1 mM verapamil.

Human skin fibroblasts have previously been shown to express the cardiac L-type Ca^{2+} channel subtype (36). However, early studies on the characterization of ion channels in human dermal fibroblasts have suggested that the expression of Ca^{2+} channels is not constitutive in human fibroblasts (37). In our study, matched fibroblasts and keratinocytes cultured from a subset of keloids demonstrated significant L-type Ca^{2+} channel activity *in vitro* in response to the agonist BayK(-).

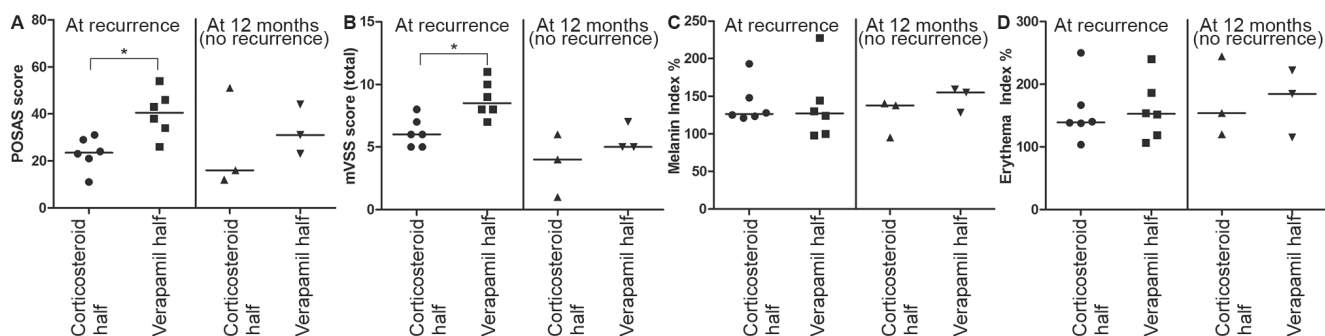


Fig. 2. Secondary scar outcomes by treatment in subjects with ($n = 6$) and without ($n = 3$) keloid recurrences. (A) POSAS (patient scale); (B) mVSS score (total); (C) Melanin Index %; (D) Erythema Index. [Horizontal line = median; * = $p < 0.05$ (Wilcoxon sign rank test)].

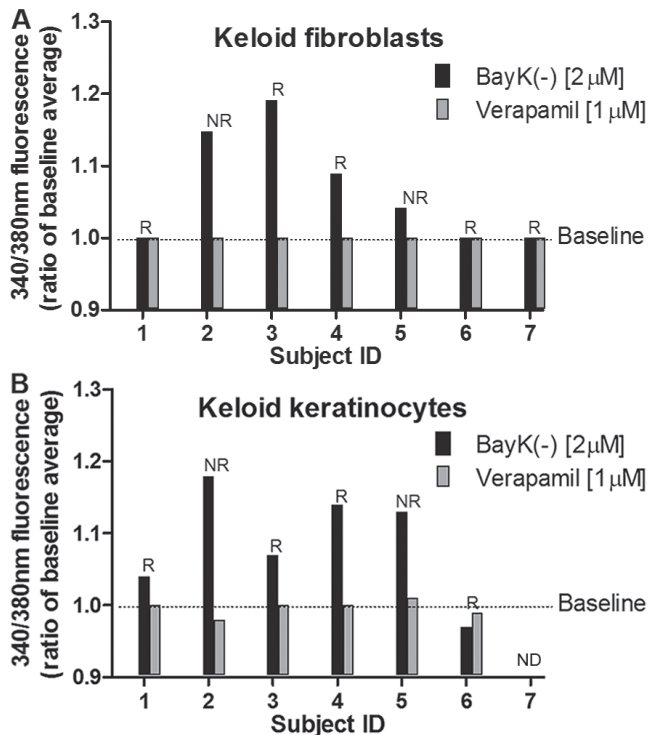


Fig. 3. Results of functional L-type Ca^{2+} channel studies. (A) 340/380 nm fluorescence in individual subject keloid fibroblast cultures treated with L-type Ca^{2+} channel agonist, BayK(-) 2 μM (20 min exposure), or the antagonist, verapamil 1 μM . Baseline 340/380 nm fluorescence is assigned a value of 1.0. (B) 340/380 nm fluorescence in individual subject keloid keratinocyte cultures treated with L-type Ca^{2+} channel agonist, BayK(-) 2 μM (20 min exposure), or the antagonist, verapamil 1 μM . Baseline 340/380 nm fluorescence is assigned a value of 1.0. [R=subject with keloid recurrence; NR=subject with no keloid recurrence; ND=no data].

However, the response to BayK(-) did not fit the pattern of the clinical response to verapamil and 1 mM verapamil did not reduce basal intracellular Ca^{2+} levels in any of the keloid fibroblasts or keratinocytes.

Previously reported *in vitro* studies of the anti-fibrotic activity of verapamil do not provide direct evidence that the effects are specifically due to antagonism of L-type Ca^{2+} channels. For example, Boggio et al. (21) measured Ca^{2+} levels and phenotypic changes in human skin fibroblasts after *in vitro* treatment with verapamil for 2 days, but these experiments did not measure Ca^{2+} influx in real time or provide evidence to support whether the observed changes were mediated through L-type Ca^{2+} channels.

No previous studies have directly compared verapamil and corticosteroid for prevention of keloid recurrence after surgical excision. It is challenging to make a direct comparison of the results of this study with previous studies due to differences in the dose of verapamil, frequency of application, surgical technique, follow-up interval and outcome measures (definition of recurrence). Copcu et al. (27) (single-arm study of verapamil) used W-plasties or split-thickness skin grafts in all subjects undergoing keloid excision and the classification of scar outcome at 2 years was subjective. A final outcome

of poor/very poor was reported in only 3/21 subjects (1.4%); an outcome of moderate/poor/very poor was reported in 10/21 subjects (48%). A single-arm study using verapamil as an adjunct to ear lobe keloid excision (26) found a 48% keloid recurrence rate with verapamil. D'Andrea et al. (28) in a randomised control trial (using topical silicone in the control group) reported a 46% keloid recurrence rate with excision and verapamil. Taken together, these studies and the study described in this paper do not support verapamil as an effective adjunct to surgical excision of keloids.

Previous studies on intralesional treatment of keloid scars without excision (24, 25) concluded that verapamil was effective, but slower than triamcinolone, with injections every 3 weeks. While this supports our finding that verapamil is not equivalent to triamcinolone, the reporting of a final positive outcome with flattening of all keloid scars with verapamil treatment contrasts with the more negative interpretation of the results of the present study. Prevention of recurrence of keloid scarring after surgical excision may require more aggressive therapy than intralesional treatment of an existing keloid scar.

Differences between the patient samples in the studies (ethnicity, Fitzpatrick skin type, familial disposition to keloid scars, size, location and duration of keloid), study design, protocol and study end points may also have contributed to the different results between studies and differences in interpretation of the results.

A key strength of this study is the paired split-scar design, with each patient their own control. This strategy overcomes the problems of large variation in keloid characteristics between subjects, which limits the interpretation of the results of previous clinical studies. The study design also included precise control of the verapamil dose per linear cm of scar. The scar assessor and subject were blinded to the treatments, which supports the ability to achieve unbiased assessment. Scar height, a key element of the primary end point, was measured with the help of calibrated silicone strips making this assessment more objective. None of the previous studies (*in vitro* or *in vivo*) have directly measured L-type Ca^{2+} channel activity and intracellular Ca^{2+} flux in keloid fibroblasts. The inclusion of Ca^{2+} studies, such as those conducted here, is an important step in building an evidence base for the proposed biological effects of verapamil in the treatment of keloids.

The study had limitations which impact on the conclusions that can be drawn. While the clinical study had a double-blind design (subjects and assessors blinded to treatments) the surgeon administering the study injections was not blinded due to the different physical properties of the two injected solutions. For ethical reasons (to minimise poor outcomes for subjects participating in this study), the definition of recurrence (study end point) used here was conservative. Similarly, the study stopping guideline was conservative ($p < 0.05$) and the final sample size was small. The long-term outcome of the

response to this dose of verapamil after keloid excision cannot be deduced from this study. The study sample was heterogeneous with respect to the anatomical location of the keloid, and the subjects' sex, age and ethnicity, which may have contributed to the variability in results. Three subjects did not experience keloid recurrence in either of the intervention arms. Due to ethical considerations it was not possible to add a non-intervention placebo arm in the study design (due to the high risk of recurrence), and it is possible that these keloid scars may not have recurred even without treatment.

The *in vitro* studies also had several limitations which influence the interpretation of the findings. The cells for the Ca²⁺ studies were only cultured from a subset of the keloids and therefore may not be representative of the whole group. Furthermore, excising the tissue and culturing the cells may have caused alterations in expression and/or localisation of the Ca²⁺ channels. While the use of Fura-2 is widely considered the standard for quantitative intracellular Ca²⁺ measurements (38), we did not calibrate the Ca²⁺ levels in our experiments, nor did we directly demonstrate the presence of L-type Ca²⁺ channels in the cells through the use of immunohistochemistry. In measuring the L-type antagonist activity of verapamil in keloid-derived cells a single concentration of verapamil was tested (1 µM) and dose response was not explored.

In conclusion, intralesional verapamil is safe but not as effective as triamcinolone in the prevention of early keloid recurrence after surgical removal. The data do not support the use of verapamil as a steroid sparing adjunct therapy for surgical management of keloid scars. It is possible that increasing the dose or frequency of injection could improve the effectiveness of verapamil as an adjunct to surgical excision, but this needs further study. Patient compliance with more frequent injections would pose a problem. From the exploratory *in vitro* experiments conducted it was not possible to conclude whether a clinical response to verapamil treatment was linked to modulation of intracellular Ca²⁺. These *in vitro* studies are a starting point and further work is required to confirm the presence and subtype of Ca²⁺ channels in keloid fibroblasts and keratinocytes, the role of these channels in keloid disease pathogenesis and the mechanism of action of verapamil in relation to its reported efficacy as an intralesional keloid treatment.

ACKNOWLEDGMENTS

This work was supported in part by the Fiona Wood Foundation. PLD was funded by Knud Højgaards Fond, Sophus Jacobsens Fond and the Fiona Wood Foundation. UTG, MA and AWS receive scholarship funding from the Wound Management Innovation Cooperative Research Centre, the Australian Government (UTG), The University of Western Australia (AWS) and the King Khalid University, Saudi Arabia (MA). HMV is a Heart Foundation Postdoctoral Fellow and LCH is ARC Future Fellow and Honorary NHMRC Senior Research Fellow. We thank Helen DeJong for scar assessment support and Sian Falder for the calibrated silicone strips for measuring scar height.

The authors declare no conflicts of interest.

REFERENCES

1. Peacock EE Jr, Madden JW, Trier WC. Biologic basis for the treatment of keloids and hypertrophic scars. *South Med J* 1970; 63: 755–760.
2. Bock O, Schmid-Ott G, Malwski P, Mrowietz U. Quality of life of patients with keloid and hypertrophic scarring. *Arch Dermatol Res* 2006; 297: 433–438.
3. Nicholas RS, Falvey H, Lemonas P, Damodaran G, Ghanem AM, Selim F et al. Patient-related keloid scar assessment and outcome measures. *Plast Reconstr Surg* 2012; 129: 648–656.
4. Mustoe TA, Cooter RD, Gold MH, Hobbs FD, Ramelet AA, Shakespeare PG et al. International Advisory Panel on Scar Management. International clinical recommendations on scar management. *Plast Reconstr Surg* 2002; 110: 560–571.
5. Jumper N, Paus R, Bayat A. Functional histopathology of keloid disease. *Histol Histopathol* 2015; 30: 1033–1057.
6. Wolfram D, Tzankov A, Püzl P, Piza-Katzer H. Hypertrophic scars and keloids – A review of their pathophysiology, risk factors, and therapeutic management. *Dermatol Surg* 2009; 35: 171–181.
7. Gauglitz GG, Korting HC, Pavicic T, Ruzicka T, Jeschke MG. Hypertrophic scarring and keloids: Pathomechanisms and current and emerging treatment strategies. *Mol Med* 2011; 17: 113–125.
8. Funayama E, Chodon T, Oyama A, Sugihara T. Keratinocytes promote proliferation and inhibit apoptosis of the underlying fibroblasts: an important role in the pathogenesis of keloid. *J Invest Dermatol* 2003; 121: 1326–1331.
9. Marneros AG, Krieg T. Keloids – clinical diagnosis, pathogenesis, and treatment options. *J Dtsch Dermatol Ges* 2004; 2: 905–913.
10. Chowdri NA, Masarat M, Mattoo A, Darzi MA. Keloids and hypertrophic scars: results with intraoperative and serial postoperative corticosteroid injection therapy. *Aust N Z J Surg* 1999; 69: 655–659.
11. Niessen F, Spauwen P, Schalkwijk J, Kon M. On the nature of hypertrophic scars and keloids: a review. *Plast Reconstr Surg* 1999; 104: 1435–1458.
12. Chen MA, Davidson TM. Scar management: prevention and treatment strategies. *Curr Opin Otolaryngol Head Neck Surg* 2005; 13: 242–247.
13. Jalali M, Bayat A. Current use of steroids in management of abnormal raised skin scars. *Surgeon* 2007; 5: 175–180.
14. Xiqiao W, Yingkai L, Chun Q, Shuliang L. A Review of the Effectiveness of Antimitotic Drug Injections for Hypertrophic Scars and Keloids. *Ann of Plast Surg* 2009; 63: 688–692.
15. Manuskiatti W, Fitzpatrick RE. Treatment response of keloidal and hypertrophic sternotomy scars: comparison among intralesional corticosteroid, 5-fluorouracil, and 585-nm flashlamp-pumped pulsed-dye laser treatments. *Arch Dermatol* 2002; 138: 1149–1155.
16. Alster T. Laser scar revision: comparison study of 585-nm pulsed dye laser with and without intralesional corticosteroids. *Dermatol Surg* 2003; 29: 25–29.
17. Asilian A, Darougheh A, Shariati F. New combination of triamcinolone, 5-fluorouracil, and pulsed-dye laser for treatment of keloid and hypertrophic scars. *Dermatol Surg* 2006; 32: 907–915.
18. Finken MJ. Cushing's syndrome and adrenal insufficiency after intradermal triamcinolone acetonide for keloid scars. *Eur J Pediatr* 2010; 169: 1147–1149.
19. Doong H, Dissanayake S, Gowrishankar TR, LaBarbera

- MC, Lee RC. The 1996 Lindberg Award. Calcium antagonists alter cell shape and induce procollagenase synthesis in keloid and normal human dermal fibroblasts. *J Burn Care Rehabil* 1996; 17: 497–514.
20. Lee RC, Ping JA. Calcium antagonists retard extracellular matrix production in connective tissue equivalent. *J Surg Res* 1990; 49: 463–466.
 21. Boggio RF, Freitas VM, Cassiola FM, Urabayashi M, Machado-Santelli GM. Effect of a calcium-channel blocker (verapamil) on the morphology, cytoskeleton and collagenase activity of human skin fibroblasts. *Burns* 2011; 37: 616–625.
 22. Giugliano G, Pasquali D, Notaro A, Brongo S, Nicoletti G, D'Andrea F. Verapamil inhibits interleukin-6 and vascular endothelial growth factor production in primary cultures of keloid fibroblasts. *Br J Plast Surg* 2003; 56: 804–809.
 23. Middelkoop E, Monstrey S, Téot L, Vranckx J. Scar management – practical guidelines. Maca-Cloetens: Elsene; 2012: pp 109.
 24. Margaret Shanthi FX, Ernest K, Dhanraj P. Comparison of intralesional verapamil with intralesional triamcinolone in the treatment of hypertrophic scars and keloids. *Indian J Dermatol Venereol Leprol* 2008; 74: 343–348.
 25. Ahuja RB, Chatterjee P. Comparative efficacy of intralesional verapamil hydrochloride and triamcinolone acetonid in hypertrophic scars and keloids. *Burns* 2014; 40: 583–588.
 26. Lawrence WT. Treatment of earlobe keloids with surgery plus adjuvant intralesional verapamil and pressure earrings. *Ann Plast Surg* 1996; 37: 167–169.
 27. Copcu E, Sivrioglu N, Oztan Y. Combination of surgery and intralesional verapamil injection in the treatment of the keloid. *J Burn Care Rehabil* 2004; 25: 1–7.
 28. D'Andrea, Brongo S, Farraro G, Baroni A. Prevention and treatment of keloids with intralesional verapamil. *Dermatology* 2002; 204: 60–62.
 29. Fitzpatrick TB. The validity and practicality of sun-reactive skin types I through VI. *Arch Dermatol* 1988; 124: 869–871.
 30. Baryza MJ, Baryza GA. The Vancouver Scar Scale: An administration tool and its interrater reliability. *J Burn Care Rehabil* 1995; 16: 535–538.
 31. van de Kar AL, Corion LU, Smeulders MJ, Draaijers LJ, van der Horst CM, van Zuijlen PP. Reliable and feasible evaluation of linear scars by the Patient and Observer Scar Assessment Scale. *Plast Reconstr Surg* 2005; 116: 514–522.
 32. Gankande TU, Duke JM, Danielsen PL, DeJong HM, Wood FM, Wallace HJ. Reliability of scar assessments performed with an integrated skin testing device – the DermaLab Combo®. *Burns* 2014; 40: 1521–1529.
 33. Aasen T, Belmonte J. Isolation and cultivation of human keratinocytes from skin or plucked hair for the generation of induced pluripotent stem cells. *Nat Protoc* 2010; 5: 371–382.
 34. Viola HM, Arthur PG, Hool LC. Transient exposure to hydrogen peroxide causes an increase in mitochondria-derived superoxide as a result of sustained alteration in L-type Ca²⁺ channel function in the absence of apoptosis in ventricular myocytes. *Circ Res* 2007; 100: 1036–1044.
 35. Roques C, Téot L. The use of corticosteroids to treat keloids: a review. *Int J Low Extrem Wounds* 2008; 7: 137–145.
 36. Soldatov NM. Molecular diversity of L-type Ca²⁺ channel transcripts in human fibroblasts. *Proc Natl Acad Sci U S A* 1992; 89: 4628–4632.
 37. Estacion M. Characterization of ion channels seen in subconfluent human dermal fibroblasts. *J Physiol* 1991; 436: 579–601.
 38. Paredes RM, Etzler JC, Watts LT, Zheng W, Lechleiter JD. Chemical calcium indicators. *Methods* 2008; 46: 143–151.