

## CLINICAL REPORT

# Onychomatricoma with Misleading Features

J. FAYOL<sup>1</sup>, R. BARAN<sup>2</sup>, C. PERRIN<sup>3</sup> and F. LABROUSSE<sup>4</sup>

<sup>1</sup>Department of Dermatology, Centre Hospitalier Universitaire Dupuytren, Limoges, <sup>2</sup>Nail Disease Centre, Cannes, <sup>3</sup>Department of Histopathology, Hôpital Pasteur, Nice and <sup>4</sup>Department of Histology, Centre Hospitalier Universitaire Dupuytren, Limoges, France

**Onychomatricoma is a rare tumour of the nail matrix with peculiar clinical and histological features and electron microscopic findings. We report on 5 cases with appearances which were misleading. Three presented as longitudinal melanonychia, a previously unreported observation. One case had the appearance of a cutaneous horn. In 3 of the 5 cases the tumour was associated with an onychomycosis and this may thus have been a predisposing factor in the secondary fungal infestation. Onychomatricoma appears as a multi-faceted tumour which can be mimicked by longitudinal melanonychia and/or onychomycosis. Key words: onychomatricoma; nail tumours; onychomycosis; longitudinal melanonychia.**

(Accepted May 19 2000.)

Acta Derm Venereol 2000; 80: 370–372.

R. Baran, Nail Disease Centre, 42, rue des Serbes, FR-06400, Cannes, France.

E-mail: baranrmd@cote-dazur.com

Onychomatricoma is a rare nail matrix tumour. Since it was first described in 1992 (1), about 20 cases have been reported (2–8) and its clinical (1, 7) histological (3) and electron microscopic aspects (4) are now well documented. In typical cases, it is characterized by a thickening of the nail plate with pronounced ridging, yellow discoloration along the length of the nail plate, a funnel-shaped deformity and multiple splinter haemorrhages in the yellowish nail. When the nail is avulsed, the thickened portion is made up of small cavities penetrated by filamentous digitations projecting from the matrix. The purpose of this paper is to report on patients with clinical presentations of onychomatricoma which could be misleading and to discuss the role of associated fungal infections.

## MATERIAL AND METHODS

### Case 1

A 64-year-old man presented with a *Trichophyton mentagrophytes* var. *interdigitale* onychomycosis which responded to oral terbinafine, except for the left second toe. On this toe, one medial fourth of the nail plate showed a dark-brown discoloration, suggesting a longitudinal melanonychia (Fig. 1). This pigmented part of the nail was thickened, but was neither hard nor crumbly. A preliminary histological examination of nail clippings taken from the distal pigmented plate did not show any fungal element (periodic acid–Schiff and Grocott stains). A second examination was done on a more extensive clipping of the distal nail plate and showed disorganization of the nail keratin with numerous empty channels; a diagnosis of onychomatricoma was therefore suspected. The pigmented nail plate involved was avulsed, exposing filiform digitations emerging from the nail matrix. Histological examination of the excised tumour and nail plate confirmed the diagnosis of onychomatricoma.

### Case 2

A 50-year-old man was treated for a *Trichophyton rubrum* onychomycosis of the toenails with oral terbinafine and topical amorolfine. All the nails concerned were cured, except the fourth left toe. The lateral half of the nail plate was thickened, yellowish and separated from the healthy nail plate by 2 dark-brown longitudinal bands. The proximal nail fold was swollen and painless. The involved portion of the nail plate was avulsed: yellowish thickened nail and melanonychia keratin were both present in 1 piece. After avulsion, a diagnosis of onychomatricoma was strongly suggested because of multiple filiform projections emerging from the nail matrix. This diagnosis was confirmed by histological examination.

### Case 3

A 24-year-old woman was concerned by the appearance, 1 year prior to consultation, of a brown pigmentation of the medial third of the great toenail. At first glance we suspected a frictional longitudinal melanonychia. One year later the area of pigmentation had become enlarged and a distal fissure was visible at the border between the normal and affected nail (Fig. 2a). Dermoscopy examination revealed that the external border of the darkened area was yellowish and we suspected the existence of an underlying onychomatricoma. The abnormal portion of the nail was removed, showing a tumour emerging from the matrix (Fig. 2b) and the characteristic proximal holes of the nail plate observed in onychomatricoma. Histology confirmed the clinical diagnosis.

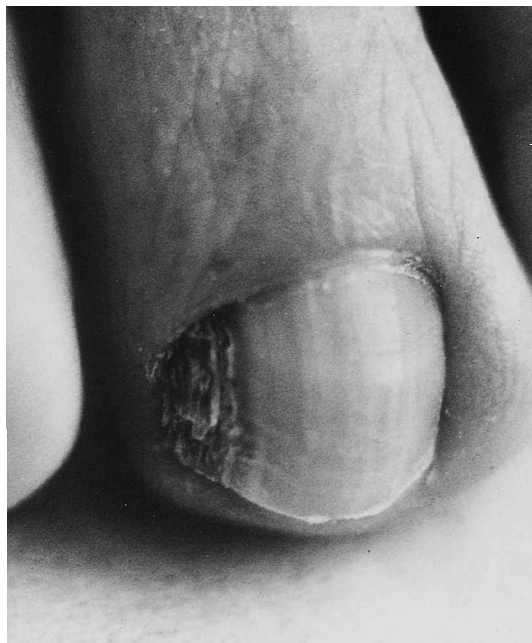

Fig. 1. Case 1: dark-brown discoloration. *Trichophyton mentagrophytes* associated with onychomatricoma.

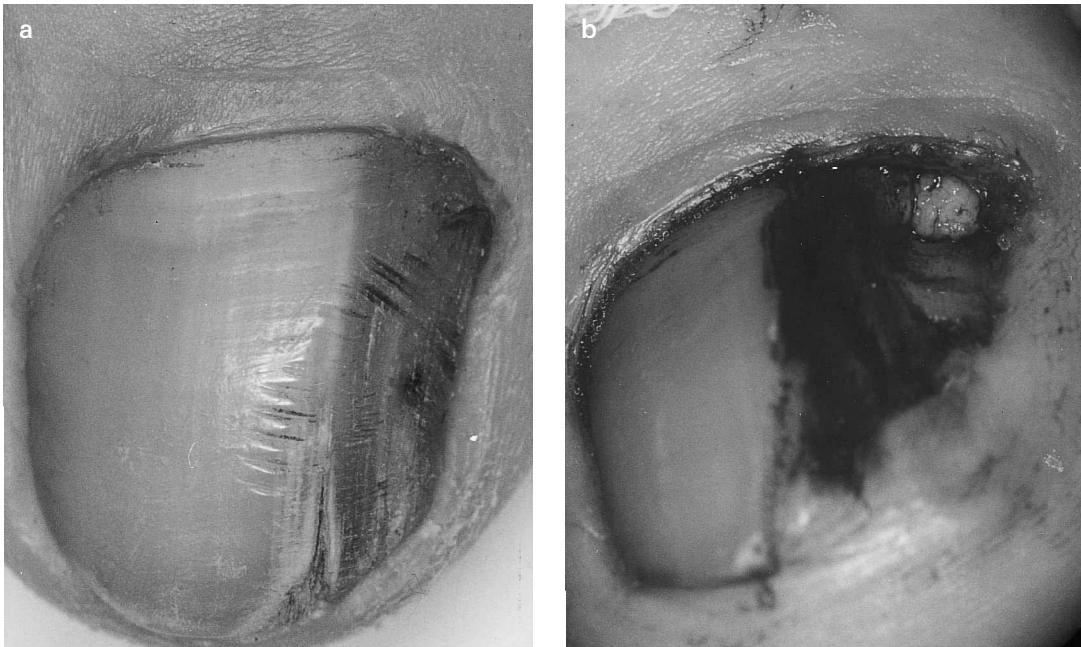


Fig. 2. Case 3: (a) longitudinal melanonychia with progressive enlargement of the dark band and distal split; (b) tumour emerging from the matrix during surgery.

#### Case 4

A 44-year-old woman presented with a longitudinal yellow patch on the right great toe, associated with a slight inflammation of the proximal nail folds. The lateral border of this abnormal area was linear and clear-cut while the inner limit was undulated (Fig. 3a). The free edge in front of the lesions was slightly thickened and a piece of nail keratin, as well as debris from the distal nail bed, were sent for direct microscopy and culture. Hyphae were demonstrated and Sabouraud's medium yielded *Fusarium oxysporum*. The patient was treated with 8% ciclopirox nail lacquer. One year later she returned, with the patch now showing a change in presentation. The lateral border was still linear, as before, but the inner border had become similarly linear (Fig. 3b). At this time this longitudinal xanthonychia was clinically diagnostic of onychomatricoma, which was confirmed both surgically and histologically (Fig. 3cd).

#### Case 5

A 67-year-old man had complained for 10 years of a lateral cutaneous horn on the fourth left finger. It looked like an onychoheterotopia and was considered to be post-traumatic. The lesion was resected. Histological examination showed large longitudinal channels. In these channels there was an epithelial structure, without interposition of a granular layer underlined by a fibrillar collagenous stroma. This histological appearance led to the diagnosis of onychomatricoma.

## DISCUSSION

Onychomatricoma has particular clinical features which should suggest the diagnosis. The clinical characteristics are a yellow longitudinal discolouration of the involved portion of the nail plate, which is thickened, a transverse over-curvature and proximal splinter haemorrhages (1, 7).

We have reported 3 cases with a longitudinal melanonychia pattern which has never been previously described. The clinical appearance clearly ruled out the possibility of a haematoma, which might have resulted either from splinter

haemorrhages associated with onychomatricoma or even from trauma produced by trimming of the nail (5). In Case 1, the peculiar consistency of the thickened part of the involved nail raised the suspicions which led to the diagnosis. The histopathological study of the nail clippings was quite helpful in this case. In Cases 2 and 3 the diagnosis of onychomatricoma was more readily suspected because the longitudinal melanonychia was associated with a rather characteristic yellow thickened nail. The pigmentation was probably caused by the activation of the matricial melanocytes.

An unusual clinical heterotopic nail appearance is noted in Case 5. This has been reported in 2 other cases, and was associated with a swollen proximal nail fold (3). In Case 5 this swollen, proximal nail fold pattern was not observed but it was, however, seen in Cases 2 and 4 which were not associated with a cutaneous horn. In Cases 1, 2 and 4 onychomatricoma was discovered only after the onychomycosis had failed to resolve fully, and histological examination was then undertaken.

Onychomycosis is very common and, of course, finding an onychomatricoma at the same time may be purely coincidental. However, the nail might have been rendered more susceptible to onychomycosis because of pathological nail keratin induced by the tumour. This may be especially relevant in Case 4 where only 1 nail was concerned. However, onychomatricoma is sometimes considered to be a "reactive" tumour, even though it has been suggested that it is most likely to be a hamartoma (1, 3). The associated fungi were of different varieties in our 3 cases, but this does not preclude the possibility that fungal infection could be a predisposing factor in the emergence of onychomatricoma. This hypothesis may be confirmed or refuted by future case reports.

Finally, onychomatricoma appears as a multi-faceted tumour which may be mimicked by longitudinal melanonychia and/or fungal infection.

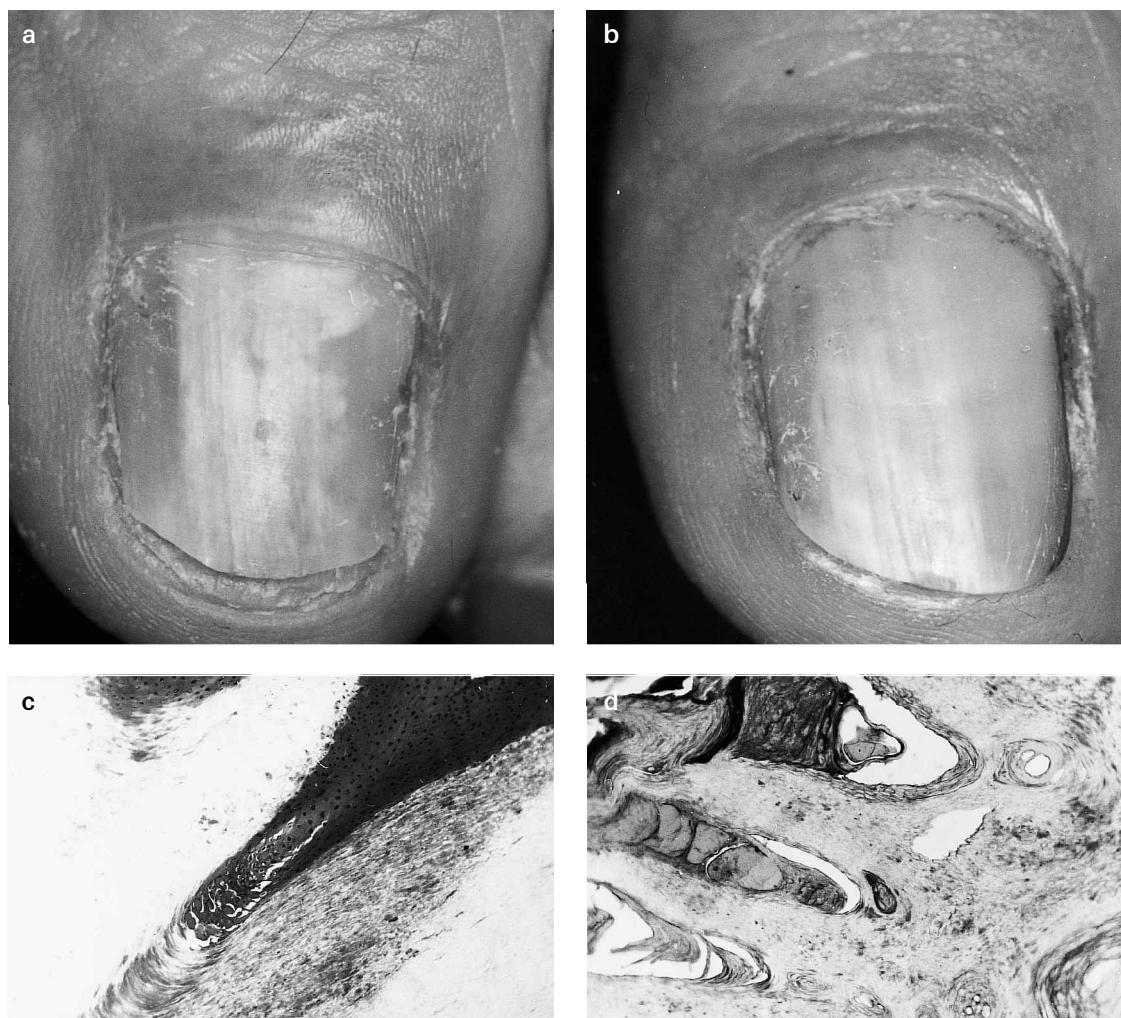


Fig. 3. Case 4: (a) yellow patch of the great toenail with linear lateral border and undulated medial limit. Culture grew *Fusarium oxysporum*; (b) lateral and medial borders of the yellow patch are both linear after antifungal therapy; (c) distal epithelial digitation lined with a keratogenous zone; (d) thickened nail plate with multiple channels filled by serous fluid.

#### REFERENCES

1. Baran R, Kint A. Onychomatrixoma: filamentous tufted tumour in the matrix of a funnel-shaped nail: a new entity (report of three cases). *Br J Dermatol* 1992; 126: 510–515.
2. Van Holder C, Dumontier C, Abimelec P. Onychomatrixoma. *J Hand Surg [Br]* 1999; 24: 120–121.
3. Perrin Ch, Goettmann S, Baran R. Onychomatrixoma: Clinical and histopathologic findings in 12 cases. *J Am Acad Dermatol* 1998; 39: 560–564.
4. Kint A, Baran R, Geerts ML. The onychomatrixoma: an electron microscopic study. *J Cutan Pathol* 1997; 24: 183–188.
5. Raison-Peyron N, Alirezai M, Meunier L, Barneon G, Meynadier J. Onychomatrixoma: an unusual cause of nail bleeding. *Clin Exp Dermatol* 1998; 23: 138.
6. Duhard E, Baptiste C, Monegier du Sorbier C. Onychomatrixome: deux nouveaux cas. *Nouv Dermatol* 1996; 15: 461.
7. Haneke E, Franken J. Onychomatrixoma. *Dermatol Surg* 1995; 21: 984–987.
8. Goettmann S, Drapé JL, Baran R, Perrin C, Haneke E, Belaich S. Onychomatrixome: deux nouveaux cas: intérêt de la résonance magnétique nucléaire. *Ann Derm Venereol* 1994; 121: S145.