

CLINICAL REPORT

Surgical Removal of Ulcer and Lipodermatosclerosis Followed by Split-Skin Grafting (Shave Therapy) Yields Good Long-term Results in “Non-healing” Venous Leg Ulcers

WILFRIED SCHMELLER¹ and YVONNE GABER²

¹Rosenparkklinik, Darmstadt, Germany and ²Department of Dermatology and Venereology, Medical University of Luebeck, Luebeck, Germany

The purpose of this study was to evaluate the long-term effects of shave therapy in non-healing venous leg ulcers. Forty-one patients with 75 recalcitrant leg ulcers caused by primary deep vein incompetence or post-thrombotic syndrome were operated by shave therapy (removal of ulcer and surrounding lipodermatosclerosis with a Schink skin-grafting knife and covering of the wounds with meshed split-thickness skin grafts). After an average follow-up period of 2 years and 5 months all patients were evaluated for long-term results. The healing rate of ulcers classified as non-healing was 67% (50 of 75 ulcers). The healing rate was 76% for ulcers associated with primary deep vein incompetence and 58% for ulcers associated with post-thrombotic syndrome ($p=0.08$). Even in cases with recurrence (33%) these ulcers were strikingly reduced by 80–90% of their original size. Hypaesthesia was noticed in 38% of the transplanted areas. In “non-healing” venous leg ulcers due to deep venous insufficiency shave therapy yields favourable long-term results. Because it is only a symptomatic treatment which does not reduce the pathological refluxes, continuous compression of the lower leg is important. **Key words:** shave therapy; non-healing venous ulcers.

(Accepted March 20, 2000.)

Acta Derm Venereol 2000; 80: 267–271.

Prof. Dr. med. Wilfried Schmeller, Germany.

E-mail: wilfried.schmeller@t-online.de

For leg ulcers associated with deep venous insufficiency, due to either primary deep vein incompetence or post-thrombotic syndrome, compression therapy is the treatment of choice. It is successful in about 80% of all venous ulcers; however, 20% of these ulcers cannot be cured (1) and of those cured recurrence rates of 30–50% within 1 year (2, 3) have been reported. In fact, it has been claimed that “at present, venous ulceration is not a curable disease” (4).

To promote healing in recalcitrant or non-healing ulcers several surgical procedures have been advocated. Conventional skin grafting yields success rates between 50% and 90%, but recurrence rates of about 50% within the following years have been described (5, 6). The effect of (endoscopic) perforator dissection on ulcer healing, having been a topic of controversy for some time (7, 8), is now encouraging (9, 10); however, it is not clear whether it is suitable for all ulcers or only for those of the inner ankle. Paratibial fasciotomy has produced favourable results (11) but can only be employed for ulcers located at the inner ankle. Replacement of insufficient deep vein segments by vein valve transplants or

venous transposition operations is difficult and can only be performed in a few specialist centres (12).

In 1987, good short-term results were reported after layered shaving of 32 consecutive patients with 58 refractory venous ulcers (13). However, no investigation of recurrence was undertaken. While we can confirm good short-term results with the same method, which we called shave therapy (14), the aim of this study was to determine the long-term effects of the procedure. This study extends our previously published data by increasing both the patient numbers and the duration of follow-up.

PATIENTS AND METHODS

Patients

In the Department of Dermatology and Venereology, Medical University of Luebeck, 129 patients with 163 non-healing leg ulcers were treated by shave therapy from January 1994 to December 1998. For the evaluation of long-term results the first 41 patients (17 men and 24 women) were re-examined with 75 ulcers on 55 limbs. Their mean age at the time of surgery was 70 (52–87) years (23 patients >70 years and 8 >80 years). The average duration of the present ulcers was 20 (0.5–65) years. Ten patients were operated on in 1994, 8 in 1995 and 23 in 1996. All ulcers were classified as “non-healing”; they did not heal in spite of conservative therapy (local wound care and treatment with compression bandaging or stockings) and/or (repeated) surgical therapy (dissection of perforator veins and/or stripping of additional insufficient superficial veins, conventional skin grafting, paratibial fasciotomy and crural fasciotomy). In several patients limb amputations because of recurrent cellulitis and extreme pain had already been considered.

In all patients ultrasound with 8 and 4 MHz probes and duplex sonography with 5 MHz pulsed Doppler probes (Sonoline SI-450, Siemens AG, Erlangen, Germany) revealed deep venous refluxes, sometimes combined with refluxes of the superficial and/or perforator veins. Refluxes were located in the femoral (16 legs), popliteal (37 legs) and crural veins (37 legs). In 30 of 55 legs post-thrombotic changes in deep veins (thickening, obstruction, organized thrombi, partial recanalization) could be observed. Thirty-four ulcers (45%) were caused by primary deep vein incompetence and 41 ulcers (55%) by post-thrombotic syndrome. In addition, insufficient superficial veins were found in 28 legs and insufficient perforator veins in 21 legs.

The classification of venous disease was according to CEAP (15): C_{6,S} (clinical signs: active ulceration with symptoms), E_S or E_P (aetiology: due to thrombosis or primary varicosis), A_D and A_S or A_D and A_P (anatomy: deep and superficial veins affected or deep and perforator veins affected, respectively). The segments affected were 2 and 3 in the long saphenous veins, 11–15 in the deep veins and 18 in the perforator veins, P_R (pathophysiology: reflux). The disability scores in our patients were 2 (can work 8 h daily only with support device) or 3 (unable to work even with support device).

“Mixed” ulcers were present in 10 legs; an ankle brachial pressure

index < 0.8 indicated arterial occlusive disease in combination with venous insufficiency. The lowest values of arterial pressure found in the foot arteries were 50 mmHg in normotensive patients.

Methods

The shave therapy operative procedure was performed under general or spinal anaesthesia using a Schink skin-grafting knife (Aesculap, Tuttlingen, Germany). The ulcers and indurated areas next to and underneath the ulcers and above the fascia were excised in flat horizontal layers (Figs 1a and b), until palpation indicated a less indurated tissue and inspection showed an improved bleeding pattern (Fig. 1c); the fascia itself was not removed. Circumscribed bleeding was terminated by electrocoagulation or ligation and diffuse bleeding by elevating the leg. Meshed split-skin grafts of 0.4–0.8 mm thickness from the thigh were placed on the wound area immediately after shave therapy (Fig. 1d). Most ulcers were located on the medial side

of the lower leg (Fig. 1a). In 16 patients with ulcers covering the whole calf area, shaving was performed over the complete circumference of the lower limb. In those who preoperatively showed an improvement in venous refilling time by photoplethysmography during occlusion tests, shave therapy was combined with saphenectomy (6 limbs) or with dissection and ligation of insufficient perforator veins (9 limbs).

In 6 patients, a second grafting was performed after incomplete healing. In most patients >75% of the grafted wound area was healed at 1 week postoperatively (Fig. 1e). The majority of these patients were discharged from hospital 2–3 weeks after surgery and treatment with hydrocolloid dressings and compression bandages was continued. Regular check-ups were performed, beginning 3 months after surgery (Fig. 1f). Most patients preferred to use compression bandaging of the lower leg after complete healing instead of hosiery.

Thirty-four patients were seen in March and April 1998. Seven had

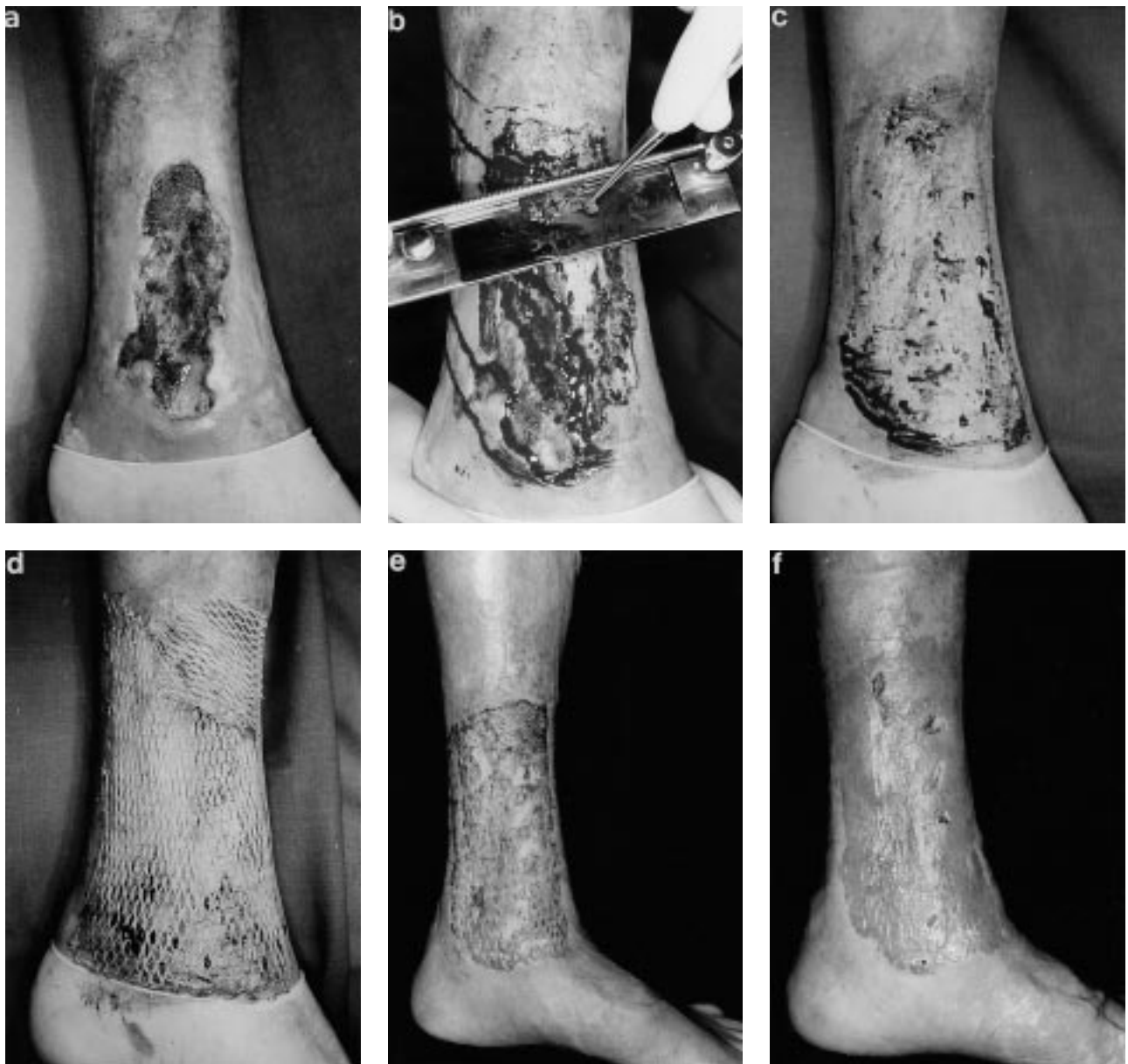

Fig. 1. Shave therapy operative procedure: (a) 66-year-old male with deep venous insufficiency in post-thrombotic syndrome. Leg ulcer of 11 years duration; (b) removal of ulcer and the surrounding lipodermatosclerosis with a Schink skin-grafting knife; (c) wound bed after shave therapy; (d) split-skin graft at the end of the operation; (e) result 2 weeks later; (f) result after 3 months, healing not yet complete.

died in the interim from diseases not related to chronic venous insufficiency; in 6 of these patients the ulcers had completely healed according to information given by close relatives.

Comparison of healing rates between patients with primary deep varicosis and those with post-thrombotic syndrome was done with the statistic program *n* Query Advisor[®].

RESULTS

Altogether, 41 patients with 75 non-healing leg ulcers were evaluated for long-term results following shave therapy. Fig. 2 shows a representative example of a circumferential ulcer which remained healed 3½ years after surgery. At an average follow-up of 2.42 years (range 1.25–4.25 years) 67% of the venous ulcers (50 of 75) were healed (Table I). All of the “mixed” ulcers (10 of 10) and 75% (12 of 16) of the ulcers covering the whole circumference of the lower leg were healed. Fisher’s exact test revealed insignificant differences ($p=0.081$) between patients with primary deep vein incompetence and post-thrombotic syndrome: in the first group the healing rate was 76%; in the second group it was 58%.

Small recurrences in the transplanted areas were found in 25 of 75 ulcers at the time of the follow-up investigation; this is a recurrence rate of 33%. However, the majority of these ulcers were only between 10% and 20% of the original ulcer area in size; most were located at the distal edge of the skin grafts. In some patients, a direct correlation between recurrence rate and discontinuation of compression therapy could be observed.

Cosmetic results were classified as very good or good by both doctors and patients; there was no extensive scarring, although in many legs a distinctive hyperpigmentation of the grafts could be observed. In 38% of patients hypaesthesia in the transplanted areas was found although none of them considered this to be a serious irritation.

Table I. Healing rates of ulcers associated with deep venous insufficiency after an average follow-up period of 2 years and 5 months after shave therapy. (The sum of ulcers in the subgroups is higher than the total number of ulcers)

All ulcers	67% (50 of 75)
“Mixed” ulcers	100% (10 of 10)
Circumferential ulcers	75% (12 of 16)
Ulcers in primary deep vein incompetence	76% (26 of 34)
Ulcers in post-thrombotic syndrome	58% (24 of 41)

DISCUSSION

Results of short- and long-term therapy in venous ulcers depend on their aetiology and on the localization of the affected veins. In ulcers caused by superficial varicosis of the great or lesser saphenous veins and/or incompetent perforator veins, long-term healing rates of 100% (16) were reported. In contrast, results in patients with deep vein damage—especially post-thrombotic syndrome—are poorer. When there were no operable superficial varicose veins and the treatment was a localized one with ulcer excision and ligation of underlying perforators and surrounding varicose veins, the long-term results were associated with the status of the deep veins. In intact deep veins, a 2-year success rate of 87% (16) was reported. In the case of post-phlebotic deep vein damage, the 2-year success rate was dependent on the degree of deep vein damage. Success rates were 80% for deep vein disease at 1 or 2 levels but only 20% if damage extended to 3 or 4 levels (16). In subfascial endoscopic perforator surgery of patients with active ulceration, healing rates after 2 years were 80% in primary valvular incompetence and 54% in post-thrombotic limbs (10). Following venous valve reconstruction in deep veins, success rates of 73% were reported in patients with primary deep vein incompetence, compared with 43% in patients with post-thrombotic syndrome (12). When looking

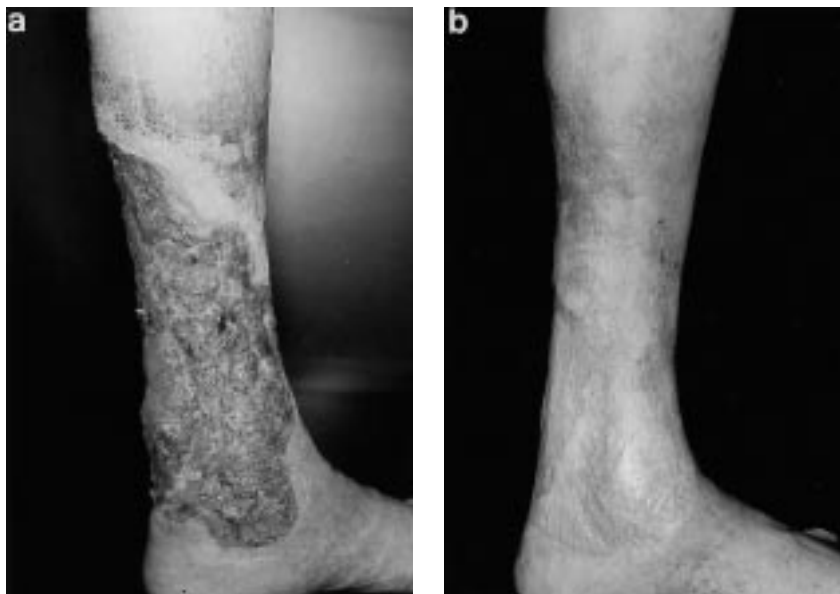


Fig. 2. 75-year-old female with primary deep vein incompetence. Circumferential leg ulcer of 15 years duration: (a) preoperative; (b) 3½ years after shave therapy.

at the results of our study, with success rates of 76% in primary deep vein incompetence and 58% post-thrombosis, one has to consider that shave therapy is a fairly simple and quick surgical method. The removal of the ulcer and surrounding lipodermatosclerosis can be performed in every theatre for all ulcers caused by deep venous insufficiency, regardless of duration, size or location. The technique is also effective in patients with venous ulcers in combination with peripheral occlusive arterial disease, where most other methods yield poor results. We cannot explain why our results were so satisfactory in these cases. Shave therapy can also be combined with removal of insufficient superficial or perforating veins.

In patients with ulcers due to chronic venous insufficiency we could demonstrate using computerized tomography (CT) and magnetic resonance imaging (MRI) morphological changes in all structures of the leg (17), including the skin, subcutaneous fat, fascia, muscles, tendons, periost and bones. Though a radical removal of all fibrotic changes in skin, subcutaneous fat and fascial sheets enclosing the muscular compartments has been advocated by various authors (4, 18, 19), the removal of ulcer and lipodermatosclerosis without the underlying fascia has proved to be beneficial as well (13, 20, 21). An average depth of shave therapy of 0.5 (0.2–1.1) cm could be demonstrated by MRI and CT 2 weeks after surgery (21). We therefore believe that the development and persistence of venous ulcers is dependent on the extent of trophic changes in the dermis and subcutaneous fat. In these areas extensive macroscopic (22, 23), microscopic and ultrastructural morphological changes (24) could be observed. In addition, functional changes in microcirculation with increased laser Doppler flow and decreased transcutaneous and intracutaneous oxygen tension (22, 25) has been noted. Removal of lipodermatosclerosis provided an improvement in microcirculation 3 months postoperatively (22), with significant differences in the parameters mentioned above. Therefore one may consider that shave therapy with skin grafting transforms a chronic wound with extensive trophic soft tissue changes in the upper and lower dermis (leg ulcer) into an acute wound in the lower subcutaneous tissue with less extensive trophic changes.

Continuous compression with elastic bandages or stockings is, however, obligatory because shave therapy is only a symptomatic treatment and does not reduce the pathological refluxes in the deep veins. Therefore, long-term results are very much dependent on the patient's compliance (compression, physiotherapy and walking) after a successful operation. In most studies (2, 3) a strong correlation between compression and recurrence rate was noted. Ulcer recurrence rates of 10–16% have been reported in patients with good usage of stockings, compared with rates of 97–100% in those with bad, or no, usage of stockings (26). Comparison of long-term therapy results in patients with deep vein damage should take this into consideration. An obvious correlation between lack of compression and recurrence could be found in some of our cases.

In conclusion, shave therapy can be successfully used for venous leg ulcers which have proved resistant to all other forms of treatment. Following surgery, continuous compression therapy is important for good long-term results. The term "non-healing venous leg ulcer" should be avoided.

ACKNOWLEDGEMENT

The authors thank Dr. H.J. Friedrich, Institute of Biometry and Statistics, Medical University of Luebeck, for his support.

REFERENCES

1. Mayer W, Jochmann W, Partsch H. Ulcus cruris: Abheilung unter konservativer Therapie. *Wien Med Wochenschr* 1994; 144: 192–195.
2. Moffatt CJ. Recurrence of leg ulcers within a community ulcer service. *J Wound Care* 1995; 4: 57–61.
3. Erickson CA, Lanza DJ, Karp DL, Edwards JW, Seabrook GR, Cambria RA, et al. Healing of venous ulcers in an ambulatory care program; the role of chronic venous insufficiency and patient compliance. *J Vasc Surg* 1995; 22: 629–636.
4. Weinzweig N, Schuler J. Free tissue transfer in treatment of the recalcitrant chronic venous ulcer. *Ann Plast Surg* 1997; 38: 611–619.
5. Kirsner RS, Mata SM, Falanga V, Kerdel FA. Split-thickness skin grafting of leg ulcers. The University of Miami Department of Dermatology's experience (1990–1993). *Dermatol Surg* 1995; 21: 701–703.
6. Sebastian G. Die Rolle der Hauttransplantation im Behandlungsplan venöser (postthrombotischer) Ulzera cruris. *Wien Med Wochenschr* 1994; 144: 269–272.
7. Warburg FE, Danielsen L, Madsen SM, Raaschou HO, Munkvad S, Siersen HE. Vein surgery with or without skin grafting versus conservative treatment for leg ulcers. *Acta Derm Venereol* 1994; 74: 307–309.
8. Coleridge Smith P. Calf perforating veins—time for an objective appraisal? [Editorial]. *Phlebology* 1996; 11: 135–136.
9. Pierik EGJM, van Urk H, Wittens CHA. Efficacy of subfascial endoscopy in eradicating perforating veins of the lower leg and its relation with venous ulcer healing. *J Vasc Surg* 1997; 26: 255–259.
10. Glovitzki P, Bergan JJ, Rhodes JM, Canton LG, Harmsen S, Ilstrup DM. Mid-term results of endoscopic perforator vein interruption for chronic venous insufficiency: Lessons learned from the North American Subfascial Endoscopic Perforator Surgery registry. *J Vasc Surg* 1999; 29: 489–502.
11. Vanscheidt W, Peschen M, Kreitlinger J, Schöpf E. Paratibial fasciotomy. A new approach for treatment of therapy-resistant venous leg ulcers. *Phlebologie* 1994; 23: 45–48.
12. Masuda EM, Kistner RL. Long-term results of venous valve reconstruction: a four- to twenty-one-year follow-up. *J Vasc Surg* 1994; 19: 391–403.
13. Quaba AA, McDowall RAW, Hackett MEJ. Layered shaving of venous leg ulcers. *Br J Plast Surg* 1987; 40: 68–72.
14. Schmeller W, Gaber Y, Gehl HB. Shave therapy is a simple, effective treatment of persistent venous leg ulcers. *J Am Acad Dermatol* 1998; 39: 232–238.
15. Classification and grading of chronic venous disease in the lower limbs: A consensus statement. *Phlebology* 1995; 10: 42–45.
16. Nachbur B, Blanchard M, Rothlisberger H. Chirurgische Therapie des Ulcus cruris. Die Bedeutung der Ausdehnung des Schadens an den tiefen Venen für die Rezidivquote beim Ulcus cruris. *Wien Med Wochenschr* 1994; 144: 264–268.
17. Schmeller W, Gmelin E, Rosenthal N. Veränderungen des Retromalleolarraums bei chronisch venösem und arthrogenem Stauungssyndrom. Ergebnisse computertomographischer und magnetresonanztomographischer Untersuchungen. *Phlebol u Proktol* 1989; 18: 175–181.
18. Pflug JJ. Operative Behandlung des supramalleolären medialen Konstriktionssyndroms bei nicht oder schlecht heilenden Ulcera cruris venosa. *Phlebologie* 1995; 24: 36–43.

19. Dunn RM, Fudem GM, Walton RL, Anderson FA, Malhotra R. Free flap valvular transplantation for refractory venous ulceration. *J Vasc Surg* 1994; 19: 525–531.
20. Galli KH, Wolf H, Paul E. Therapie des Ulcus cruris venosum unter Berücksichtigung neuerer pathogenetischer Gesichtspunkte. *Phlebologie* 1992; 21: 183–187.
21. Gaber Y, Gehl HB, Schmeller W. Magnetresonanz- und Computertomographie vor und nach Shave-Therapie venöser Ulzera. *Phlebologie* 1999; 28: 87–92.
22. Schmeller W, Roszinski S. Shave-Therapie zur operativen Behandlung persistierender venöser Ulzera mit großflächiger Dermatoliposklerose. *Hautarzt* 1996; 47: 676–681.
23. Kirsner RS, Pardes JB, Eaglstein WH, Falanga V. The clinical spectrum of lipodermatosclerosis. *J Am Acad Dermatol* 1993; 28: 623–627.
24. Tronnier M, Schmeller W, Wolff HH. Morphological changes in lipodermatosclerosis and venous ulcers: light microscopy, immunohistochemistry and electron microscopy. *Phlebology* 1994; 9: 48–54.
25. Roszinski S, Schmeller W. Differences between intracutaneous and transcutaneous skin oxygen tension in chronic venous insufficiency. *J Cardiovasc Surg* 1995; 36: 407–413.
26. Samson RH, Showalter DP. Stockings and the prevention of recurrent venous ulcers. *Dermatol Surg* 1996; 22: 373–376.