

LETTERS TO THE EDITOR

Localized Pustular Psoriasis with Onycholysis Representing a Köbner Phenomenon

Sir,

A localized exacerbation of psoriasis, a phenomenon originally observed by Köbner (1) and bearing his name ever since, can be triggered by a variety of factors, including mechanical trauma, viral infections, sunburn, frost bite or laser treatment (2–4). The lesions elicited in the course of the Köbner phenomenon resemble plaque psoriasis and are usually observed in patients with active psoriasis (2). Rarely, Köbner phenomenon is the first sign of the disease.

Here we describe an unusual case of pustular psoriasis and onycholysis induced in a previously healthy individual by burn and skin transplantation.

CASE REPORT

A 38-year-old man with no history of skin disease or family history of psoriasis was referred to our institution because of pustular changes localized in the upper extremity, chest and thighs. The medical history was negative besides alcohol abuse in the past. A month before admission the patient burned himself with boiling water in the right hand, forearm, arm and the right side of the chest. Because of a third degree burn he was admitted to the plastic surgery department where he was treated with split skin transplants harvested from the thighs. A week after transplantation he developed pustular lesions localized to the burn wounds and skin transplant donor sites (Fig. 1). At the time of referral (2 weeks after the surgery) many of his pustular lesions were dried-out which caused an impetigo-like appearance of the skin (Fig. 1). Additionally, he developed subungual hyperkeratoses and onycholysis in the right hand. *Staphylococcus aureus* was cultured from the pustules (moderate growth) and the patient was treated with dicloxacillin; however, with no effect on skin changes. Microscopy and culture for fungi were negative. Histological examination revealed epidermis with psoriasiform hyperplasia, migration of neutrophils and superficial spongiform pustulation (Fig. 2). The blood vessels in the papillary dermis were dilated and there was a perivascular infiltrate of lymphocytes, few granulocytes and plasma cells. The histological changes, which could not simply represent impetigo, led to the diagnosis of pustular psoriasis. The patient was treated with Acitretin 25 mg daily with full recovery of skin changes after 8 weeks.

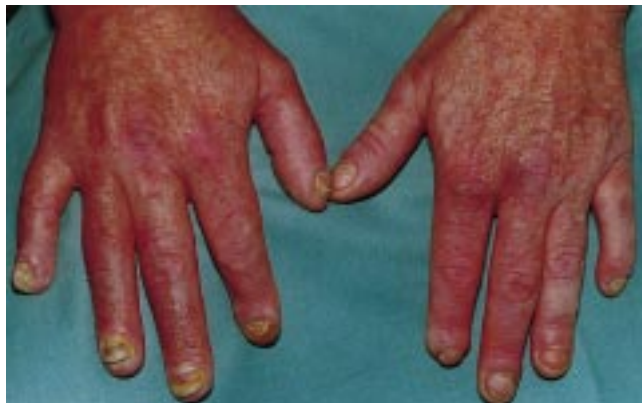

Fig. 1. Pustules, subungual hyperkeratosis and onycholysis after a third degree burn of the right hand. Note normal skin and nails on the contralateral side.

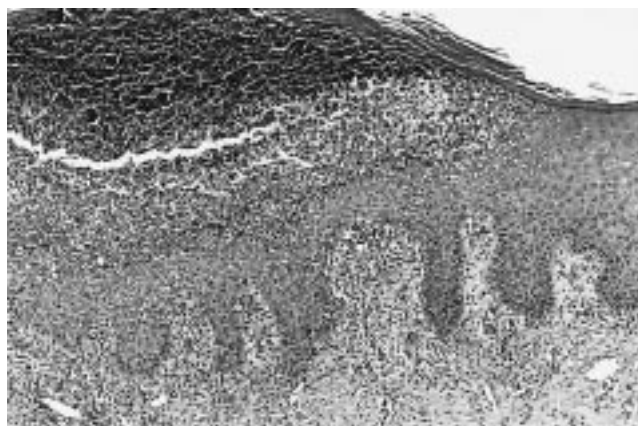


Fig. 2. Histology showing epidermis with psoriasiform hyperplasia and superficial spongiform pustulation (haematoxylin and eosin stain, $\times 100$).

DISCUSSION

To our knowledge, this is the first case of severe, localized pustular psoriasis with subungual hyperkeratosis and onycholysis induced by trauma, and thus representing the Köbner reaction. The distribution pattern followed the well-known all-or-none phenomenon (3), i.e. that Köbner reaction occurs in all sites of injury (in this case it was elicited both within the burned and the transplant donor sites). An extreme presentation of the all-or-none phenomenon was that this patient simultaneously developed both skin and nail changes in the burned hand. This observation suggests that a common pathogenic pathway may be responsible for the precipitation of skin and nail lesions in psoriasis.

In conclusion, the present observation emphasizes that the diagnosis of psoriasis must be taken into account in patients presenting with pustules and/or onycholysis following any traumatic insult even in the absence of a previous history of psoriasis.

REFERENCES

1. Köbner H. Klinische, experimentelle und therapeutische Mitteilungen über Psoriasis. Berlin Klin Wochenschr 1878; 21: 631–632.
2. Eyre RW, Krueger GG. The Köbner response in psoriasis. In: Roenigk HH, Maibach HI, eds. Psoriasis. New York: Marcel Dekker, 1985: 105–116.
3. Eyre RW, Krueger GG. Response to injury of skin involved and uninvolved with psoriasis and its relation to disease activity. Br J Dermatol 1982; 106: 153–159.
4. Bjerring P, Zachariae H, Søgaard H. The flashlamp-pumped dye laser and dermabrasion in psoriasis—further studies on the reversed Köbner phenomenon. Acta Derm Venereol 1997; 77: 59–61.

Accepted January 17, 2000.

Robert Gniadecki, Carsten Sand Petersen and Kristian Rossen²
Departments of ¹Dermatology and ²Pathology, Bispebjerg Hospital,
Bispebjerg bakke 23, DK-2400 Copenhagen NV, Denmark.