

incidences of 1 per 100,000 inhabitants or less (6, 7). In 1998, 45 cases of syphilis were registered in Denmark (6). Thus, the rise of syphilis in Eastern Europe has not yet influenced the incidence of syphilis in Denmark.

In 1989 Mindel et al. described the location of 642 penile chancres and no cases were reported with a location close to the radix penis (8). However, these cases emphasize that a lesion located close to the radix penis may be a syphilitic chancre in a condom user. Condoms do not always provide protection against a sexually transmitted disease.

REFERENCES

1. Morton RS. The treponematoses. In: Champion RH, Burton JL, Burns DA, Breathnach SM, eds. *Rook/Wilkinson/Ebling. Textbook of Dermatology*, 6th edn. Oxford: Blackwell Science, 1998: 1237–1275.
2. Sanchez J, Gotuzzo E, Escamilla J, Carrillo C, Moreyra L, Stamm W, et al. Sexually transmitted infections in female sex workers: reduced by condom use but not by a limited periodic examination program. *Sex Transm Dis* 1998; 25: 82–89.
3. Finelli L, Budd J, Spitalny KC. Early syphilis. Relationship to sex,

drugs, and changes in high-risk behavior from 1987–1990. *Sex Transm Dis* 1993; 20: 89–95.

4. Singh AE, Romanowski B. Syphilis: review with emphasis on clinical, epidemiologic, and some biologic features. *Clin Microbiol Rev* 1999; 12: 187–209.
5. Gerbase AC, Rowley JT, Heymann DH, Berkley SF, Piot P. Global prevalence and incidence estimates of selected curable STDs. *Sex Transm Infect* 1998; 74: 12–16.
6. EPI-NYT. Annual summaries and weekly reports. 1991/9, 1992/9, 1993/49, 1996/7, 1998/17, 1999/15. Statens Seruminstitut.
7. Weismann K, Petersen CS, Søndergaard J. Sexually transmitted diseases in Denmark and in an STD clinic in Copenhagen 1980–1991. *Acta Derm Venereol* 1993; 73: 313–314.
8. Mindel A, Tovey SJ, Timmins DJ, Williams P. Primary and secondary syphilis, 20 years' experience. 2. Clinical features. *Genitourin Med* 1989; 65: 1–3.

Accepted January 3, 2000.

Merete Hædersdal and Kaare Weismann
Department of Dermatology D-92, Bispebjerg Hospital, University of Copenhagen, Bispebjerg Bakke 23, DK-2400 Copenhagen NV, Denmark.
E-mail: mhaedersdal@dadnet.dk

Subungual Myiasis

Sir,

Subungual location of infestation by larvae is an unusual event that has not been sufficiently addressed in the literature (1).

CASE REPORT

A 90-year-old woman was seen in our dermatological clinic in 1999. She suffered from type-II diabetes mellitus, and had no previous history of other relevant diseases. She had noted bilateral leg swelling in the previous months, and intense pain on her right foot. She denied having intermittent claudication or symptoms of cardiac, renal or hepatic disease. On physical examination, she had bilateral pitting oedema, without varicosities. No distant pulses were felt, and she had bilateral femoral bruits. On her right first toe she had onycholysis, periungual erythema, and a distal erosion. Thoracic X-ray and laboratory test results, including blood cell count and blood chemistries, were within normal limits. Doppler ultrasound showed valvular incompetence of the veins. Only on a second visit did we realize that there were larvae under the nail (Fig. 1). We performed avulsion of the nail plate and cleaned the unguis bed. We found no signs of tissue necrosis. Larvae were identified as *Sarcophaga sp.* The patient's symptoms and oedema improved in the following days. We referred the patient to a vascular surgeon, who diagnosed non-critical lower-limb ischaemia.

DISCUSSION

This is an unusual, and hard to notice, location of myiasis. Previous reports of such infestation were induced by *Musca domestica* after trauma and subungual haematoma (1). *Sarcophaga* is a genus producing facultative myiasis, occasionally reported as infesting wounds. The presence of necrotic tissue, in a patient with diabetes mellitus and limb ischaemia, could have been a predisposing factor, but larvae are well

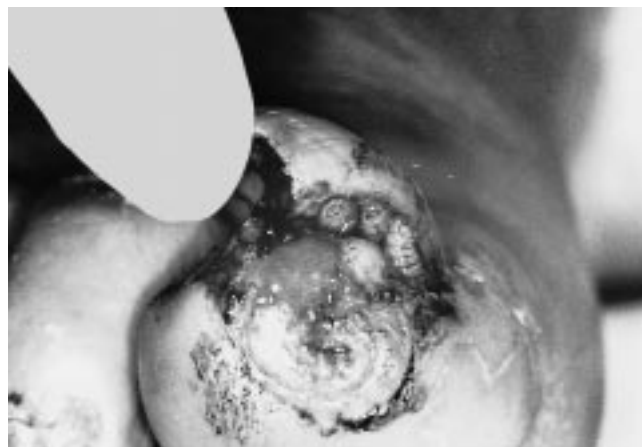


Fig. 1. On close inspection, larvae could be seen under the nail plate.

known to perform good debridement and may have avoided the detection of previous necrosis.

REFERENCES

1. Muñyon TG, Urbanc AN. Subungual myiasis. A case report and literature review. *J Assoc Milit Dermatol* 1978; 4: 60–61. Quoted in Baran R, Dawber RPR. *Diseases of the nails and their management*, 2nd edn. Oxford: Blackwell Science, 1994: 134.

Accepted January 19, 2000.

Ignacio García-Doval, Carlos de la Torre, Antonio Losada, Elena Rosón, Teresa Rodríguez, Carlos Feal and Manuel J. Cruces
Servicio de Dermatología, Hospital Provincial de Pontevedra, C/Loureiro Crespo, 2, ES-36001, Pontevedra, Spain.
E-mail: igarciad@meditex.es