

ACKNOWLEDGEMENT

We appreciate the valuable collaboration of K. Thestrup-Pedersen, MD, PhD, in reviewing the manuscript.

REFERENCES

1. Kaltoft K, Pedersen CB, Hansen BH, Lemonidis AS, Fridenberg J, Thestrup-Pedersen K. In vitro genetically aberrant T-cell clones with continuous growth are associated with atopic dermatitis. *Arch Dermatol Res* 1994; 287: 42–47.
2. International Study of Asthma and Allergies in Childhood (ISAAC) Steering Committee. Worldwide variation in prevalence of symptoms of asthma, allergic rhinoconjunctivitis, and atopic eczema: ISAAC. *Lancet* 1998; 351: 1225–1232.
3. Olesen AB, Ellingsen AR, Olesen H, Juul S, Thestrup-Pedersen K. Atopic dermatitis and birth factors: historical follow-up by record linkage. *Br Med J* 1997; 314: 1003–1008.
4. Olesen AB, Ellingsen AR, Larsen ES, Larsen PO, Veien NK, Thestrup-Pedersen K. Atopic dermatitis may be linked to whether a child is first or second born and/or the age of the mother. *Acta Derm Venereol* 1996; 76: 457–460.
5. Strachan DP. Hay fever, hygiene, and household size. *Br Med J* 1989; 299: 1259–1260.
6. Mattes J, Karmaus W, Moseler M, Frischer T, Kuehr J. Accumulation of atopic disorders within families; a sibling effect only in offsprings of atopic fathers. *Clin Exp Allergy* 1998; 28: 1480–1486.
7. Hanifin JM, Rajka G. Diagnostic features of atopic dermatitis. *Acta Derm Venereol Suppl* 1980; 92: 44–47.
8. Evans AJ. The treatment of burns in infancy and childhood. In: Mustarde JC, ed. *Plastic surgery in infancy and childhood*. Philadelphia, PA: WB Saunders, 1971: 531–560.
9. David TJ, Ewing CI. Atopic eczema and preterm birth. *Arch Dis Child* 1988; 63: 435–436.
10. Olesen AB, Thestrup-Pedersen K. The “old mother” hypothesis. In: Williams HC, ed. *Atopic dermatitis. The epidemiology, causes and prevention of atopic eczema*, 1st edn. Cambridge: Cambridge University Press, 2000: 148–154.

Accepted February 13, 2001

Carolina G. Palacios-Lopez, Luz Orozco-Covarrubias, Lourdes Tamayo-Sánchez, Carola Duran-McKinster and Ramón Ruiz-Maldonado*
Department of Pediatric Dermatology, National Institute of Pediatrics, Mexico City, Insurgentes Sur 3700-C, 04530 DF, Mexico.
*E-mail: rrm@servidor.unam.mx

Molluscum Contagiosum on a Tattoo

Sir,

Molluscum contagiosum following tattooing practice is a very rare event. Here we report the second case, to our knowledge.

CASE REPORT

A 20-year-old Caucasian woman was admitted to our Institute because of the appearance of several papular lesions localized exclusively on the left forearm. The lesions had appeared in the context of a tattoo which had been created 3 weeks earlier. The patient stated that she was in good general health and that she was not on any therapy.

Dermatological examination revealed the presence of 10 papules which were localized exclusively within the tattoo: they were round, 2–4 mm in diameter, of different colours (from pearly to bluish), shiny and of a parenchymatous–hard consistency (Fig. 1). All papules were asymptomatic. No similar lesions were found on other areas of the skin surface or mucous membranes.

A general physical examination did not reveal anything pathological. All laboratory examinations, including tests for human immunodeficiency virus (HIV) infection, were within the normal range or negative. Histopathological examination, obtained from a shaving of a lesion, confirmed the clinical diagnosis of molluscum contagiosum (Fig. 2).

The patient refused all treatments that we suggested.

DISCUSSION

The practice of tattooing can transmit, albeit rarely, some severe systemic infectious diseases, such as hepatitis B and C (1–14), acquired immunodeficiency syndrome (AIDS) (15), tetanus (1, 10) and septicaemia (1). Several infectious diseases of the skin can also be transmitted, in particular warts (1, 6, 14, 16–18), but also rubella (10), vaccinia (1), impetigo (1, 10), erysipelas (1, 10), ecthyma (1, 10), cellulitis (1, 10), gangrene (1), chancroid (1, 10), syphilis (1, 6, 10, 14), cutaneous tuberculosis (1, 6, 10, 14, 18) and leprosy (1, 10, 14, 19–21). To our knowledge, only one previous case of

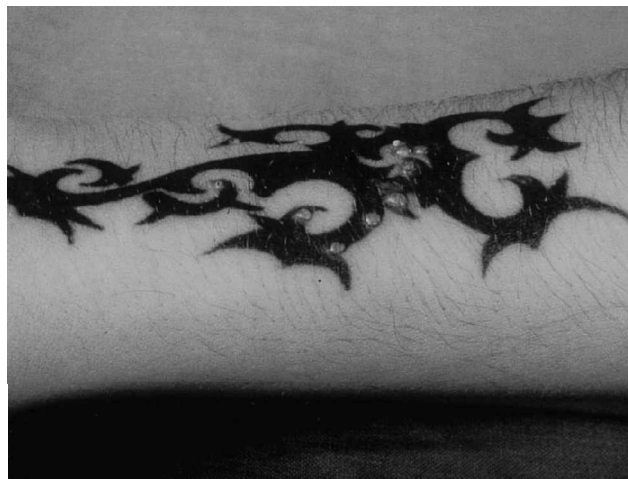

Fig. 1. Papules limited to within the area of the tattoo.

molluscum contagiosum following tattooing has been reported (22).

It is very likely that the appearance of molluscum contagiosum is related to tattooing, since all lesions appeared following tattooing and exclusively within the area covered by the tattoo. At least two pathogenetic hypotheses may be advanced: (i) viruses may have been transmitted by the instruments used for tattooing; this is the most likely hypothesis; or (ii) the ink may have been contaminated by viruses. Furthermore, some authors (17) have suggested that black dye can decrease locally either cell-mediated or humoral immunity. It seems highly unlikely that the patient had

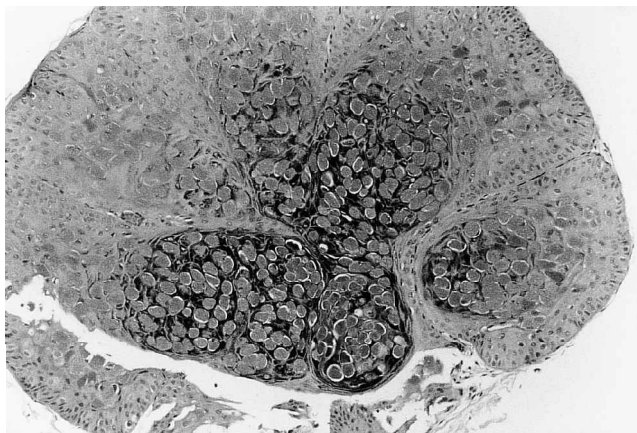


Fig. 2. Nodular lesion with clusters of keratinocytes characterized by nuclear amorphous eosinophilic material. (Haematoxylin & eosin, $\times 200$.)

clinically non-visible molluscum contagiosum in the area that was subsequently subjected to tattooing.

REFERENCES

1. Watkins DB. Viral disease in tattoos: verruca vulgaris. *Arch Dermatol* 1961; 84: 174–177.
2. Gostling JV. Long-incubation hepatitis and tattooing. *Lancet* 1971; ii: 1033.
3. Sterner G, Agell B-O, Gerzén P, Berg R. Hepatitis with Australia antigen after tattooing. *Scand J Infect Dis* 1971; 3: 109–112.
4. Gostling JV. Long-incubation hepatitis and tattooing. *Lancet* 1972; i: 382.
5. Roberts DM. Long-incubation hepatitis and tattooing. *Lancet* 1972; i: 1016.
6. Scutt RWB. The medical hazards of tattooing. *Br J Hosp Med* 1972; 8: 194–202.
7. Mowat NA, Brunt PW, Albert-Recht F, Walker W. Outbreak of serum hepatitis associated with tattooing. *Lancet* 1973; i: 33–34.
8. Hopkins GB, Gostling JVT, Hill I, McNab DJN, Mullan DP, Scutt RWB, Wright EA. Hepatitis after tattooing: a fatal case. *Br Med J* 1973; 873: 210–211.
9. Limentani AE, Elliot LM, Noah ND, Lamborn JK. An outbreak of hepatitis B from tattooing. *Lancet* 1979; ii: 86–88.
10. Goldstein N. IV. Complications from tattoos. *J Dermatol Surg Oncol* 1979; 5: 869–878.
11. Harrison MA, Noah ND. Hepatitis B from tattooing. *Lancet* 1980; ii: 644.
12. Abildgaard N, Peterslund NA. Hepatitis C virus transmitted by tattooing needle. *Lancet* 1991; 338: 460.
13. Ko Y-C, Ho M-S, Chiang T-A, Chang S-J, Chang P-Y. Tattooing as a risk of hepatitis C virus infection. *J Med Virol* 1992; 38: 288–291.
14. Long GE, Rickman LS. Infectious complications of tattoos. *Clin Infect Dis* 1994; 18: 610–619.
15. Doll DC. Tattooing in prison and HIV infection. *Lancet* 1988; i: 66–67.
16. Young DF, Cole GW. The verrucous mermaid. *Int J Dermatol* 1979; 18: 816–817.
17. Miller DM, Brodell RT. Verruca restricted to the areas of black dye within a tattoo. *Arch Dermatol* 1994; 130: 1453–1454.
18. Horney DA, Gaither JM, Lauer R, Norins AL, Mathur PN. Cutaneous inoculation tuberculosis secondary to “jailhouse tattooing”. *Arch Dermatol* 1985; 121: 648–650.
19. Sehgal VN. Inoculation leprosy appearing after seven years of tattooing. *Dermatologica* 1971; 142: 58–61.
20. Sehgal VN. Upgrading borderline tuberculoid (subpolar tuberculoid tuberculoid) developing in tattoos. *Int J Dermatol* 1987; 26: 332–333.
21. Sehgal VN. Inoculation leprosy. Current status. *Int J Dermatol* 1988; 27: 6–9.
22. Foulds IS. Molluscum contagiosum: an unusual complication of tattooing. *Br Med J* 1982; 285: 607.

Accepted January 31, 2001.

Flavia Salmaso, Luigi Gneccchi, Raffaele Gianotti and Stefano Veraldi*
 Institute of Dermatological Sciences, IRCCS, University of Milan,
 Via Pace 9, IT-20122 Milan, Italy. *E-mail: stefano.veraldi@libero.it