

CLINICAL REPORT

Cutaneous Infection with *Mycobacterium fortuitum* after Localized Microinjections (Mesotherapy) Treated Successfully with a Triple Drug Regimen

EDUARDO NAGORE¹, PILAR RAMOS², RAFAEL BOTELLA-ESTRADA¹, JOSÉ A. RAMOS-ÑÍGUEZ³, ONOFRE SANMARTÍN¹ and PILAR CASTEJÓN⁴

¹Department of Dermatology, Instituto Valenciano de Oncología, Valencia and Departments of ²Microbiology, ³Pathology and ⁴Dermatology, Hospital Francesc de Borja, Gandia, Spain

Mesotherapy is a treatment method devised for controlling pain syndromes or diseases by subcutaneous microinjections given at or around the involved areas at short intervals of time. Different adverse effects have been described due to this modality of treatment. This report describes 3 patients with cutaneous infection caused by *Mycobacterium fortuitum* after mesotherapy. Three women, aged 24, 27 and 44 years, presented with similar clinical features, consisting of painful nodules located at the points where mesotherapy had been applied. A smear from a skin biopsy revealed the presence of acid-fast bacilli in all 3 cases. The specimen was cultured and eventually identified as *M. fortuitum*. A multidrug long-term regimen (combinations of 3 drugs from the following: ciprofloxacin, cotrimoxazole, clarithromycin and amoxicillin–clavulanic acid) was needed to achieve resolution of the lesions. After 15, 25 and 26 months of follow-up, no patient relapsed. *Mycobacterium fortuitum* is a rapidly growing mycobacterium that can lead to cutaneous infection after minor surgical procedures when aseptic measures are not adequate. Multiple drugs for several months are usually needed to treat this disease successfully. **Key words:** mesotherapy; *Mycobacterium fortuitum*; treatment.

(Accepted April 23, 2001.)

Acta Derm Venereol 2001; 81: 291–293.

Eduardo Nagore, C/Denia, 20-6, 46006 Valencia, Spain.
E-mail: eduyame@meditex.es

Mesotherapy is a therapeutic methodology belonging to homeopathic medicine which is usually administered by alternative medical practitioners. It is a treatment method devised for controlling pain syndromes or diseases by microinjections at the point on the body where the pain is felt or the disease is present. Its goal is to apply an adequate amount of medication directly to the problem point and to avoid oral medications. In this way a mixture of readily available drugs is administered. Mesotherapy is mostly applied for osteoarticular problems.

Different secondary effects have been previously reported, usually due to allergic reactions to the administered drugs (1). Two previous reports in the French literature have emphasized the potential danger of cutaneous infection after treatment with mesotherapy (1, 2).

This report describes 3 cases with atypical mycobacterial infection after mesotherapy administration by a single practitioner, most probably due to inadequate antiseptic measures.

CASE REPORTS

Patient 1

A 44-year-old woman was referred for painful nodules on the right thigh. Nodules appeared on the site where she had previously received 15 sessions of mesotherapy because of an osteoarticular affliction of her knee. This treatment consisted of receiving microinjections with a mixture of procaine, piroxicam and pentoxifilin weekly for 3 months, and the skin lesions appeared 3 weeks after the last session.

On examination 2 subcutaneous nodules were found. These were purple, tender and painful on pressure (Fig. 1). There were no palpable inguinal lymph nodes or other physical findings.

One nodule was biopsied and the piece was cut into 2 parts: one for histopathological study and the other for culture and direct microscopic examination with Ziehl–Nielsen stain. Direct examination showed acid-fast bacilli. Histopathological study showed a perivascular lymphocytic infiltrate in the dermis, and an intense neutrophil and histiocytic infiltrate occupying the entire subcutaneous cellular tissue, with abscesses and granulomas (Fig. 2). Ziehl–Nielsen, Gram and Giemsa stains were negative.

Culture of biopsy material was positive for mycobacteria after 6 days and was identified as *Mycobacterium fortuitum* complex (MFC).

Treatment with minocycline (100 mg/12 h) was given for 3 weeks with no response. Monotherapy with cotrimoxazole (800/160 mg/12 h) for 3 weeks was also unsuccessful. Then a regimen with ciprofloxacin (500 mg/12 h), clarithromycin (500 mg/12 h) and amoxicillin–clavulanic acid (500 mg/12 h) for 3 weeks followed by 3 months with clarithromycin (500 mg/12 h) was given according to the results of the drug susceptibility study. Forty-eight hours after starting the treatment, the patient developed a rash; consequently all drugs were stopped and restarted consecutively at intervals of 3 days. Ciprofloxacin was

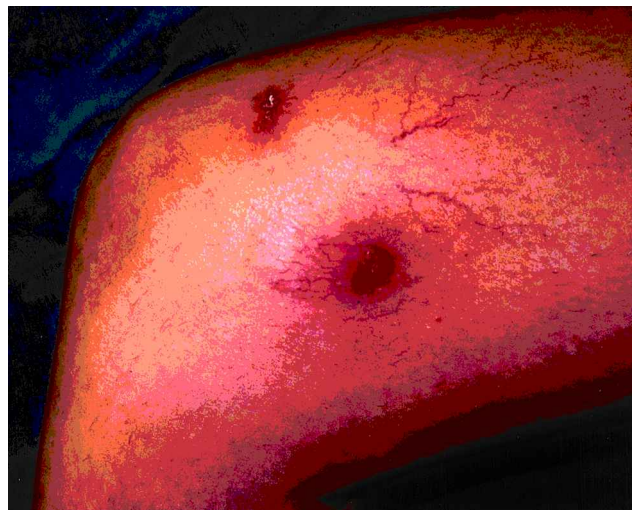

Fig. 1. Two subcutaneous nodules on the right thigh of patient 1. The nodules were purple, tender and painful on pressure.

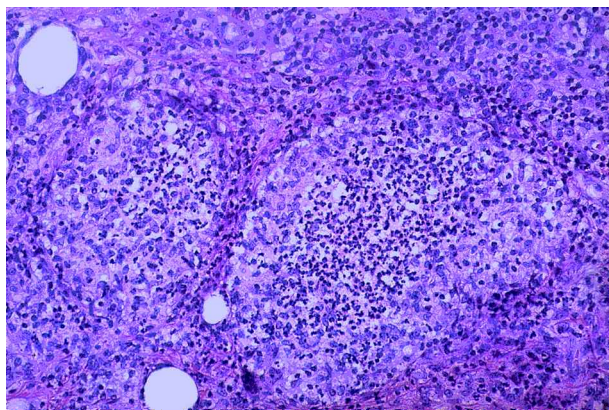


Fig. 2. Abscesses of neutrophils surrounded of histiocytes in the subcutaneous cellular tissue. (H&E, 100 ×).

identified as the aetiological drug and was substituted with cotrimoxazole (800/160 mg/12 h). The nodules had improved on the 15th day after starting treatment and had completely disappeared in 5 weeks. The patient remained free of symptoms for 26 months.

Patient 2

A 24-year-old woman presented with a one-week history of painful nodules on the right thigh. Nodules appeared on the site where she had previously received one session of mesotherapy because a tenosynovitis of the right abductor tendon. The treatment modality was the same as in patient 1, although the skin lesions appeared 3 weeks after the first and only session.

On examination 3 subcutaneous nodules, which were tender, erythematous and painful on pressure, were found. Physical examination was otherwise unremarkable.

Diagnostic tests and results were the same as in patient 1.

A multidrug treatment was considered because of the previous experience with patient 1. The same treatment regimen given to patient 1 (with ciprofloxacin, clarithromycin and amoxicillin-clavulanic acid) was empirically administered and no adjustment was needed after the results of the drug sensibility became available several weeks later. The lesions began to improve after 2 weeks and healed on the 6th week. No relapse was noted after 25 months.

Patient 3

A 27-year-old woman related a 4-year history of painful nodules on the thighs and abdomen. Nodules appeared on the site where she had previously received several sessions of mesotherapy to treat obesity 4 years before. Every single lesion was progressively and spontaneously scarring while new ones appeared. The diagnostic procedures and results were identical to those in the 2 previous cases. Treatment was given under the same conditions as in patient 2 and consisted of ciprofloxacin (500 mg/12 h), clarithromycin (500 mg/12 h) and cotrimoxazole (800/160 mg /12 h) for 3 weeks followed by 3 months with clarithromycin (500 mg/12 h). All of the active lesions lessened after 2 weeks and completely healed on the 6th week with remaining residual scars. No new lesions appeared after 15 months.

DISCUSSION

MFC includes different biovariants of rapidly growing mycobacteria that belong to group IV of the Runyon classification. MFC has been isolated from natural and tap water, soil and dust. It has also been isolated from respiratory specimens, but frequently these isolates are not clinically significant. MFC organisms are responsible for a number of different types of infections which tend to be subacute or chronic, recurrent and resistant to treatment (3). Most of them are soft-tissue

and skeletal infections that result from direct inoculation of contaminated materials via injections, surgery and penetrating trauma (3–5). When the infection is related to the insertion of an intravenous catheter, disseminated disease can occur (3). Diagnosis should be made through the culture of biopsy material; in the case of ulcers, the sample should be collected from the periphery of the lesion. MFC grows quickly, usually in less than 1 week, at 35–37°C (6).

Almost all strains of MFC are resistant to the drugs used for the treatment of tuberculosis and resistance when the regimen includes only one agent is not unusual (3, 7). The best treatment regimen has yet to be determined and, when possible, should be based on *in vitro* susceptibility studies. Clarithromycin, ciprofloxacin, amikacine and ceftioxin are considered as first-line drugs. Alternative drugs are doxycycline, imipenem, etambutol, cotrimoxazole and amoxicillin-clavulanic acid. A combined regimen, preferably with 3 drugs, should be used for 2–4 weeks followed by ciprofloxacin or clarithromycin for 3 months (8–10).

The regimen designed for these patients was based on safety and ease of administration. Nevertheless, in patient 1, ciprofloxacin was withdrawn because of cutaneous toxicity and substituted with cotrimoxazole. Except for patient 1, in whom the delay in the administration of the definitive regimen allowed adjustment to be made according to drug susceptibility studies, an empirical regimen was initially used to begin early and achieve healing with the minimum sequelae. However, the suitability of the regimen was subsequently confirmed with the drug susceptibility studies. The response was excellent and lesions resolved with minimal scars in all 3 patients.

Although surgical debridement has been proposed together with antibiotic treatment, it usually causes disfiguring scars and should not be considered as a first-line treatment except when an adequate regimen has failed.

The best attitude is prevention. Contaminated instruments have been suggested to be the source of infection (9). Iodine, formaline and other acid antiseptics may be used to avoid this complication. Standardization of aseptic measures in daily medical practice could prevent the infectious complications of mesotherapy.

REFERENCES

- Guillaume JC, Jouffroy L, Touraine R. Complications cutanées de la mésothérapie (2 observations). *Ann Dermatol Venerol* 1984; 111: 701–702.
- Friedel J, Piemont Y, Truchetet F, Cattani E. Mésothérapie et mycobactériose cutanée à *Mycobacterium fortuitum*: une “médecine douce” à risque. *Ann Dermatol Venerol* 1987; 114: 845–849.
- Wallace RJ Jr, Swenson JM, Silcox VA, Good RC, Tschien JA, Stone MS. Spectrum of disease due to rapidly growing mycobacteria. *Rev Infect Dis* 1983; 5: 657–679.
- Grange JM, Noble WC, Yates MD, Collins CH. Inoculation mycobacterioses. *Clin Exp Dermatol* 1988; 13: 211–220.
- Hoffman PC, Fraser DW, Robicsek F, O’Bar PR, Mauney CU. Two outbreaks of sternal wound infection due to organisms of the *Mycobacterium fortuitum* complex. *J Infect Dis* 1981; 143: 533–542.
- Metchock BG, Nolte FS, Wallace Jr, RJ. *Mycobacterium*. In: Murray PR, Baron EJ, Pfaller MA, Tenover FC, Tenover RH, eds. *Manual of clinical microbiology*. Washington, DC: ASM Press, 1999: 399–437.

7. Inderlied CB, Salfinger M. Antimycobacterial agents and susceptibility tests: Mycobacteria. In: Murray PR, Baron EJ, Pfaller MA, Tenover FC, Tenover RH, eds. *Manual of clinical microbiology*. Washington, DC: ASM Press, 1999: 1601–1623.
8. Wolinsky E. Mycobacterial diseases other than tuberculosis. *Clin Infect Dis* 1992; 15: 1–12.
9. Goldberg GS, Orkin B, Smith LE. Microbiology of human immunodeficiency virus anorectal disease. *Dis Colon Rectum* 1994; 37: 439–443.
10. American Thoracic Society. Diagnosis and treatment of disease caused by nontuberculous mycobacteria. *Am J Respir Crit Care Med Suppl* 1997; 156: S1–S25.