

## CLINICAL REPORT

# Angioedema Due to Acquired Deficiency of C1-Esterase Inhibitor Associated with Leucocytoclastic Vasculitis

HENRIETTE FARKAS<sup>1</sup>, MARIANN SZONGOTH<sup>2</sup>, MIKLÓS BÉLY<sup>3</sup>, LILIAN VARGA<sup>4</sup>, BÉLA FEKETE<sup>5</sup>, ISTVÁN KARÁDI<sup>5</sup> and GEORGE FÜST<sup>5</sup>

<sup>1</sup>Allergology and Angioedema Outpatient Clinic of the Semmelweis University, Kútívölgyi Clinical Centre, Budapest, Hungary; <sup>2</sup>A' Department of Rheumatology of the National Institute of Rheumatology and Physiotherapy, Budapest, Hungary; <sup>3</sup>Department of Pathology of the National Institute of Rheumatology and Physiotherapy, Budapest, Hungary; <sup>4</sup>Complement Laboratory of the National Institute of Haematology and Immunology, Budapest, Hungary; <sup>5</sup>Third Department of Internal Medicine of the Semmelweis University; Budapest, Hungary

**A hereditary and an acquired type of C1-esterase inhibitor deficiency have been described. Manifestations characteristic of both forms include recurrent subcutaneous and submucosal angioedema. Acquired C1-esterase inhibitor deficiency has been observed in association with lymphoproliferative disorders, malignancy, autoimmune diseases and infections. We report on a case with the acquired form of the disease accompanied by leucocytoclastic vasculitis. Treatment with antimalarial agents resulted in complete resolution of symptoms and signs. Furthermore, C1-esterase inhibitor concentration and activity, as well as C1 levels, all returned to normal. Key words: acquired angioedema; vasculitis; C1-esterase inhibitor deficiency.**

(Accepted May 16, 2001)

Acta Derm Venereol 2001; 81 298–300.

Henriette Farkas, MD, PhD, Allergology and Angioedema Outpatient Clinic, Semmelweis University, Kútívölgyi Centre, H-1125 Budapest, Hungary, Kútívölgyi út 4.  
E-mail: farkash@kut.sote.hu

The C1-esterase inhibitor (C1-INH) is an important regulatory protein of the complement system (1). Spontaneous activation of the classical complement pathway and blood coagulation cascades, as well as the fibrinolytic and plasma kinin systems, occurs in its absence (2).

Deficiency of C1-INH triggers the release of vasoactive mediators that increase vascular permeability. This can result in oedema formation in the subcutis (of the extremities, face, genitals) and the submucosa. Laryngeal oedema is a potentially fatal complication, whereas gastrointestinal manifestations can mimic the symptoms and signs of an acute abdominal catastrophe. The autosomal-dominant variant of C1-INH deficiency is hereditary angioedema (HAE). The acquired form of C1-INH deficiency (AAE) occurs in association with lymphoproliferative diseases (3), malignancy (4), immune disorders (5) and infections (6). The clinical manifestations of HAE and AAE are identical (7).

A review of the literature revealed only one case of angioedema, where acquired C1-INH deficiency was associated with vasculitis of the Churg–Strauss type (8). Our report describes a case of AAE with angioedema and leucocytoclastic vasculitis (9, 10).

## CASE REPORT

The history of the 40-year-old Caucasian woman was unremarkable. Her symptoms started at the beginning of August 1997 with the

development of two types of recurrent cutaneous lesions. Generalized, non-pruritic urticarial eruptions were visible for 3 to 4 days before they resolved spontaneously and completely, but recurred weekly. Furthermore, palpable purpura developed symmetrically on both lower extremities and persisted for 2 weeks. She had not taken any medication before the onset of symptoms. Chronic tonsillitis was a potential triggering factor; however, tonsillectomy did not result in any improvement. Furthermore, spontaneous angioedema of the face and extremities recurred on multiple occasions. Initially, symptoms resolved spontaneously within 2 days. The patient experienced paroxysms of colicky abdominal pain, accompanied by ascites demonstrated by abdominal ultrasonography. On one occasion during September 1997, oedema involved the pharynx and larynx and was only slowly alleviated by antihistamines and corticosteroids. In the end of September 1997, the patient was admitted for clinical work-up.

Routine laboratory parameters (haematology, clinical chemistry and urinalysis) were unremarkable. Thyroid hormone levels (T3, T4 and TSH), serum protein and immune electrophoresis, ESR and peripheral eosinophil cell count were in the normal range. Antinuclear, anti-dsDNA, anti-RNP, anti-Sm, anti-thyroglobulin anti-TPO, ANCA, and anti-cardiolipin could not be detected in the serum; total IgE level was normal. Quantitative rheumatoid factor was 20–80 IU/ml and ANA was positive (produced a speckled pattern) on one occasion. Throat swabs and antistreptolysin-O titres were normal.

The level of circulating immune complexes was low, no cryoglobulin or cryofibrinogen could be detected. Chronic viral infections were ruled out by performing the appropriate serologic tests. Major systemic diseases and focal inflammatory disorders were excluded by thorough clinical work-up.

## Histopathology and immunohistochemistry

Biopsy samples were placed in 8% formaldehyde solution (pH 7.6) and embedded in paraffin. Serial sections were cut and stained with haematoxylin-eosin, PAS, lightgreen-orcein or Sirius red F3BA. Vasculitis was identified and characterized by histological evaluation or by streptavidin-biotin complex/horseradish peroxidase (SABC/PO) immunohistochemical reaction.

Biopsy of a purpuric skin lesion showed leucocytoclastic vasculitis involving the capillaries and arterioles in the superficial layers of the cutis and sparing the deeper layers. Within the vasculitic foci, infiltration by inflammatory cells with marked LCA positivity was seen. The majority of cells in the infiltrates were CD3 T-lymphocytes interspersed with CD20 B-lymphocytes and some granulocytes. Labelled monoclonal antibodies to endothelium-specific linear CD31 and factor VIII showed diffuse positivity in vessel walls and the perivascular region (Fig. 1a, b).

## Complement studies

CH50 or total haemolytic complement assay, which measures the activity of the classical pathway, as determined using the method of Mayer (11). Haemolytic activity of the first component of the complement system (C1) was measured according to Nelson et al. (12). Results were expressed in complement haemolytic units per millilitre serum (CH<sub>50</sub>/ml for CH50 and CH<sub>63</sub>/ml for C1).

To quantify C4-, C3- and C1-INH levels, radial immunodiffusion

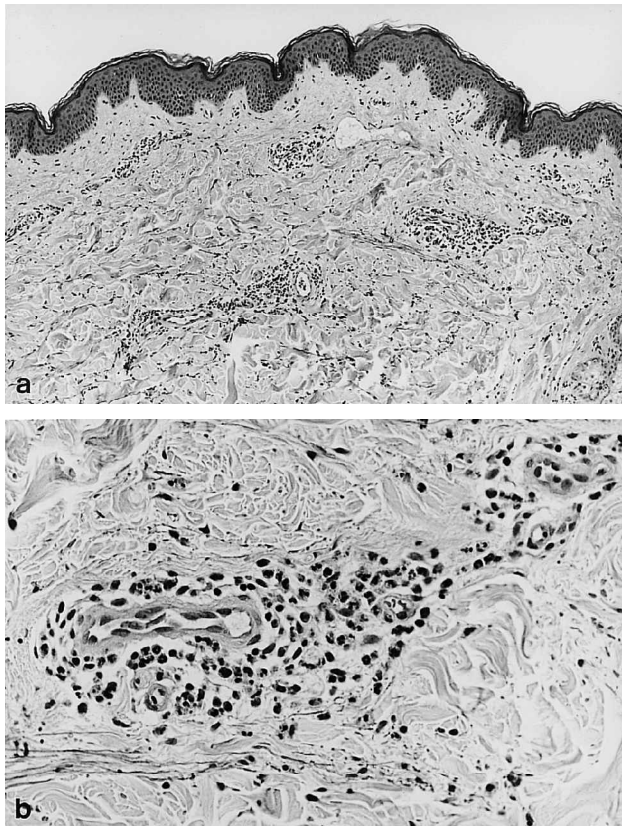


Fig. 1. Leucocytoclastic vasculitis of cutaneous capillaries and arterioles. (a) haematoxylin-eosin stain; original (50 ×) magnification; (b) the same stain and region, but viewed at 125 × magnification.

was applied using antibodies from ATAB and an in-house calibrator serum. C1-INH activity was measured with a kinetic assay kit (Behringwerke AG). Autoantibodies to C1-INH were tested by the method of Cicardi et al. (3) and IgG type antibodies against C1q were measured by the solid phase ELISA method of Siegert et al. (13). Investigation of the complement system (low C1-INH concentration and activity along with low C1 and C4 levels) confirmed the tentative diagnosis of acquired C1-INH deficiency (Table I).

*Clinical course*

Acute oedema and skin lesions resolved slowly and only partially after the parenteral administration of prednisolone and antihistamines.

Table I. Changes of complement component levels between September 1997 and February 2000. Normal ranges are given in parentheses

Dates of complement tests	CH50 (48–103 units/ml)	C4 (36–144%)	C3 (0.7–1.8 mg/ml)	C1-INH level (64–166%)	C1-INH activity (85–125%)	C1 (4000–33,000 units/ml)
Sept. 1997	18.7	36.8	0.76	42	40.4	2478
Oct. 1997	18.1	16.1	0.64	95.7	72.4	3343
Feb. 1998	11	18	0.52	84.6	N.D.	12,455
Dec. 1998	13	19	0.73	72	N.D.	N.D.
Jan. 1999	15	11	0.17	79	95	N.D.
Feb. 2000	16	28	0.87	83	98.5	15,000

N.D. = not done. CH50 = total haemolytic activity of the classical complement pathway. C4 = serum concentration of C4 complement component expressed as percentage of the normal serum pool. C3 = serum concentration of C3 complement component. C1-INH level = antigen concentration of C1-esterase inhibitor expressed as percentage of the normal serum pool. C1-INH activity = functional activity of C1-esterase inhibitor protein expressed as percentage of the normal serum pool. C1 = haemolytic activity of the first component of the complement system.

Therefore, and owing to the histologic evidence of vasculitis as well as the painfulness of cutaneous lesions, chloroquine (150 mg b.i.d.) was initiated. Since angiooedematous attacks did not recur, specific treatment (antifibrinolytics, androgens, C1-INH concentrate) was not initiated.

Corneal opacities appeared after 3 months of treatment on chloroquine, which was therefore replaced with hydroxychloroquine (initial dose of 400 mg/day tapered to 200 mg/day maintenance dose). Ocular signs remained stable subsequently. The resolution of skin symptoms was complete after 3 months and no relapses have occurred up to now.

The efficacy of treatment was also demonstrated by the normalization of C1-INH level and activity, as well as of C1 haemolytic activity. C4 and CH50 concentrations, however, remained permanently low. C3 levels were low-normal or normal during follow-up (Table I). Anti-C1q autoantibodies were found in the serum of the patient, but anti-C1-INH autoantibodies could not be detected.

DISCUSSION

AAE is an uncommon disorder first described by Caldwell et al. in 1972 (14). Subsequently, several observations have been published on the association of acquired C1-INH deficiency with various diseases. Our case is an example of acquired C1-INH deficiency accompanied by angiooedema and associated with leucocytoclastic vasculitis. Complement measurements established the diagnosis of AAE and skin biopsy confirmed the diagnosis of vasculitis. The absence of autoantibodies against C1-INH was suggestive of acquired – Type I – C1-INH deficiency. This would suggest an aetiologic role of the enhanced consumption of complement factors possibly related to vasculitis. C1-INH level was low at the onset of clinical symptoms (i.e. at the beginning of the observation period), but returned into the normal range after treatment. However, this was not accompanied by the normalization of C4 and C3 levels. C1q antibodies may have a role in the pathogenesis of vasculitis by contributing to the formation and deposition of immune complexes in the wall of cutaneous vessels (9, 13). Considering that a finding of permanently low CH<sub>50</sub>, C3 and C4 levels is a potential harbinger of future systemic disease, the patient is being followed-up closely. This is in agreement with the observation that angiooedema associated with transiently low C1-INH levels may occasionally occur in systemic autoimmune disorders (15). Drug therapy with antimalarial agents achieved complete symptomatic relief and full resolution of clinical manifestations. This concurs with the observation of Pasquali et al. (8), who reported on the beneficial effect of corticosteroids in

Churg–Strauss vasculitis. This remarkable case substantiates the observation that successful treatment of underlying disease is the cornerstone of the therapy of angioedema related to acquired C1-INH deficiency.

#### ACKNOWLEDGEMENTS

This work was supported by grants ETT 21/2000, FKFP-0106/2000, OTKA T-025449 and OTKA T-029044.

#### REFERENCES

1. Donaldson VH, Evans RR. A biochemical abnormality in hereditary angioedema: absence of serum inhibitor of C1-esterase. *Am J Med* 1963; 35: 37–44.
2. Nielsen EW, Johansen HT, Hogasen K, Wuillemin W, Hack CE, Mollnes TE. Activation of the complement, coagulation, fibrinolytic and kallikrein systems during attacks of hereditary angioedema. *Immunopharmacology* 1996; 33: 359–360.
3. Cicardi M, Beretta A, Colombo M, Gioffre D, Cugno M, Agostoni A. Relevance of lymphoproliferative disorders and of anti-C1 inhibitor autoantibodies in acquired angioedema. *Clin Exp Immunol* 1996; 106: 475–480.
4. Wasserfallen J-B, Spaeth P, Guillou L, Pecoud AR. Acquired deficiency in C1-inhibitor associated with signet ring cell gastric adenocarcinoma: a probable connection of antitumor-associated antibodies, hemolytic anemia, and complement turnover. *J Allergy Clin Immunol* 1995; 95: 124–131.
5. Nakamura S, Yoshinari M, Saku Y, Hirakawa K, Miishama C, Murai K, et al. Acquired C1-inhibitor deficiency associated with systemic lupus erythematosus affecting the central nervous system. *Ann Rheum Dis* 1991; 50: 713–716.
6. Farkas H, Csepregi A, Nemesánszky E, Pár A, Gyenyey L, Varga L, et al. Acquired angioedema associated with chronic hepatitis C. *J Allergol Clin Immunol* 1999; 103: 711–712.
7. Agostoni A, Cicardi M. Hereditary and acquired C1-inhibitor deficiency: biological and chemical characteristics in 235 patients. *Medicine* 1992; 71: 206–215.
8. Pasquali J-L, Christmann D, Modert F, Belval PC, Storck D, Hauptmann G. First case of acquired functional C1-INH deficiency: association with angioedema during Churg and Strauss vasculitis. *Int Arch Allergy Appl Immunol* 1984; 74: 284–285.
9. Siegert CEH, Kzatchkine MD, Sjöholm A, Wurzner R, Loos M, Daha MR. Autoantibodies against C1q: view on clinical relevance and pathogenic roles. *Clin Exp Immunol* 1999; 116: 4–8.
10. Lee Coldman, Bennett JC, editors. *Cecil textbook of medicine*, 21st ed. Philadelphia: W. B. Saunders Company. 2000: 1524–1534.
11. Mayer MM. Complement and complement fixation. In: Kabat EA, Mayer MM, editors. *Experimental immunochemistry*. Springfield, IL: Thomas. 1962: 133–140.
12. Nelson RA Jr, Jensen J, Gigli I, Tamura N. Methods for the separation, purification and measurement of nine components of hemolytic complement in guinea pig serum. *Immunochemistry* 1966; 3: 111–135.
13. Siegert CEH, Daha MR, van der Voort EAM, Breedveld FC. IgG and IgA antibodies to the collagen like region of C1q in rheumatoid vasculitis. *Arthritis Rheum* 1990; 33: 1646–1654.
14. Caldwell JR, Rudi S, Schur PH, Austen KF. Acquired C1 inhibitor deficiency in lymphosarcoma. *Clin Immunol Immunopathol* 1972; 1: 3952.
15. Jazwinska EC, Gatenby PA, Dunckley H, Serjeantson SW. C1 inhibitor functional deficiency in systemic lupus erythematosus (SLE). *Clin Exp Immunol* 1993; 92: 268–273.