

## CLINICAL REPORT

# Squamous Cell Carcinoma in Junctional and Dystrophic Epidermolysis Bullosa

F. WEBER<sup>1</sup>, J. W. BAUER<sup>2</sup>, N. SEPP<sup>1</sup>, W. HÖGLER<sup>3</sup>, W. SALMHOFER<sup>4</sup>, H. HINTNER<sup>2</sup> and P. FRITSCH<sup>1</sup>

<sup>1</sup>Department of Dermatology and Venereology, University of Innsbruck, Innsbruck, Austria, <sup>2</sup>Department of Dermatology, General Hospital, Salzburg, Austria, <sup>3</sup>Department of Pediatrics, University of Innsbruck, Innsbruck, Austria and <sup>4</sup>Department of Dermatology and Venereology, University of Graz, Graz, Austria

**We report here on three patients suffering from recessive dystrophic epidermolysis bullosa and one suffering from generalized atrophic benign epidermolysis bullosa, all of whom developed cutaneous squamous cell carcinoma. Our observations and a review of the literature suggest that squamous cell carcinoma in generalized atrophic benign epidermolysis bullosa is very infrequent and has a better outcome compared to skin cancer in recessive dystrophic epidermolysis bullosa. These differences could be explained by the distinct pathophysiology and clinical course of each of these variants of epidermolysis bullosa. In contrast to UV-induced skin cancer, the tumours in epidermolysis bullosa develop on distal extremities at sites of chronic wound healing. The cases reported here underline the exceptional importance of early histopathological assessment of suspicious skin lesions in patients with epidermolysis bullosa. Key words: epidermolysis bullosa dystrophicans Hallopeau–Siemens; generalized atrophic benign epidermolysis bullosa; skin cancer.**

(Accepted April 3, 2001.)

Acta Derm Venereol 2001; 81: 189–192

F. Weber, Department of Dermatology and Venereology, University of Innsbruck, Anichstraße 35, A-6020 Innsbruck, Austria. E-mail: florian.weber@uibk.ac.at

Epidermolysis bullosa (EB) comprises a heterogeneous group of genetically determined disorders in which minor trauma leads to blister formation on the skin and mucous membranes (1). Recessive dystrophic EB Hallopeau–Siemens (RDEB-HS) is one of the most severe forms of EB, with blister formation below the lamina densa due to mutations in the gene of type VII collagen resulting in lack of, or abnormal, anchoring fibrils (2). It is characterized by chronic mucocutaneous erosions/ulcers and atrophic scarring, resulting in pseudosyndactyly, scarring alopecia, symblepharon, dysphagia due to oesophageal strictures, loss of nails and teeth and formation of multiple milia. Chronic wound healing and inflammation cause hypochromic anaemia and growth retardation. RDEB-HS is associated with profound morbidity requiring intensive medical care throughout life. Life expectancy is reduced in patients with RDEB-HS, with a substantial cumulative risk of death in late adolescence (3).

Generalized atrophic benign EB (GABEB), which has recently also been termed junctional EB non-Herlitz (4), is a less severe but still disabling autosomal recessive type of EB. Mucocutaneous blisters arise due to cleavage in the lamina lucida and heal without scarring but often result in notable atrophy. Atrophic alopecia, dental abnormalities and nail dystrophy are characteristic clinical features (5). In addition,

some patients have large melanocytic naevi at sites of prior blistering (6). There is a tendency towards spontaneous improvement in symptoms in adulthood. As most patients live to adulthood, GABEB has a more favourable prognosis than RDEB-HS.

Chronic inflammation and tissue repair are thought to be responsible for tissue alterations which allow tumour formation from pre-existing transformed cells (7). Tumours arising under such conditions are most commonly squamous cell carcinomas (SCCs) and have been described as a complication of chronic infections (e.g. lupus vulgaris, Hansen's disease, gummatous syphilis and chronic osteomyelitis), chronic ulcerations (e.g. venous stasis, decubitus ulcers), burn scars and, of particular relevance to this article, EB (8). Under these conditions, and also in EB, these carcinomas tend to exhibit very aggressive growth and lead to high mortality rates within this patient group (1, 3).

We report herein on our experience with four patients with EB – one suffering from GABEB and three from RDEB-HS – all of whom developed SCC during the course of the disease.

## CASE REPORTS

### *Patient suffering from junctional EB*

*Case 1.* This male patient was born in 1939 with a chronic blistering disorder. He is the oldest son of consanguineous parents (cousins); three of eight surviving siblings are affected by the same condition [see Hintner & Wolff (9)]. In both the patient and the affected siblings, the diagnosis of GABEB was established by histopathology, electron microscopy and immunofluorescence (absence of the 180 kD bullous pemphigoid antigen, i.e. type XVII collagen). Genetic studies later revealed a 4003delTC mutation of the type XVII collagen gene (5, 10).

Blistering of the skin occurred continuously throughout his life, with predilection for the hands, feet, knees and elbows. There was a clear spontaneous decrease in disease activity after childhood. In the chronically affected areas, the skin was atrophic and reddish and hair follicles were absent. During childhood, blisters had also developed in the oral mucosa. Atrophic alopecia developed after the age of 20 years; eyelashes, eyebrows and beard were sparse, and pubic and axillary hair had never developed. Nails were partially absent and the remaining nails were dystrophic. On the right aspect of the trunk, two large shagreen-like EB naevi were present.

At the age of 58 years, a verrucous exophytic tumour was noticed on the back of the left foot. Histopathology revealed a well-differentiated SCC. The entire lesion was excised and the defect closed with a split skin graft. No regional or distant metastases were detected either then or during the follow-up period.

### *Patients suffering from dystrophic EB*

*Case 2.* A 26-year-old female patient without a family history of bullous disorders exhibited persistent generalized mucocutaneous blistering with subsequent scarring since birth. Owing to severe and early dental caries, dysphagia allowing only a liquid diet, chronic

constipation, dilatative cardiomyopathy and recurring skin and airway infections the patient showed severe growth retardation (height: 115 cm; body weight: 16 kg). Her hands and feet exhibited pseudosyndactyly with complete loss of nails and formation of multiple milia. Furthermore, the patient developed symblephara of both eyes, scarring alopecia of the scalp with massive crusting, chronic hypochromic, microcytic anaemia requiring multiple blood transfusions, thrombocytosis of up to 800,000/ $\mu$ l and leukocytosis of about 14,000/ $\mu$ l. The clinical course and histopathologic features, including immunofluorescent antigen mapping, were diagnostic for RDEB-HS. Systemic therapy with phenytoin, vitamin E and etretinate had failed to show objective improvement.

In 1998, the patient presented with a rapidly growing exophytic tumour of the left sole measuring 6 cm in diameter (Fig. 1), accompanied by large firm subcutaneous masses of the left femoro-inguinal region (Fig. 2). Histology revealed a moderately differentiated SCC with inguinal lymph node metastases. No further metastases were detected by sonographic or radiologic examinations.

As the patient and her parents refused any surgical intervention, radiotherapy (60 Gy) was performed to the left foot, left groin and left thigh. Despite an initial reduction in tumour mass, the tumour resumed growth later during therapy. Seven months later the patient died of weight loss and heart failure.

*Case 3.* A 33-year-old woman had developed severe persistent bullous eruptions of the skin and oral mucosa soon after birth. In her family one of her two brothers suffered from the same disorder. Owing to scarring with milia formation, pseudosyndactyly, complete loss of nails and scarring alopecia, the diagnosis of RDEB-HS was made and confirmed by electron microscopy (dermal cleavage and rarefication of anchoring fibrils). In the course of the disease the patient suffered from dysphagia due to oesophageal strictures, scarring of genital skin and mucosa with contraction of the introitus vaginae, chronic erosive keratitis of both eyes with pannus formation, growth retardation

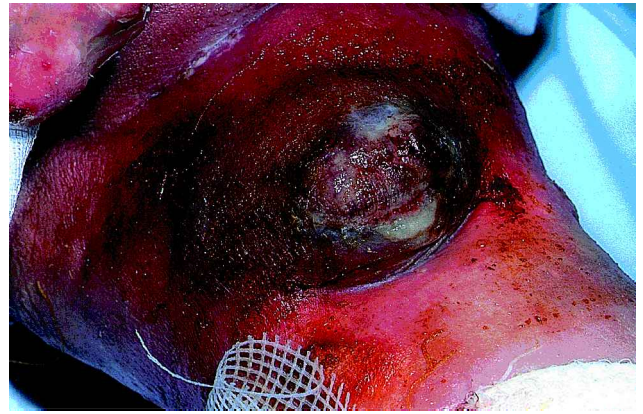

Fig. 2. Metastatic tumour tissue on the left proximal thigh of patient 2 at the time of presentation with the primary tumour.

(height: 144 cm; body weight: 32 kg) and persistent anaemia, with haemoglobin levels varying between 6 and 9 g/dl.

At the age of 33 years the patient was admitted to hospital because of a hypertrophic granulomatous lesion in scar tissue of the right prepatellar region (Fig. 3) which had developed after a trauma a few months earlier. Biopsy revealed a well-differentiated SCC and the tumour was surgically removed. After biopsy, multiple lymph nodes of the right inguinal region were found to be enlarged, suspicious for reactive lymphadenopathy or metastatic disease. In order to differentiate between an inflammatory process alone, as often occurs in patients with EB, and an additional lymph node metastasis a sentinel lymph node biopsy was performed. Histopathology of the lymph node

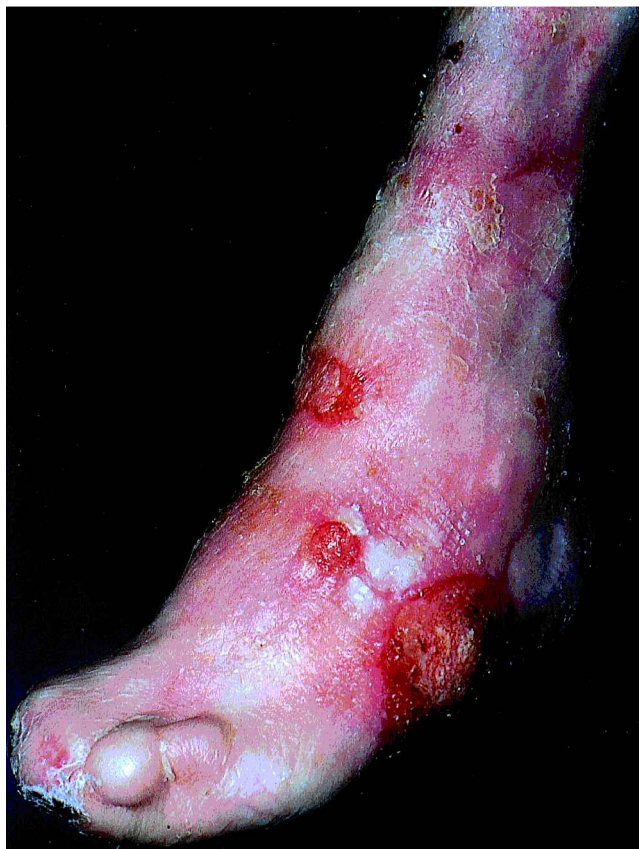

Fig. 1. Exophytic tumour on the left foot of patient 2. Histopathology revealed a squamous cell carcinoma.

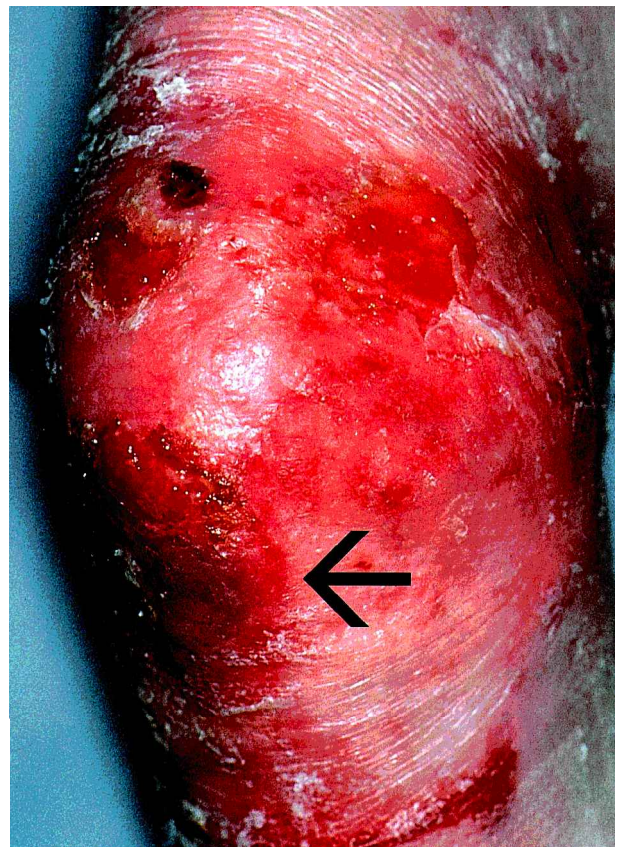


Fig. 3. The non-healing erosive area prepatellar on the right knee of patient 3 developed hypertrophic granulations (arrow) with the histopathology of a differentiated squamous cell carcinoma.

revealed only inflammation without metastatic tumour cells. During follow-up, the enlarged lymph nodes regressed spontaneously and there were no signs of a metastatic process.

*Case 4.* This 28-year-old male patient is the oldest of four siblings. Since birth the patient had suffered from a chronic mucocutaneous blistering disorder which led to scarring, formation of milia within scars, pseudosyndactyly of hands and feet, scarring alopecia, complete loss of nails and teeth, microstomy, oesophageal stenosis and growth retardation. The diagnosis of RDEB-HS was made by histopathology and antigen mapping.

At the age of 26 years, the patient had developed a deep bacterial infection of the right hand. Despite vigorous antibiotic treatment and appropriate surgical measures, which finally included the amputation of the fourth and fifth fingers, wound healing was still not complete after 1 year. At this time, an exophytic verrucous tumour arose on the back of the hand within the chronic wound area which proved to be a well-differentiated SCC by histopathology. No regional or distant metastases were detected. The patient's hand had to be amputated. Further treatment was refused by the patient.

## DISCUSSION

Malignancies of the skin are a well-documented complication of EB. The most common neoplasms are SCCs and they occur most commonly in RDEB-HS; including this series, 56 patients with generalized RDEB associated with SCC have been reported, most commonly as single case reports (11–17). The National Epidermolysis Bullosa Registry (NEBR) registered 87 RDEB-HS patients with SCC and 12.6% of the RDEB-HS patients had at least one SCC at the time of first presentation to the NEBR. By the age of 25 years, 21.7% were at risk of having had at least one SCC, and the risk rose steadily to 39.6%, 53% and 76.5% by ages 30, 35 and 60 years, respectively (1).

SCCs in RDEB-HS are typically well-differentiated, but they frequently show rapid growth and metastatic spread with an overall poor prognosis (1, 3), as is common for non-actinic variants of SCC (18). In contrast to UV-induced SCCs, they are mostly located on the distal extremities (19). Sometimes more than one primary SCC is found in these patients (17).

In contrast, junctional EB is probably very rarely complicated by skin tumours: only four cases have been reported, who developed a total of eight SCCs and three keratoacanthomas (Table I) (20–22). All these patients were males and had GABEB; all SCCs were exclusively located on the distal

extremities and were well-differentiated. No lethal outcome has been reported to date.

Although it is difficult for numerous reasons to compare the biological behaviour of SCCs arising in GABEB to those in RDEB-HS, it appears that they occur less often, at a later age, predominantly in males and behave less aggressively. This may be linked to the generally milder disease severity of GABEB, with less inflammation and little scarring. Also, the disruption below the basal lamina in RDEB-HS may facilitate lymphogenic spread of tumour cell aggregates. Based on conventional histological grading schemes the prognosis of SCCs is not predictable in these patients (1). Possibly, genetic profile studies of cutaneous SCCs in the future will explain the aggressive behaviour of these tumours in RDEB-HS patients (23).

The cases reported here underscore the necessity of monitoring EB patients for the emergence of SCCs at reasonable intervals, e.g. every 3–6 months, by the same skilled examiner. Although patients with RDEB-HS are at highest risk, SCCs may also occur in other types of EB, such as GABEB. Only few cases of SCCs in GABEB are documented, but the course of the disease is likely to resemble that of non EB patients. Notably, the case presented here is, to the best of our knowledge, the first example of SCC complicating junctional EB with a documented primary defect in type XVII collagen.

Owing to the reduced longevity of patients with RDEB-HS, this severe type is less frequent in the adult population than milder types of dystrophic EB, such as dominant dystrophic EB Cockayne–Touraine, dominant dystrophic EB Pasini and localized variants of dystrophic EB. Most of these types are at increased risk of developing SCC (1) and therefore also require careful clinical surveillance.

Cutaneous ulceration and hyperkeratotic crusting are common findings in EB but should always arouse suspicion of SCC when persistent or enlarging. We therefore propose that persistent hyperkeratotic crusting, especially on distal extremities, should be detached for clinical (and later histological) assessment of the underlying skin changes.

In our three patients with RDEB-HS complicated by SCC, one patient had regional lymph node metastasis at the time of diagnosis. Another patient had reactive inflammatory lymphadenopathy without metastatic tumour cells. This case under-

Table I. Squamous cell carcinoma (SCC) in five male patients with generalized atrophic benign epidermolysis bullosa: a review of the literature

Patient No.	Age (years)	Location	Diagnosis	Differentiation	Reference
1	43	Left lower leg	Keratoacanthoma		20
		Left lower leg	Keratoacanthoma		
		Left lower leg	Keratoacanthoma		
2	45	Dorsal hand	SCC	ND	21
		Lower leg	SCC	ND	
3	39	Right calf	SCC	Well diff.	22
		Left shin	SCC	Well diff.	
4	32	Inner ankle	SCC	Well diff.	22
		Lower leg	SCC	Well diff.	
		Left calf	SCC	Well diff.	
		Right shin	SCC	Well diff.	
		Left foot	SCC	Well diff.	
5	58	Left foot	SCC	Well diff.	Present work

SCC: squamous cell carcinoma; ND = not determined; diff. = differentiated.

lines that non-metastatic lymphadenopathy can occur in EB patients with SCC and histological assessment is necessary in order to differentiate between reactive inflammatory lymph node augmentation alone or a suspected metastatic process. As SCC in RDEB-HS is known to behave aggressively, with a rather high potential for lymphogenic metastasis, sentinel lymph node dissection could be of early diagnostic, prognostic or therapeutic value. Of course, the utility of such a technique in this group of patients is unknown at present and needs to be confirmed in a larger number of patients.

## REFERENCES

1. Fine JD, Johnson LB, Suchindran C, Bauer EA, Carter M, McGuire J, et al. Cancer and inherited epidermolysis bullosa. In: Fine J, Bauer E, McGuire J, Moshell A, eds. *Epidermolysis bullosa*. Baltimore, MD: The Johns Hopkins University Press, 1999: 175–192.
2. Uitto J, Christiano AM. Molecular basis for the dystrophic forms of epidermolysis bullosa: mutations in the type VII collagen gene. *Arch Dermatol Res* 1994; 287: 16–22.
3. Fine JD, Johnson LB, Suchindran C, Bauer EA, Carter M, McGuire J, et al. Premature death and inherited epidermolysis bullosa. In: Fine J, Bauer E, McGuire J, Moshell A, eds. *Epidermolysis bullosa*. Baltimore, MD: The Johns Hopkins University Press, 1999: 207–224.
4. Fine JD, Eady RAJ, Bauer EA, Briggaman RA, Bruckner-Tudermann L, Christiano A, et al. Revised classification system for inherited epidermolysis bullosa: report of the second International Consensus Meeting on Diagnosis and Classification of Epidermolysis Bullosa. *J Am Acad Dermatol* 2000; 42: 1051–1066.
5. Darling TN, Bauer JW, Hintner H, Yancey KB. Generalized atrophic benign epidermolysis bullosa. In: James W, Cockerell C, Dzubow L, Paller A, Yancey K, eds. *Advances in dermatology*. St. Louis, MO: Mosby-Year Book, 1998: 87–120.
6. Bauer JW, Schaeppi H, Kaserer C, Hantich B, Hintner H. Large melanocytic nevi in hereditary epidermolysis bullosa. *J Am Acad Dermatol* 2001; 44: 577–584.
7. Goldberg GI, Eisen AZ, Bauer EA. Tissue stress and tumor promotion. Possible relevance to epidermolysis bullosa. *Arch Dermatol* 1988; 124: 737–741.
8. Lawrence EA. Carcinoma arising in the scars of thermal burns. *Surg Gynecol Obstet* 1952; 95: 579–588.
9. Hintner H, Wolff K. Generalized atrophic benign epidermolysis bullosa. *Arch Dermatol* 1982; 118: 375–384.
10. McGrath JA, Darling T, Gatalica B, Pohla-Gubo G, Hintner H, Christiano AM, et al. A homozygous deletion in the gene encoding the 180 kDa bullous pemphigoid antigen (BPAG2) in a family with generalized atrophic benign epidermolysis bullosa. *J Invest Dermatol* 1996; 106: 771–774.
11. McGrath JA, Schofield OMV, Mayou BJ, McKee PH, Eady RAJ. Epidermolysis bullosa complicated by squamous cell carcinoma: report of 10 cases. *J Cutan Pathol* 1992; 19: 116–123.
12. Newman C, Wagner RF Jr, Tyring SK, Spigel GT. Squamous cell carcinoma secondary to recessive dystrophic epidermolysis bullosa. A report of 4 patients with 17 primary cutaneous malignancies. *J Dermatol Surg Oncol* 1992; 18: 301–305.
13. Chorny JA, Shroyer KR, Golitz LE. Malignant melanoma and a squamous cell carcinoma in recessive dystrophic epidermolysis bullosa. *Arch Dermatol* 1993; 129: 1212.
14. Van Rengen A, Degreef H. Epidermolysis bullosa dystrophica Hallopeau-Siemens and squamous cell carcinoma: a case report. *Dermatology* 1996; 192: 418–419.
15. Bastin KT, Steeves RA, Richards MJ. Radiation therapy for squamous cell carcinoma in dystrophic epidermolysis bullosa: a case report and literature review. *Am J Clin Oncol* 1997; 20: 55–58.
16. Hosokawa K, Yoshitatsu S, Kakibuchi M, Nishimoto S, Higashiyama M, Yoshikawa K. Simultaneous manifestation of squamous cell carcinoma in identical twins with epidermolysis bullosa. *Plast Reconstr Surg* 1998; 102: 448–449.
17. Bosch RJ, Gallardo MA, Ruiz del Portal G, Sanchez P, Arce MF, Herrera E. Squamous cell carcinoma secondary to recessive dystrophic epidermolysis bullosa: report of eight tumours in four patients. *J Eur Acad Dermatol Venereol* 1999; 13: 198–204.
18. Baldursson BT, Hedblad MA, Beitner H, Lindelöf B. Squamous cell carcinoma complicating chronic venous leg ulceration: a study of the histopathology, course and survival in 25 patients. *Br J Dermatol* 1999; 140: 1148–1152.
19. Chuang TY. Skin cancer II: nonmelanoma skin cancer. In: Williams HC, Strachan DP, eds. *The challenge of dermatology*. New York: CRC Press, 1997: 209–222.
20. Pellicano R, Fabrizi G, Cerimele D. Multiple keratoacanthomas and junctional epidermolysis bullosa. *Arch Dermatol* 1990; 126: 305–306.
21. Parker SC, Schofield OMV, Black MM, Eady RAJ. Non-lethal junctional epidermolysis bullosa complicated by squamous cell carcinoma. In: Priestly GC, Tidman MJ, Weiss JB, Eady RAJ, eds. *Epidermolysis bullosa: a comprehensive review of classification, management and laboratory studies*. Berkshire, UK: Dystrophic Epidermolysis Bullosa Research Association, 1990: 103–106.
22. Swensson O, Christophers E. Generalized atrophic benign epidermolysis bullosa in 2 siblings complicated by multiple squamous cell carcinoma. *Arch Dermatol* 1998; 134: 199–203.
23. Wang T, Hopkins D, Schmidt C, Silva S, Houghton R, Tarita H, et al. Identification of genes differentially over-expressed in lung squamous cell carcinoma using combination of cDNA subtraction and microarray analysis. *Oncogene* 2000; 19: 1519–1528.