

## Systemic Therapy of Primary Cutaneous B-cell Lymphoma, Marginal Zone Type, with Rituximab, a Chimeric Anti-CD20 Monoclonal Antibody

Sir,

According to the European Organization for Research and Treatment of Cancer (EORTC) classification, the major subtypes of primary cutaneous B-cell lymphomas are follicle centre-cell lymphoma and immunocytoma/marginal zone lymphoma, both characterized by indolent behaviour and favourable prognosis in the majority of patients (1). Radiotherapy, surgery excision and intralesional interferon are the preferred treatments in patients with solitary or localized skin lesions (2). Multiagent chemotherapy alone or associated with interferon- $\alpha$  or with radiotherapy is limited to multifocal skin lesions (3).

Rituximab, a genetically engineered anti-CD20 monoclonal antibody, already approved for the treatment of non-Hodgkin's lymphomas (3, 4), has been recently used in primary cutaneous B-cell lymphoma (5).

The recent observation of a patient affected by a primary multifocal B-cell cutaneous lymphoma, marginal zone type, prompted us to use Rituximab as a single agent, with satisfactory results.

### CASE REPORT

A 38-year-old man presented a 10-year history of progressive erythematous nodules located on the back and thorax with no lymphadenopathies (Fig. 1). A total of 8 lesions, 1–5 cm in size, was counted. The patient, who had not received any previous treatment, was otherwise in good health.

Skin biopsies showed diffuse lymphocytic infiltrate with few follicular centres in the dermis sparing the subepidermal zone and reaching the subcutaneous tissue (Fig. 2a). Small lymphocytes and monocytoïd cells were the main neoplastic component. Immunohistochemical staining revealed positivity for CD20 (Fig. 2b, d) and for  $\lambda$ -immunoglobulin light chains (Fig. 2c), whereas  $\kappa$ -light chains, CD5 and CD10 were negative. A scattered CD3 positivity was also observed within and around the neoplastic infiltrate. Staging of the patient (TC total body, bone marrow biopsy, laboratory findings) showed no abnormalities and anti-*Borrelia burgdorferi* antibodies were absent.

The clinical picture, the immunohistological findings and the absence of extracutaneous localizations were indicative of a primary cutaneous B-cell lymphoma of marginal zone type. The multifocal localization

and the strong CD20 positivity prompted us to use Rituximab, as a single agent, at the dosage of 375 mg/m<sup>2</sup> once a week for 4 weeks as an intravenous infusion in 1 litre of normal saline. At the end of this schedule, the more recent 3 nodules disappeared and the other lesions were reduced in size by at least 50%. One of these persistent lesions was biopsied. A substantial reduction in the neoplastic infiltrate, mainly involving the interstitial and mantle follicular components, was observed (compare Fig. 2a with 2e). The immunohistochemical staining revealed down-regulation of CD20 antigen expression (compare Fig. 2b and 2d with 2f) and different distribution of immunoglobulin light-chain positivity. After 6 months of follow-up, clearing or partial remission of the pre-existing lesions and absence of a new relapse completed the clinical picture.

### DISCUSSION

Marginal zone B-cell lymphoma, characterized clinically by solitary or cluster erythematous papules, nodules or plaques, usually shows an indolent clinical behaviour, slow evolution and good prognosis (3).

Rituximab is a monoclonal antibody directed against the B-cell specific antigen CD20, which is a 297 amino acid phosphoprotein expressed on pro-B-cells and B-cells, and overexpressed on malignant B-cells. CD20 antigen seems to be involved in B-cell differentiation and proliferation (6). This antibody, binding with high affinity to CD20 antigen, mediates complement-dependent cell lysis and antibody-dependent cellular cytotoxicity. It has also been shown to sensitize chemoresistant human lymphoma cell lines and to induce apoptosis *in vitro* (7). In most patients, this treatment is well tolerated without serious systemic adverse effects. Temporary peripheral blood B-cell depletion may occur, but it has not been associated with immunodeficiency or significant changes in immunoglobulin G levels (8). Recent data demonstrate complete or more often partial remission in half of the patients with systemic relapsed low-grade lymphomas. The follow-up showed a median remission of about 1 year (9).

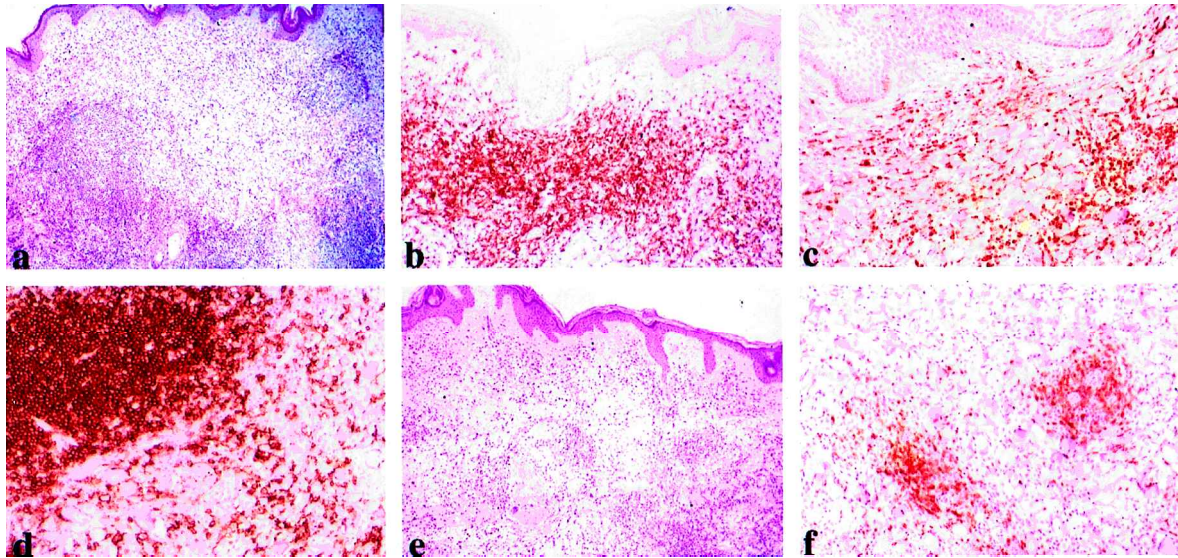
We used Rituximab as a first-choice agent for the treatment of a disseminated cutaneous marginal zone lymphoma with no additional chemotherapy, and observed a good therapeutic response and no significant side-effects. Furthermore, we observed the downregulation of CD20 antigen on neoplastic cells at the end of therapy. The loss of CD20 expression is a phenomenon already reported in the literature, which seems to occur only rarely (10) and may decrease the efficacy of this treatment. However, Treon et al. reported that interferon- $\gamma$  at pharmacologically achievable concentrations induced CD20 expression on B-lymphocytes (11). It will be interesting to observe the clinical response to an interferon- $\gamma$ /Rituximab combined treatment in patients with CD20<sup>+</sup> lymphoproliferative diseases.

### REFERENCES

1. Willemze R, Kerl H, Berti E, Cerroni L, Diaz-Peréz JL, et al. EORTC classification for primary cutaneous lymphomas: a proposal from the cutaneous lymphoma study group of the European Organization for Research and Treatment of Cancer. *Blood* 1997; 90: 354–371.

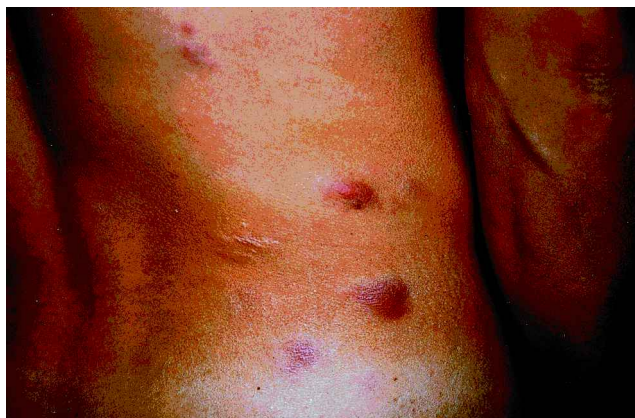

Fig. 1. Multiple erythematous nodules are evident on the back.



**Fig. 2.** Histology and immunohistochemical study. (a) Diffuse lymphocytic infiltrate of the dermis sparing the subepidermal border with some follicular structures (H&E; original magnification  $\times 125$ ). (b) Strong positivity on immunostaining for CD20 of the infiltrating cells in the upper dermis ( $\times 160$ ). (c) Positivity on immunostaining of  $\lambda$ -immunoglobulin light chains ( $\times 160$ ). (d) Strong positivity at immunostaining for CD20 in the deep dermis ( $\times 160$ ). (e) Evident reduction in neoplastic infiltrate after anti-CD20 treatment (H&E;  $\times 125$ ). (f) Down-regulation of CD20 expression after anti-CD20 treatment ( $\times 160$ ).

- Cerroni L, Peris K, Torlone G, Chimenti S. Use of recombinant interferon  $\alpha$ -2a in the treatment of cutaneous lymphoma of T and B lineage. In: Lambert WC, Giannotti B, van Vloten WA, eds. Basic mechanisms of physiologic and aberrant lymphoproliferation in the skin. New York: Plenum Press, 1994: 545–551.
- Bennenk MW, Vermeer MH, Geerts ML, Noordijk EM, Heule F, van Voorst Vader PC, et al. Treatment of multifocal primary cutaneous B-cell lymphoma: a clinical follow-up study of 29 patients. *J Clin Oncol* 1999; 17: 2471–2478.
- Peterson BA. Current treatment of follicular low-grade lymphomas. *Semin Oncol* 1999; 26 Suppl 14: 2–11.
- Sabroe RA, Child FJ, Woolford AJ, Spittle MF, Russel-Jones R. Rituximab in cutaneous B cell lymphoma: a report of two cases. *Br J Dermatol* 2000; 143: 157–161.
- Maloney DG. Preclinical and phase I and II trials of rituximab. *Semin Oncol* 1999; 26 Suppl 14: 74–78.
- Grillo-Lopez AJ, White CA, Varns C, Shen D, Wei A, McClure A, et al. Overview of the clinical development of rituximab: first monoclonal antibody approved for the treatment of lymphoma. *Semin Oncol* 1999; 26 Suppl 14: 66–73.
- Maloney DG, Grillo-Lopez AJ, White CA, Bodkin D, Schilder RJ, Neidhart JA, et al. Idec-C2B8 (rituximab) anti CD20 monoclonal antibody therapy in patients with relapsed low-grade non-Hodgkin's lymphoma. *Blood* 1997; 90: 2188–2195.
- McLaughlin P, Grillo-Lopez AJ, Link BK, Levy R, Czuczman MS, Williams ME, et al. Rituximab chimeric anti-CD20 monoclonal antibody therapy for relapsed indolent lymphoma: half of patients respond to a four dose treatment program. *J Clin Oncol* 1998; 16: 2825–2833.
- Davis TA, Czerwinski DK, Levy R. Therapy of B-cell lymphoma with anti CD20 antibodies can result in the loss of CD20 antigen expression. *Cancer* 1999; 5: 611–615.
- Treon SP, Shima Y, Preffer FI, Doss DS, Ellman L, Schlossman RL, et al. Treatment of plasma cell dyscrasias by antibody-mediated immunotherapy. *Semin Oncol* 1999; 26 Suppl 14: 97–106.

Accepted March 2, 2001.

R. Soda<sup>1</sup>, A. Costanzo<sup>1</sup>, M. Cantonetti<sup>2</sup>, A. Orlandi<sup>3</sup>, L. Bianchi<sup>1</sup> and S. Chimenti<sup>1\*</sup>  
 Departments of <sup>1</sup>Dermatology, <sup>2</sup>Haematology and <sup>3</sup>Anatomic Pathology, University of Rome "Tor Vergata", Viale dell'Umanesimo 10, 00144 Roma, Italy. \*E-mail: chimenti@uniroma2.it