Acta Derm Venereol 2002; 82: 329–334

Taylor & Francis healthsciences

INVESTIGATIVE REPORT

Loss of Hyaluronan in the Basement Membrane Zone of the Skin Correlates to the Degree of Stiff Hands in Diabetic Patients

ULF BERTHEIM[1], ANNA ENGSTRÖM-LAURENT[3], PER-ÅKE HOFER[4], PETER HALLGREN[5], JOHAN ASPLUND[5] and STEN HELLSTRÖM[2]

Departments of [1]Plastic Surgery, [2]Otorhinolaryngology, [3]Internal Medicine and [4]Dermatology, Venereology and Pathology, University Hospital of Umeå, Umeå, and [5]Department of Internal Medicine, Central Hospital, Falun, Sweden

Glycosaminoglycans are important components of all extracellular matrices. One of the glycosaminoglycans is hyaluronan, which is ubiquitously distributed throughout the connective tissue. Hyaluronan is especially abundant in the skin, in which it is of both structural and functional importance. This study describes the localization and distribution of hyaluronan in the skin of healthy individuals and of 23 patients with insulin-dependent diabetes mellitus and various degrees of limited joint mobility. In normal skin, hyaluronan staining was seen in all layers but most prominently in the papillary dermis and the basement membrane zone. In the skin from diabetic patients with normal or only moderately restricted mobility of the hands (limited joint mobility grades 0 and 1), the distribution of hyaluronan was similar to that of normal skin. In the skin of patients with severe restriction in joint mobility (limited joint mobility grade 2) the staining pattern was significantly different with weak hyaluronan staining in the papillary dermis and the basement membrane zone almost devoid of hyaluronan. Moreover, an increased epidermal thickness in the latter patients was evident as well as a pronounced hyaluronan staining compared with normal epidermis. ***Key words: diabetes; hyaluronan; skin; limited joint mobility.***

(Accepted May 13, 2002.)

Acta Derm Venereol 2002; 82: 329–334.

Anna Engström-Laurent, Department of Internal Medicine, University of Umeå, SE-901 85 Umeå, Sweden. E-mail: anna.engstrom-laurent@medicin.umu.se

In patients with insulin-dependent diabetes mellitus (IDDM) as well as in non-insulin-dependent diabetes mellitus (NIDDM), stiffening of the periarticular connective tissues in the hand, including the skin, is a well-known feature giving rise to limited joint mobility (LJM) (1). It has also been reported that LJM is associated with an increased risk of other complications such as nephropathy and retinopathy (2). The pathogenesis of such stiffening of the connective tissues is not clearly elucidated but structural and biochemical changes in the composition of the connective tissues are probably of major importance.

Normal skin matrix is composed of a mixture of collagen and other proteins such as elastin and different glycosaminoglycans. When skin pathology is discussed, attention is focused particularly on collagens and elastin (3–5). Also important for skin structure and integrity are the various glycosaminoglycans, which have attracted less attention except in studies of heparan sulphate and its expression in both the skin (6) and the kidney (7) in patients with diabetes. Hyaluronan (hyaluronic acid, HYA) is the major glycosaminoglycan of the skin (3, 8) and is synthesized in large quantities by the dermal fibroblasts. HYA is a high molecular weight polysaccharide formed by repeating units of glucuronic acid and glucosamine residues. HYA has several important cell biological functions affecting, for example, cell differentiation, cell migration and cell recognition. The molecule also has pronounced physicochemical properties, such as regulation of water homeostasis in the tissues, serving as a barrier and a sieve, all of which are important for the maintenance and integrity of the tissues (8). HYA also contributes to the elasticity and the shearing properties of the skin. Furthermore, HYA is an essential component in wound healing and the scar remodelling process of the skin (9, 10).

In normal skin, HYA is shown to occur in both the epidermis and the dermis, being mainly accumulated in the papillary dermis (11, 10). The distribution of HYA in skin diseases is less well characterized, with the exception of psoriasis (11, 12).

The purpose of the present study was to localize HYA in the skin of diabetic patients with varying degrees of limited joint mobility in order to investigate whether there were any differences in the occurrence and distribution of this macromolecule between diabetic patients and healthy persons. In view of the functional and structural properties of HYA, it is conceivable that an altered content and localization of HYA could contribute to the pathology observed in the skin in these patients (5). Moreover, changes in HYA distribution in the skin may correspond to similar changes in other extracellular matrices, e.g. in vessels and kidneys.

MATERIAL AND METHODS

Patients and controls

In 23 patients with IDDM, a 5 mm skin biopsy was punched from the dorsum of the hand, 4 cm distal to the ulnar head. In

© 2002 Taylor & Francis. ISSN 0001-5555

6 of these patients, representing LJM grade 0 ($n = 3$) and LJM grade 2 ($n = 3$), a second biopsy was taken for determination of the total HYA concentration. From 6 healthy subjects (2 males and 4 females, age range 35–50 years) 2 biopsies were obtained, one for histological localization and one for quantitative analysis of HYA. One of the specimens was lost during the histological procedure and only 5 could be evaluated according to histological localization and epidermal thickness. Of the 23 patients with diabetes, ranging in age from 20 to 57 years, 13 had varying degrees of joint limitations. The numbers of patients in the various LJM groups were as follows: grade 0 ($n = 10$), grade 1 ($n = 7$) and grade 2 ($n = 6$). All the patients were biopsied during the month of November and December, thus minimizing the time for sun exposure. On clinical examination of the patients' hands and skin, no signs of cutaneous inflammation were observed.

Limited joint mobility (LJM)

The patient's mobility in the wrist and finger joints was tested and assessed according to a modified scale described by Rosenbloom et al. in 1981 (1). This test has been used in a number of other studies and is easy to perform and standardize. In brief, each subject was asked to approximate the palmar surfaces of the interphalangeal joints of both hands, with the fingers splayed. If such an approximation is incomplete, the examiner confirms the limitation by passively extending the patient's fingers. Normal extension should be 180° or more at the proximal interphalangeal joints. The distal interphalangeal joints are often affected as well. According to the number of interphalangeal joint contractures, the subjects are graded as follows: *stage 0*, no limitation; *stage 1*, one interphalangeal joint is involved in both hands; *stage 2*, 2 or more interphalangeal joints are involved, with or without one large joint involvement.

The clinical examinations of the joints were performed by the same observer (JA) prior to taking the skin punch biopsies. Laboratory tests included determination of glycosylated haemoglobin (HbA_{1c}) and urine–albumin.

Fixation, embedding and staining

After the skin punch biopsies were taken, the tissue specimens were transferred to saline, and within 30 min fixed in a solution containing 2% formaldehyde and 0.5% glutaraldehyde in 0.1 M phosphate-buffered saline (PBS). Fixation was performed under microwave irradiation according to a modified technique for localization of HYA (13). The specimens were irradiated at 700 W up to 45°C and then transferred to PBS and kept at cold storage temperature until further processing for embedding. The samples were dehydrated in upgraded series of ethanol to xylene and embedded in paraffin wax. Serial paraffin sections (5 μm) were cut and collected on albumin-coated slides and allowed to dry at room temperature. After deparaffinization, the tissue sections were washed in PBS and then incubated with a fresh solution of 3% H_2O_2 in methanol for 5 min at room temperature, to destroy any endogenous peroxidase activity. After 2 washes in PBS, the slides were incubated with 1.0% bovine serum albumin for 30 min at room temperature, to block non-specific binding sites. The slides were then washed twice with PBS for 10 min and incubated with approximately 100 μl of biotinylated hyaluronan binding protein (HABP), at a dilution of 1:40, overnight, at 4°C storage temperature. After the washings in PBS, twice for 10 min, the slides were incubated with the Vectastain-Elite avidin-biotin complex (ABC reagent, Vector Laboratories, Burlingame, CA, USA) at a dilution of 1:200, for 40 min at room temperature. After three washes in PBS for 10 min each, the sections were incubated for 5 min in 0.1% diaminobenzidine tetrahydrochloride (Sigma Co., St Louis, Mo, USA) and 0.03% H_2O_2 in 0.05 M TRIS-HCl buffer, pH 7.6, at room temperature, which produced a water-insoluble brown precipitate. Finally, the slides were washed in tap water for 5 min and cover slipped. For controls, sections were incubated with 50 units/ml *Streptomyces hyaluronidase* (Sigma Co., St Louis, Mo, USA) for 4 h at 37°C prior to the incubation with biotinylated HABP. This hyaluronidase specifically degrades HYA and therefore served as a control to demonstrate the specificity of the method. The sections were examined and photodocumented using a Zeiss Axiophot photomicroscope.

To evaluate the histological appearance of the skin collagen, a van Gieson staining of the biopsy material was undertaken.

Isolation and biotin labelling of the hyaluronan-binding protein (HABP)

The isolation and biotin labelling of the HABP has been described in detail elsewhere (14). Briefly, a mixture of proteins, having affinity for the HYA-binding region of the chondroitin sulphate proteoglycan and the link proteins, was isolated from bovine nasal cartilage and purified by affinity chromatography. The purified HYA-binding region was then linked to biotin and stored at −20°C until used.

Evaluation of HYA-staining intensity

Each section was examined separately under the light microscope at an objective magnification of ×10 and ×40. The staining intensities of stratum corneum, stratum granulosum, stratum spinosum, stratum basale, the papillary dermis and the reticular dermis were evaluated as: 0 = absent, 1 = weak, 2 = moderate and 3 = strong. In this way, the staining intensities of the different layers were compared only within the same section. For an overall comparison of staining intensities in the different groups, a mean value was calculated. The mean value of the reticular dermis in controls was 1.8 and in LJM-2 patients 1.5. The overall HYA staining pattern in the healthy controls was graded as normal (N). In the diabetic patients, the histology was graded 0 when the HYA staining was similar to that of the healthy controls, except for a weaker staining in the papillary dermis. When the papillary dermis corresponding to the basement membrane zone showed a patchy and irregular HYA staining, the histology was graded as 1. When there was almost no HYA staining in the area corresponding to the basement membrane zone, the histology pattern was graded as 2. The evaluation was performed on blinded slides by 2 examiners separately: one of the authors (UB) and a technician (A-L G). When the results obtained were compared, there was a close correlation between the findings of the 2 examiners.

Quantitative analysis of skin HYA

The skin samples were collected in pre-weighed tubes and weighed. The weighed tissue was digested with pronase (Protease P-5005 SIGMA 5 units/2 ml buffer 0.05 M TRIS-HCL-0.01 m $CaCl_2$, pH 7.2) for 18 h at 55°C. The digests were kept in a bath of boiling water for 10 min and then stored frozen at −80°C. Before analyses, 0.1 ml 0.2 M phenylmethylsulphonyl fluoride (PMSF) (Sigma) in 99% ethanol was added to inhibit the remaining enzyme activity. The solution was centrifuged for 10 min (approximately 2,000 rpm) and 2 ml of the supernatant was applied to a 10 ml Sephadex G-25 column (PD-10, Pharmacia Fine Chemicals, Uppsala, Sweden) followed by PBS. The first 3 ml of the eluate was discarded and the subsequent 4 ml was saved for analysis of the HYA content, according to the method described by Laurent & Tengblad (15). The method utilizes purified HABP extracted from nasal bovine cartilage. The HABP is used as an antibody in an RIA-like type of assay.

Measurements of the epidermal thickness

Measurements were taken on photomicrographs, at a magnification of ×400, of tissue sections from all ($n = 23$) biopsies from patients with diabetes mellitus and from 5 healthy controls. The measurements concerned the thickness of the epidermis and were performed using grid transparencies, which were overlaid on the photomicrographs (16). The height of the epidermis was measured from the basement zone to the border between stratum granulosum and stratum corneum in equidistant lines running perpendicular to the surface of the epidermis.

Statistical methods

An unpaired t-test was used for calculations of differences between the groups regarding age, duration of disease, HbA1c and microalbuminuria. A non-parametric test, the Mann–Whitney U-test, was used to calculate correlation in epidermal thickness to the histological grading of the HABP staining.

RESULTS

Limited joint mobility (LJM) grades and grading of the hyaluronan (HYA) staining pattern

A good correlation was found between the clinical LJM grades and the histological grading in the diabetic patients. The correlation between LJM status, histological grading and epidermal thickness is shown in Table I.

On evaluating the HYA staining intensity, the most obvious difference was seen in the papillary dermis and the reticular dermis when comparing controls ($n = 5$) and diabetic patients with LJM grade 2 ($n = 6$). The mean value in the papillary dermis in controls was 3.0 and in LJM grade 2 patients 1.6.

Van Gieson staining

The dermal collagen organization was normal in healthy skin and the skin from patients with diabetes with various degrees of LJM. No inflammatory cells were observed in either the normal specimens or the diabetics (Figs 1*a* and *b*).

HYA in normal skin

The most intense HYA staining was observed in the papillary dermis. In this region, HYA was present in a dense layer directly below the epidermis, with the most pronounced staining in the basement membrane zone. The HYA staining of the papillary layer had a homogeneous appearance, whereas the HYA staining in the reticular dermis was spread in an irregular, mesh-like pattern. HYA staining was also seen in the keratinocytes in the spinous layer of the epidermis. There was also staining in the superficial part of the specimen, interpreted as the granular layer (Fig. 2*a* and Table I).

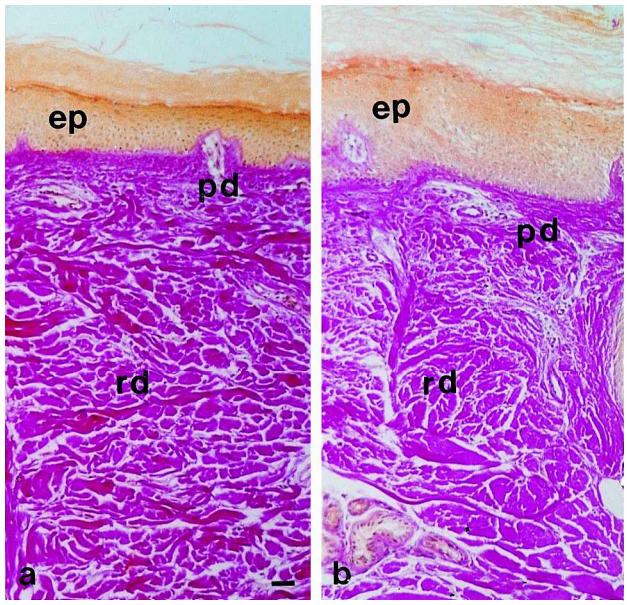

Fig. 1. Light micrographs of histological sections from (*a*) normal skin and (*b*) skin from a patient with diabetes with limited joint mobility grade 2 status. The sections are stained with the van Gieson solution. No clear-cut difference is demonstrated between these sections concerning distribution of collagen but the epidermis of diabetic skin is thicker than the epidermis of normal skin. Scale bar = 40 μm. ep: epidermis; pd: papillary dermis; rd: reticular dermis.

HYA in diabetic skin from patients with LJM grade 0

In 5 patients the distribution of HYA resembled that of normal skin, except that the dense HYA layer of the papillary dermis was thinner. The most intense HYA staining band corresponded to the basement membrane zone. In the remaining 5 patients with LJM grade 0, the

Table I. *Correlation between the limited joint mobility (LJM) status, hyaluronan (HYA) histological grading and epidermal thickness*

			HYA histological grading			
			0	1	2	
LJM (grades)	Mean age (years)	Sex (F/M)	(n)			Epidermal thickness (μm)
Controls	49.8	2/3	5	0	0	62.6 ± 14.0
0	38.7	0/10	5	5	0	78.8 ± 23.3
1	35.9	1/6	2	2	3	88.3 ± 32.99
2	41.5	3/3	0	1	5	94.2 ± 31.85

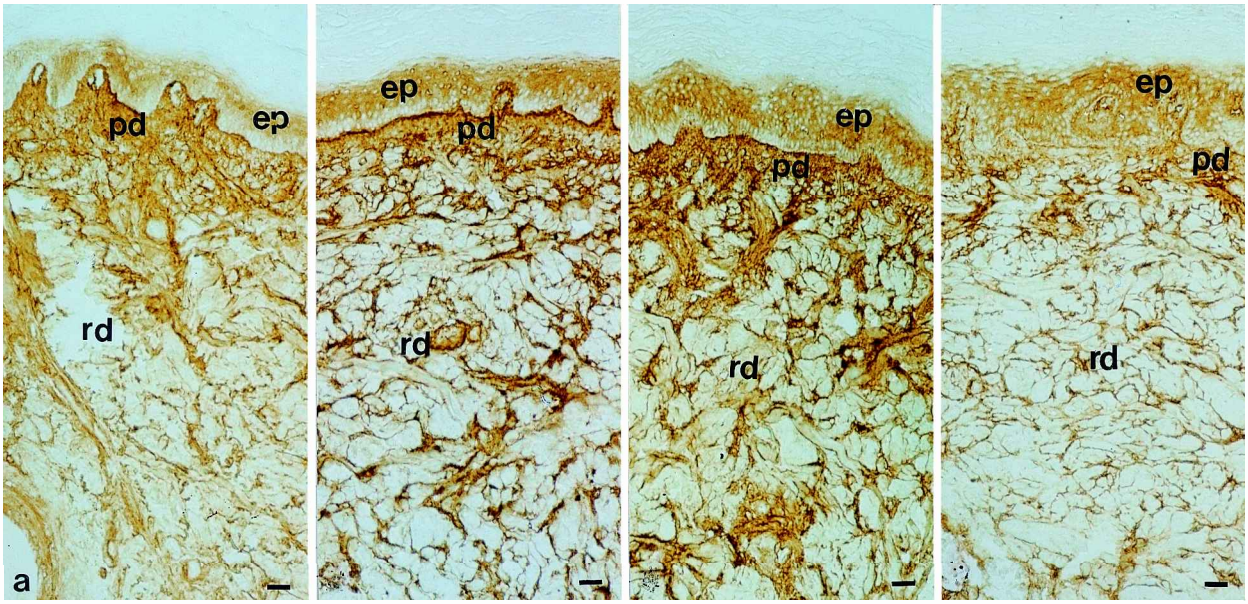

Fig. 2. (*a*) Normal skin tissue from a healthy individual. The most intense hyaluronan (HYA) staining is observed in the papillary dermis (pd). The epidermis (ep) demonstrates a weak HYA staining pattern. In the basement membrane zone (BMZ) a homogeneous and intense staining of HYA is observed. (*b*) Skin from a patient with diabetes and limited joint mobility (LJM) grade 0. The distribution of HYA resembles that of the normal skin except that the dense HYA layer of the papillary dermis is thinner and appears as a pronounced band, which correlates to the BMZ. (*c*) Skin from a patient with diabetes and LJM grade 1. The HYA staining of the pd is weaker than that of normal skin and the HYA staining of the ep is stronger. (*d*) Skin from a patient with diabetes and LJM grade 2. Note that the pd, including the BMZ, is almost devoid of HYA staining. The HYA staining of the thickened epidermis is more pronounced than that in normal skin but resembles that in diabetic skin of LJM grades 0 and 1. Scale bar = 40 μm. rd: reticular dermis.

appearance of HYA was patchy in some of the papillae and the histological pattern was graded as 1 (Fig. 2*b* and Table I).

HYA in the diabetic skin of patients with LJM grade 1

This group showed the most heterogeneous HYA staining pattern. In 2 of these patients the papillary dermis had a less dense HYA layer compared with normal skin and was graded as 0. In 2 patients some of the papillae had a patchy appearance of the HYA staining and this corresponded to histological grading 1. Three of the patients with LJM grade 1 had HYA staining patterns with weak staining in the papillary layer and the basement membrane zone was almost devoid of HYA. This corresponded to histology grade 2 (Fig. 2*c* and Table I).

HYA in diabetic skin from patients with LJM grade 2

The papillary layer in the skin of all but one of the patients with LJM grade 2 showed weak HYA staining. The basement membrane was almost devoid of HYA staining and histology grading was 2. One patient with LJM grade 2 had an HYA staining pattern that was graded 1. In the thickened epidermis the HYA staining pattern was more intense compared with normal skin but resembled the staining intensity of diabetic skin from patients with LJM grades 0 and 1 (Fig. 2*d* and Table I).

Miscellaneous

The skin sections digested with *Streptomyces hyaluronidase* prior to the HABP probe did not show any HYA staining.

Measurements of epidermal thickness. A weak statistical difference ($p = 0.126$) was observed between controls and patients with LJM grade 2 regarding epidermal thickness. When comparing epidermal thickness with HYA histology grading, a statistical correlation was observed ($p = 0.021$) (Fig. 3).

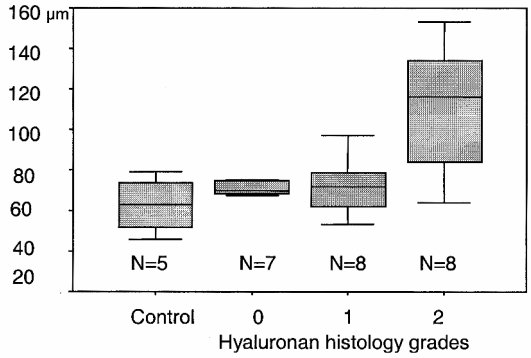

Fig. 3. Box-plot graph showing the epidermal thickness compared to the HYA histology grades in patients and controls. The horizontal bar in the box indicates the mean value of the skin thickness in each group.

Quantitative analysis. In 6 of the 23 diabetic patients a second skin biopsy was obtained for quantitative analysis of HYA. The HYA concentrations varied between 1,232 and 3,555 μg/g (mean value: 1,924 μg/g) in the skin biopsies of the 6 diabetics. In the 6 healthy individuals the HYA concentrations varied between 1,388 and 2,090 μg/g (mean value: 1,568 μg/g). There was no significant difference between the groups.

Laboratory findings. Patients with LJM grade 2 had significantly higher ($p < 0.05$) HbA1c levels compared with those of the other groups. There were no significant differences between LJM grades with respect to microalbuminuria, duration of disease or the age of the patients.

DISCUSSION

A variety of manifestations of diabetes mellitus involve the skin (5, 17). Stiffness of the hands, first described in a severe form by Lundbæk in 1957 (17), is today acknowledged as a common characteristic of diabetes. This periarticular stiffness, giving rise to limited joint mobility of the hands, is associated with the early microvascular disease that affects patient with diabetes (1, 2). This relationship between LJM and vascular changes has contributed to the belief that similar changes occur in the vessels of other connective tissues, such as the skin (1, 6, 18, 19).

The present study shows that the histological distribution of HYA, a major connective tissue component in the skin, is clearly different in healthy individuals compared with patients with diabetes type 1 with advanced degrees of LJM. The LJM status was graded as 0, 1 or 2, a scale on which grade 2 is related to the more severe forms of limited joint mobility (19). Histological grading of HYA staining pattern was also graded as 0, 1 or 2. The correlation between the severity of the limited joint mobility and the HYA staining pattern was fairly good. The changes in HYA distribution were most pronounced in the diabetic patients with LJM grade 2 and observed in the papillary layer of the dermis, mainly in the area at the epidermal–dermal junction in the basement membrane zone and in the spinous layer. These changes included a reduced HYA staining of the papillary dermis together with a distinct disintegration of the HYA-enriched basement membrane zone. In the patients with LJM grade 2, the histology pattern also gave the impression of a thickened epidermis with a more pronounced staining intensity compared with that in normal skin. When measurements were performed it was shown that the epidermis in skin biopsies with an HYA histological grading of 2 was indeed thicker than that in normal skin. It can be speculated whether this increase in thickness is caused by HYA leaking out into the epidermis from deeper layers, not only filling up the space but also attracting water.

It is less likely that the changes observed in histology appearance in the diabetic skin should be a consequence of a loss of HYA due to processing of the material. All the biopsies from controls and patients were taken by the same person and from intact skin and with the same type of equipment. The clinical impression in all the patients, especially the LJM grade 2 patients, was that the skin was tighter and firmer but with no obvious oedema. There were no difficulties in obtaining the biopsies and no excess bleeding was observed in the patients.

However, when the total amount of HYA in the biopsies was analysed, no significant differences were observed between the patients with diabetes and the healthy individuals. The most probable explanation for the similar values on total amount of HYA in controls and patients is the fact that HYA is not homogeneously distributed in the deeper layers of the skin and the total HYA concentration in a skin biopsy can vary from specimen to specimen. The method used for quantitative analysis of HYA in a full skin biopsy will not detect local changes in the basal membrane zone or in the superficial layers of the epidermis. Thus, a comparison between the histological appearance of HYA in various parts of the skin and analysis of the total amount of HYA in full skin biopsies is not informative.

Disturbed wound healing is another skin complication of diabetes and a high local content of HYA has been suggested to play an important role in early wound healing (20–22). In clinical use, exogenously administered HYA accelerates wound healing and also reduces scarring (20, 21, 23). As early as 1983, Abatangelo et al. (20) reported on the beneficial healing effects in HYA-enriched wounds in diabetic rats. He also claimed that insulin appears to have a direct stimulating effect on HYA production by fibroblasts (20). In the present study it was shown that areas of the skin that are normally rich in HYA, were almost devoid of this substance in diabetics. As HYA is attributed with regulatory functions such as mitosis, cell migration, angiogenesis, immune reactions and phagocytosis (24), all of which are functions that are important for maintenance of the skin integrity, a change in HYA content and localization could give rise to skin pathology, e.g. impaired wound healing. Furthermore, the physicochemical properties of HYA affecting water homeostasis and friction-reducing functions could thus be disturbed in diabetic patients, attributing to the stiffness of the skin.

The clinical variables studied included patient's age, disease duration, glycosylated haemoglobin (HbA_{1C}) and microalbuminuria. A weak correlation was seen between HbA_{1C} and LJM grade 2 but none of the other clinical variables showed any significant correlation to the LJM grades. This must, however, be viewed in regard to the limited number of patients investigated in the present study. However, this study indicates that

biopsies of the skin must be regarded as an easy and accessible way to study changes in the composition of the basal membrane zone and to relate these changes to the pathological processes in diabetes mellitus.

To summarize, the pronounced changes in HYA distribution that were observed in the skin mainly from diabetic patients with LJM grade 2 occurred both in the epidermis and in the papillary dermis. These changes included a reduced HYA staining of the papillary dermis together with a distinct disintegration of the HYA-rich basement membrane zone. In the thickened epidermis, a stronger HYA staining was observed in the spinous layer. The thickening of the epidermis was confirmed by measurements showing a clear correlation between the thickness and the HYA staining pattern. These findings may all result in a variety of impaired functions, e.g. leakage of water, nutrients, rigidity and stiffness of the normally smooth shear layer and an impaired migratory pattern of the epidermal cells. How the pathological processes in diabetes mellitus affect the synthesis and metabolism of HYA is not known but certainly needs to be further investigated.

ACKNOWLEDGEMENTS

The excellent technical assistance of Mrs Cathrine Johansson and Miss Ann-Louise Grehn and the outstanding secretarial help of Mrs Andrea Lotz are gratefully acknowledged. This study was supported by grants from the Swedish Research Council No: 17X-06578, the Medical Faculty of the University of Umeå and the Torsten and Ragnar Söderberg Foundation.

REFERENCES

1. Rosenbloom AL, Silverstein JH, Lezotte DC, Richardson K, McCallum M. Limited joint mobility in childhood diabetes mellitus indicates increased risk for microvascular disease. N Engl J Med 1981; 305: 191–194.
2. Starkman HS, Gleason RE, Rand LI, Miller DE, Soeldner JS. Limited joint mobility (LJM) of the hand in patients with diabetes mellitus: relation to chronic complications. Ann Rheum Dis 1986; 45: 130–135.
3. Tajima S, Nishikawa T, Hatano H, Nagai Y. Distribution of macromolecular components in human dermal connective tissue. Arch Dermatol Res 1982; 273: 115–120.
4. Lyons TJ, Kennedy L. Non-enzymatic glycosylation of skin collagen in patients with type 1 (insulin-dependent) diabetes mellitus and limited joint mobility. Diabetologia 1985; 28: 2–5.
5. Huntley AC. Cutaneous manifestations of diabetes mellitus. Dermatol Clin 1989; 7: 531–546.
6. van der Pijl JW, Daha MR, van den Born J, et al. Extracellular matrix in human diabetic nephropathy: reduced expression of heparan sulphate in skin basement membrane. Diabetologia 1998; 41: 791–798.
7. Tasma JT, van den Born J, Bruijn JA, et al. Expression of glomerular extracellular matrix components in human nephropathy. Decrease of heparan sulphate in the glomerular basement membrane. Diabetologica 1994; 37: 313–320.
8. Laurent TC, Fraser JRE. Hyaluronan. FASEB J 1992; 6: 2397–2404.
9. Burd DAR, Siebert JW, Ehrlich HP, Garg HG. Human skin and post-burn scar hyaluronan: demonstration of the association with collagen and other proteins. Matrix 1989; 9: 322–327.
10. Bertheim U, Hellström S. The distribution of hyaluronan in human skin and mature, hypertrophic and keloid scars. Br J Plast Surg 1994; 47: 483–489.
11. Wells AF, Lundin Å, Michaelsson G. Histochemical localization of hyaluronan in psoriasis, allergic contact dermatitis and normal skin. Acta Derm Venereol 1991; 71: 232–238.
12. Tammi R, Paukkonen K, Wang C, Horsmanheimo M, Tammi M. Hyaluronan and CD44 in psoriatic skin. Intense staining for hyaluronan on dermal capillary loops and reduced expression of CD44 and hyaluronan in keratinocyte-leukocyte interfaces. Arch Dermatol Res 1994; 286: 21–29.
13. Hellström S, Tengblad A, Johansson C, Hedlund U, Axelsson E. An improved technique for hyaluronan histochemistry using microwave irradiation. Histochemistry 1990; 22: 677–682.
14. Tengblad A. Affinity chromatography on immobilized hyaluronate and its applications to the isolation of hyaluronate binding proteins from cartilage. Biochim Biophys Acta 1979; 578: 282–289.
15. Laurent UBG, Tengblad A. Determination of hyaluronate in biological samples by a specific radioassay technique. Anat Biochem 1980; 109: 386–394.
16. Chapman DM, Ross JB. Objective measurement of three epidermal parameters in psoriasis vulgaris and in dermatopathology in general. Br J Dermatol 1988; 119: 333–343.
17. Lundbæk K. Stiff hands in long term diabetes. Acta Med Scand 1957; 158: 447–451.
18. Fernando DJS, Masson EA, Veves A, Boulton AJM. Relationship of limited joint mobility to abnormal foot pressures and diabetic foot ulceration. Diabetes Care 1991; 14: 8–11.
19. Garg SK, Chase HP, Marshall G, Jackson WE, Holmes D, Hoops S, et al. Limited joint mobility in subjects with insulin-dependent diabetes mellitus: relationship with eye and kidney complications. Arch Dis Child 1992; 67: 96–99.
20. Abatangelo G, Martelli M, Veccia P. Healing of hyaluronic acid enriched wounds: histological observations. J Surg Res 1983; 35: 410–416.
21. Hellström S, Laurent C. Hyaluronan and healing of tympanic membrane perforations. An experimental study. Acta Otolaryngol (Stockh) 1987; Suppl 442: 54–61.
22. Hanna W, Friesen D, Bombardier C, Gladmean D, Hanna A. Pathologic features of diabetic fix skin. J Ann Acad Dermatol 1987; 6: 546–553.
23. Laurent C, Hellström S, Fellenius E. Hyaluronan improves the healing of experimental tympanic membrane perforations: a comparison of preparations with different rheologic properties. Arch Otolaryngol Head Neck Surg 1988; 114: 1435–1441.
24. Lees VC, Fan TP, West DC. Angiogenesis in a delayed revascularization model is accelerated by angiogenic oligosaccharides of hyaluronan. Lab Invest 1995; 73: 259–266.