

INVESTIGATIVE REPORT

Iodine and Gliadin Challenge on Oral Mucosa in Dermatitis Herpetiformis

P. PATINEN^{1,2}, J. HIETANEN^{1,3}, M. MALMSTRÖM¹, T. REUNALA⁵ and E. SAVILAHTI⁴

¹Departments of Oral Surgery, Pathology and Medicine, Institute of Dentistry, University of Helsinki, ²Department of Oral and Maxillofacial Surgery, Department of Surgery, ³Oral Pathology Unit, Laboratory Diagnostics and ⁴Children's Hospital, Helsinki University Central Hospital, Helsinki, ⁵Departments of Dermatology, University Hospitals and Universities of Helsinki and Tampere, Finland

Oral lesions and mucosal inflammatory changes may appear in dermatitis herpetiformis (DH). We examined whether potassium iodine, known to initiate blisters in the DH skin, or wheat gliadin, responsible for T-cell-dependent intestinal damage, can induce visible or microscopic changes in oral mucosa. Six patients with active DH were challenged with crude gliadin and 50% potassium iodine applied in patch test chambers on buccal mucosa for 12 h. After reading, biopsies were taken from the challenged and non-challenged mucosa. No macroscopic or microscopic vesicles were seen. However, gliadin- but not iodine-challenged epithelium showed increased numbers of CD4+ lymphocytes in all 5 patients with representative specimens ($p=0.06$). No marked changes were found in the numbers of CD8+ or TcR α/β + lymphocytes, and the numbers of TcR γ/δ + cells remained at a low level. The results show that oral mucosa is resistant to production of macroscopic or microscopic DH lesions. It is, however, capable of reacting to locally applied gliadin by a T-cell response consisting of CD4+ lymphocytes. Key words: coeliac disease; dermatitis herpetiformis; gluten; iodine; oral mucosa; T lymphocytes.

(Accepted January 3, 2002.)

Acta Derm Venereol 2002; 82: 86–89.

Timo Reunala, Department of Dermatology, Tampere University Hospital, P.O. Box 2000, FIN-33521 Tampere, Finland. E-mail: timo.reunala@tays.fi

Dermatitis herpetiformis (DH) is a gluten-sensitive, blistering skin disease with pathognomic IgA deposits in the skin and oral mucosa (1, 2). Blisters may also occur in the oral cavity (3), and a recent study reported that mucosal ulceration and lymphocytic inflammation is a common finding in DH (4). The rash and damage in small bowel in DH respond to gluten withdrawal, but the effect of the diet on various oral lesions is not known. At present, it seems evident that a T-cell-mediated immune response against gliadin, a component of wheat gluten, is involved in the production of the gut lesion (5). Epithelial γ/δ T-cell receptor bearing lymphocytes (TcR) are typical of the inflamed intestine (6), but these cells seem not to be present in DH skin (7, 8).

In the present study in DH, we examined how sensitive

oral mucosa is to blister formation by challenging it with potassium iodine, an agent known to initiate blistering in DH skin (9). An additional challenge was performed with gliadin to study whether oral mucosa is capable of reacting against this antigen by a T-cell response.

MATERIAL AND METHODS

Patients

Six patients with DH (5 men, 1 woman, aged 35–75 years) volunteered for the study. The diagnosis of DH was based on demonstration of granular IgA deposits in the unaffected skin. Small-bowel biopsy showed subtotal or partial villous atrophy in 5 and inflammatory changes in one patient. At the time of the study, all patients used dapsone (25–75 mg/day) to control the rash. Three newly diagnosed patients were on a normal gluten-containing diet and 3 had tried for several months to adhere to a gluten-free diet, but had all consumed some gluten, at least weekly. Five of the patients had increased IgA class antigliadin antibody levels in ELISA and 4 showed IgA endomysium antibodies (titer 10–1600) in the serum (10). Dapsone was withdrawn 48 h before the study and after it all patients showed active skin lesions. Two healthy volunteers (age 37 and 42 years) served as controls in oral challenge.

The study was approved by the Ethics Committee of Helsinki University Hospital for Skin and Allergic Diseases.

Challenges and immunohistochemistry

Fifty percent potassium iodine in petrolatum and gliadin powder (30 mg; Sigma Chemicals, St. Louis, MO, USA) moistened with but not diluted in physiological saline was applied in 8 mm diameter aluminum patch test chambers (Finchamber, Epicon Ltd, Tuusula, Finland). These were fixed with occlusive bandage (Stomahesive[®], Squibb, Princeton, NJ, USA) on buccal mucosa of the molar area just below linea alba. The chambers were removed after 12 h and 4 mm punch biopsies were taken from the challenged and non-challenged (control) mucosa under 2% lidocaine with adrenalin.

The biopsy specimens were snap-frozen in liquid nitrogen, embedded in a mounting media (OCT, Tissue Tek; Miles, Elkhart, IN, USA) and the staining was performed with the avidin-biotin peroxidase method as previously described (6, 10). Monoclonal antibodies used were OKT8 (dilution 1:20; Becton Dickinson, Mountain View, CA, USA) for CD8+ cells, T4 (dilution 1:20; Coulter Immunology, Hialeah, FL, USA) for CD4+ cells, TCRd1 (dilution 1:200; T cell Sciences, Cambridge, MA, USA) for TcR gamma/delta+ cells and BF1 (dilution 1:100; T cell Sciences) for TcR alpha/beta+ cells. Counterstaining was performed with haematoxylin. Positively

stained T cells were counted in the epithelium and lamina propria with a light microscope through a calibrated graticule at $400\times$ magnification, as previously described (11). The results were given as cells/mm².

Statistics

The permutation test for paired replicates was used to compare the cell counts in the challenged and control mucosa (12). A *p*-value below 0.05 was considered significant.

RESULTS

Clinical and histological findings

Though all 6 patients with DH had active lesions in the skin at the end of the 12-h oral challenge, none of them showed any blisters or clinically evident inflammatory changes on the potassium-iodine- or gliadin-challenged buccal mucosa. In agreement with this, none of the biopsy specimens from the challenge sites showed sub-epithelial vesicles or polymorphonuclear leukocyte microabscesses typical of DH lesions. The oral mucosa of the 2 gliadin and potassium-iodine-challenged control persons remained also clinically and histologically negative.

T-cell response

In the epithelium, all 5 patients with representative biopsy specimens showed increased numbers of CD4+ T lymphocytes compared to the control sites in the gliadin challenge sites (Fig. 1). This increase was almost significant ($p=0.06$). In contrast to gliadin, potassium iodine did not cause any marked influx of CD4+ lymphocytes into the epithelium (Fig. 1). The alpha/beta

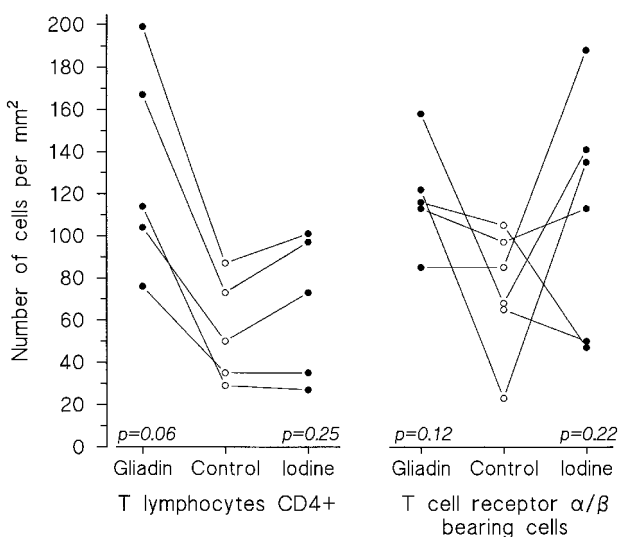


Fig. 1. Numbers of CD4+ and T-cell receptor alpha/beta bearing lymphocytes in the buccal epithelium of 5 patients with dermatitis herpetiformis after the 12h challenge with gliadin and potassium iodine. Control specimens were taken from unchallenged buccal mucosa.

TcR+ cells did not show any statistically significant change either in the gliadin or in the potassium iodine challenge sites because individual variation was large (Fig. 1). Similarly, no significant change were found in the numbers of CD8+ cells in the gliadin (median 111 cells/mm²; percentiles 75 and 154 cells/mm²) or potassium iodine (106; 81 and 184 cells/mm²) challenge sites compared to the control sites (45; 31 and 114 cells/mm²; $p=0.12$ and 0.44).

In the lamina propria, the numbers of CD4+ cells in the gliadin (109; 103 and 156 cells/mm²) or potassium iodine (47; 23 and 72 cells/mm²) challenge sites did not show any marked increase compared to control sites (28; 15 and 58 cells/mm²; $p=0.12$). Similarly, the numbers of TcR alpha/beta+ cells were unaltered in the gliadin (57; 37 and 72/cells/mm²) and potassium iodine (107; 36 and 144 cells/mm²) challenge sites compared to the control sites (62; 47 and 87 cells/mm²; $p=0.03$ and 0.37).

In contrast to alpha/beta TcR+ cells, only very few gamma/delta TcR+ cells were seen intraepithelially or in lamina propria in the gliadin- or potassium-iodine-challenged sites (maximum 5 cells/mm²) or in the control sites, so no statistical comparisons could be performed.

DISCUSSION

It is generally believed that DH rarely affects the oral cavity, though pathognomonic IgA deposits occur frequently in the oral mucosa (1, 2). In an earlier DH study, however, oral lesions were found in more than 70% of patients and a recent study reported unspecified mucosal ulceration in 37% of patients compared to none of the controls (3, 4). In the present study we examined 6 patients with active DH in the skin and exposed their normal-appearing oral mucosa to 50% potassium iodine. We observed no visible or microscopic lesions in the oral mucosa, though in the previous studies skin challenge with potassium iodine has brought lesions to most patients with active DH (9, 13). We conclude, therefore, that at least in experimental conditions oral mucosa is not as sensitive as the skin for development of DH lesions. One possible reason for the different responses could be that the oral epithelial cells do not respond to an inflammatory agent, i.e. potassium iodine, in a similar way to the keratinocytes in the skin by showing early upregulation of urokinase plasminogen activator with subsequent activation of macrophage matrix metalloproteinase (13, 14).

In the present study we also examined whether gliadin challenge on oral mucosa could produce oral lesions or influx of immunocompetent cells. No visible or microscopic blisters were seen, but gliadin challenge caused a marked influx of CD4+ lymphocytes in the epithelium in all 5 patients with representative specimens (Fig. 2). This increase was statistically almost significant ($p=0.06$). In contrast to CD4+ lymphocytes, the numbers

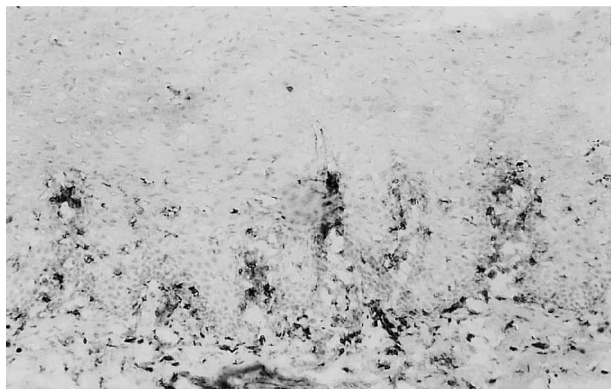

Fig. 2. Increased numbers of CD4+ T-lymphocytes in the oral epithelium and lamina propria after the 12-h gliadin challenge in a patient with dermatitis herpetiformis.

of CD8+ and alpha/beta TcR+ cells remained unaltered in the epithelium. These findings are in good agreement with those observed recently by Lähteenoja et al. in patients with coeliac disease (15, 16). They applied gliadin powder on oral mucosa with the aid of an adhesive bandage for 6–24 h and found a similar increase of the CD4+ cells in the epithelium as we did. These results show that, at least under occlusion, gliadin, which is fairly insoluble in water, can penetrate mucosa and cause an influx of immunocompetent cells. Supporting this, Lähteenoja et al. (15, 16) could also document an influx of the TcR alpha/beta+ cells and increased expression of IL-2 receptor on T cells with submucosally injected gliadin or gliadin peptides. Moreover, the present study in DH and the previous study in coeliac disease by Lähteenoja et al. (15) documented that mucosal gliadin challenge did not cause any influx of TcR gamma/delta+ cells into the epithelium, indicating that a marked difference exists between the occurrence of these cells in the oral and gut mucosa (6, 11, 18).

The present and previous results in the patients with DH and coeliac disease indicate that application of gliadin on oral mucosa is capable of causing a prominent CD4+ influx into the epithelium and that submucosal injection of gliadin causes TcR alpha/beta+ cell influx and general T-cell activation. Further studies are needed to show the specificity and cytokine pattern of the orally invading T cells, because gliadin-specific T cells are known to occur in coeliac intestine (18, 19) though not in the DH skin (20, 21).

In conclusion, the present study showed that DH lesions are not easy to produce on oral mucosa. It also documented that in DH, as in coeliac disease, mucosal gliadin challenge can evoke a CD4+ lymphocyte but not TcR gamma/delta+ cell influx into the oral epithelium.

ACKNOWLEDGEMENTS

We thank Hanu Kautiainen, MA, for performing statistical analyses. The skilful technical assistance of Ms Sirkku

Kristiansen and Mrs Marjatta Kivekäs is greatly acknowledged. The study was supported by a grant from the Finnish Dental Society.

REFERENCES

1. Reunala TL. Dermatitis herpetiformis. *Clin Dermatol* 2001; 19: 728–736.
2. Hietanen J, Reunala T. IgA deposits in the oral mucosa of patients with dermatitis herpetiformis. *Scand J Dent Res* 1984; 92: 230–234.
3. Fraser NG, Kerr NW, Donald D. Oral lesions in dermatitis herpetiformis. *Br J Dermatol* 1973; 89: 439–440.
4. Lähteenoja H, Irjala K, Viander M, Vainio E, Toivanen A, Syrjänen S. Oral mucosa is frequently affected in patients with dermatitis herpetiformis. *Arch Dermatol* 1998; 134: 756–758.
5. Mollberg O, McAdam SN, Körner R, et al. Tissue transglutaminase selectively modifies gliadin peptides that are recognized by gut-derived T cells in celiac disease. *Nature Med* 1998; 4: 713–717.
6. Savilahti E, Reunala T, Mäki M. Increase of lymphocytes bearing the gamma/delta T cell receptor in the jejunum of patients with dermatitis herpetiformis. *Gut* 1992; 33: 206–211.
7. Kell DL, Glusac EJ, Smoller BR. T lymphocytes bearing the gamma/delta T-cell receptor in cutaneous lesions in dermatitis herpetiformis. *J Cutan Pathol* 1994; 21: 413–418.
8. Garioch JJ, Baker BS, Leonard JN, Fry L. T lymphocytes in lesional skin of patients with dermatitis herpetiformis. *Br J Dermatol* 1994; 131: 822–826.
9. Haffenden GD, Blenkinsopp WK, Ring NP, Wojnarowska F, Fry L. The potassium iodine patch test in dermatitis herpetiformis in relation to treatment with a gluten free diet and dapsone. *Br J Dermatol* 1980; 102: 313–317.
10. Reunala T, Chorzelski TP, Viander M, Sulej J, Vainio E, Kumar V, Beutner EH. IgA anti-endomysial antibodies in dermatitis herpetiformis: correlation with jejunal morphology, gluten-free diet and antigliadin antibodies. *Br J Dermatol* 1987; 117: 185–191.
11. Patinen P, Savilahti E, Hietanen J, Malmström M, Mäki M, Reunala T. Intraepithelial lymphocytes bearing the gamma/delta receptor in the oral and jejunal mucosa in patients with dermatitis herpetiformis. *Eur J Oral Sci* 1997; 105: 130–135.
12. Siegel S, Castellan NJ Jr. *Nonparametric statistics for the behavioural sciences*. McGraw-Hill Book Company, Singapore; 1988.
13. Airola K, Reunala T, Salo S, Saarialho-Kere U. Urokinase plasminogen activator is expressed in basal keratinocytes before interstitial collagenase, stromelysin-1 and laminin-5 in experimentally induced dermatitis herpetiformis lesions. *J Invest Dermatol* 1997; 108: 7–11.
14. Salmela MT, Pender SLF, Reunala T, MacDonald T, Saarialho-Kere U. Parallel expression of macrophage metalloelastase (MMP-12) in duodenal and skin lesions of patients with dermatitis herpetiformis. *Gut* 2001; 48: 496–502.
15. Lähteenoja H, Mäki M, Viander M, Toivanen A, Syrjänen S. Local challenge of oral mucosa with gliadin in patients with coeliac disease. *Clin Exp Immunol* 2000; 120: 38–45.
16. Lähteenoja H, Mäki M, Viander M, Rähä I, Vilja P, Rantala I, et al. Local challenge of oral mucosa with an alpha-gliadin related synthetic peptide in patients with celiac disease. *Am J Gastroenterol* 2000; 95: 2880–2887.
17. Maiuri L, Pickarelli A, Boirivant M, Coletta S, Mazzirilli

- MC, De Vincenzi M, et al. Definition of the initial immunologic modifications upon *in vitro* gliadin challenge in the small intestine of celiac patients. *Gastroenterology* 1996; 110: 1368–1378.
18. Lundin KEA, Scott H, Hansen T, Paulsen G, Halstensen TS, Fausa O, et al. Gliadin specific, HLA-DQ (alpha 1*0501, beta 1*0201) restricted T cells isolated from the small intestinal mucosa of coeliac patients. *J Exp Med* 1993; 178: 187–196.
19. Schuppan D, Dieterich W, Riecken EN. Exposing gliadin as a tasty food for lymphocytes. *Nature Med* 1998; 4: 666–667.
20. Baker BS, Garioch JJ, Bokth S, Leonard JN, Fry L. Absence of gluten-specific T lymphocytes in the skin of patients with dermatitis herpetiformis. *J Autoimmun* 1995; 8: 75–82.
21. Caproni M, Feliciani G, Fuligni A, Salvatore E, Atani L, Boanchi B, et al. Th2-like cytokine activity in dermatitis herpetiformis. *Br J Dermatol* 1998; 129: 530–532.