

CLINICAL REPORT

Chronic Active EB Virus Infection Complicated with IgG3 Subclass Deficiency: An Adult Case Treated with Intravenous Immunoglobulin and IFN- α HIROSHI MITSUI¹, MAYUMI KOMINE¹, AKIRA SHIRAI¹, NAOKO KANDA¹, AKIHIKO ASAHINA¹, HITOSHI OKOCHI¹, SHIGEMI HITOMI², SATOSHI KIMURA² and KUNIHICO TAMAKI¹*Departments of ¹Dermatology and ²Infection Control and Prevention, University of Tokyo, Tokyo, Japan*

A 60-year-old man presented with recurrent genital and oral ulcers, necrotic papules on his face and scalp, spiking fever and indurated skin erythema on the trunk. A diagnosis of chronic active Epstein-Barr virus infection and IgG3 subclass deficiency was made, and he was supplemented by intravenous gammaglobulin injection. The spiking fever was resistant to treatment, but the addition of systemic interferon- α therapy was partially effective in treating his clinical symptoms, although the patient eventually died from pulmonary effusions and cardiac insufficiency. Key words: chronic active EB virus infection; interferon- α ; immunoglobulin; lymphoproliferative disease.

(Accepted August 16, 2002.)

Acta Derm Venereol 2003; 83: 31–35.

Hiroshi Mitsui, M.D., Department of Dermatology, Faculty of Medicine, University of Tokyo, 7-3-1 Hongo, Bunkyo-ku, Tokyo 113-8655, Japan
E-mail: mitsuhi-der@h.u-tokyo.ac.jp

Many cases of chronic active Epstein-Barr virus (CAEBV) infection have been reported, mainly in children (1), and the clinical course is usually progressive, frequently evolving into lymphoma (2, 3). The standard therapeutic regimen has not been established, but various approaches have been reported. Although interferon (IFN)- α is known to suppress viral DNA replication by affecting its basal promoter activation machinery, it is seldom used for this disease. We encountered an adult case of CAEBV with IgG3 subclass deficiency – an extremely rare case. Intravenous immunoglobulin and IFN- α suppressed the frequency of spiking fever and led to an improvement in ulceration of the genitals.

CASE REPORT

A 60-year-old man had been suffering from oral ulcers, fever and pharyngitis for 2 years, his symptoms repeatedly waxing and waning. He had consulted several doctors, but failed to get a specific clinical diagnosis.

He was otherwise healthy and had had no serious illnesses. He was referred to our hospital in November 1996 with recurrent oral ulcers, necrotic papules, exudative erythema and recurrent fever. On examination, shallow ulcers were noted on his lips, soft palate and buccal mucosa, and reddish papules with necrotic central ulcers and crusts on his face and scalp (Fig. 1A–C). Routine laboratory tests revealed a white blood cell count of $3.5 \times 10^9/l$ (eos 2.0%, st 6.0%, mono 6.0%, lym 6.0%, segmental leukocytes 80.0%), a red blood cell count of $4.11 \times 10^9/l$, total protein of 6.9 g/dl, Alb of 3.6 g/dl, GOT of 25 IU, GPT of 11 IU, γ GTP of 22 IU, BUN of 18.4 mg/dl, creatinine of 1.0 mg/dl, ESR of 46 mm/h and CRP of 2.4 mg/dl. We first suspected exudative erythema multiforme from his skin eruption tested. Of the virus antibody titres tested, those against Epstein-Barr virus (EBV) were elevated (Table I, 1997.5). The antibody titres against cytomegalovirus (CMV) were as follows: the anti-CMV IgG titre $\times 25.7$, the anti-CMV IgM titre $\times 0.86$. The antibody against human immunodeficiency virus was negative, as was the antibody against adult T cell leukaemia antigen. Natural killer cell activity was normal (24%) and the CD4/8 ratio was also normal (2.3).

After admission to our hospital in November 1996, the patient developed extensive erosive lesions on his genital area (Fig. 1D) and vesicles with erythema on his thighs. Both were resistant to intravenous administration of antibiotics such as cephem, carbapenem, macrolides and new quinolones or antiviral agents such as acyclovir. Recurrent spiking fever repeatedly waxed and waned and was also resistant to therapy. There were no signs of malignancies with whole-body CT-scan. No autoantibodies were detected. Behçet disease was suspected but was unlikely because of the lack of other symptoms, including ocular involvement or needle reactions.

Histopathological examination of samples taken from the necrotic papules on his face, vesicles on the thighs and erosions on the lips revealed dense infiltration of mononuclear cells in the upper dermis and in the necrotic epidermis (Fig. 2). The infiltrating cells were

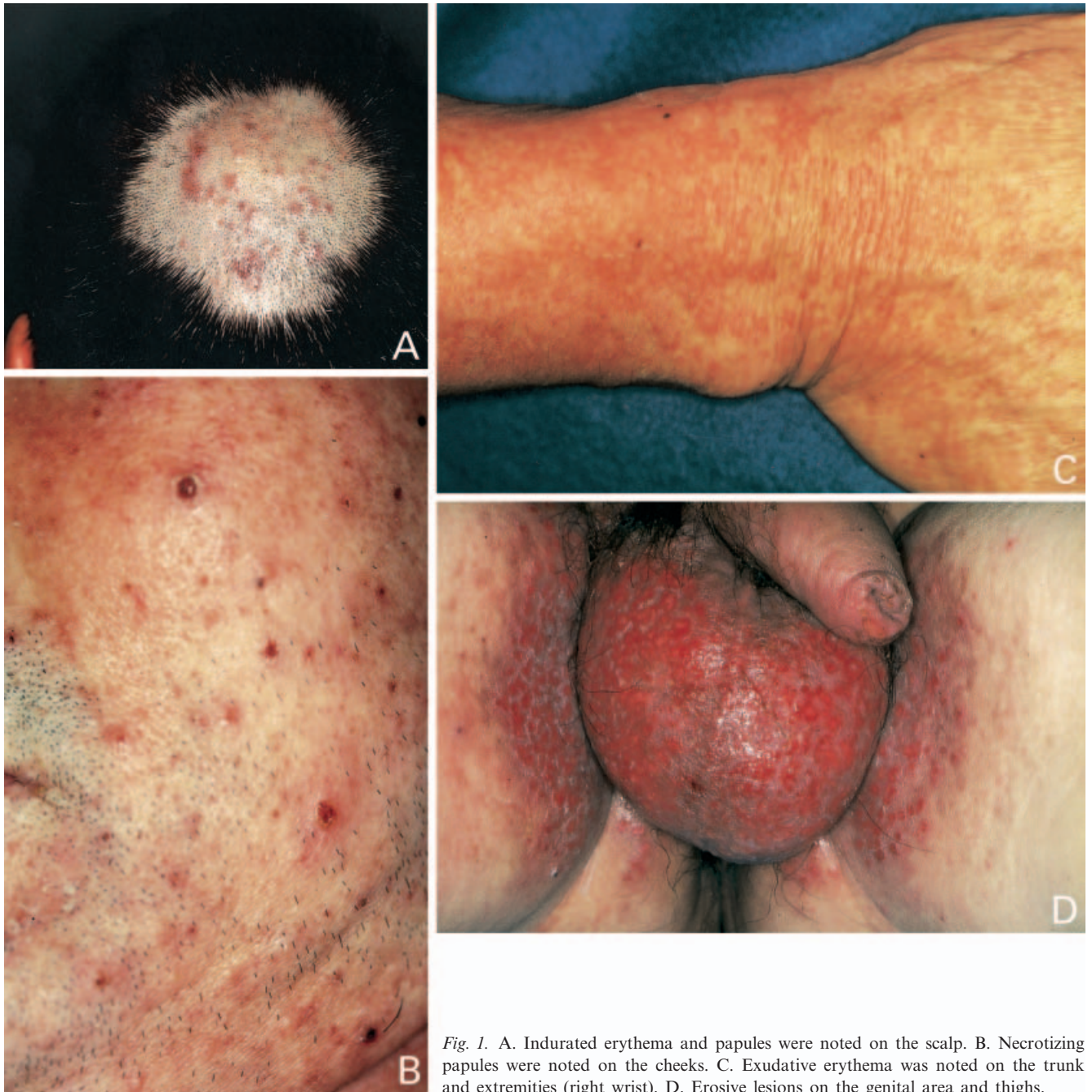


Fig. 1. A. Indurated erythema and papules were noted on the scalp. B. Necrotizing papules were noted on the cheeks. C. Exudative erythema was noted on the trunk and extremities (right wrist). D. Erosive lesions on the genital area and thighs.

monotonous, but no atypia was found. Immunohistochemical staining for surface markers of the infiltrating cells showed a predominance of CD8+ lymphocytes over CD4+ lymphocytes. EBV-encoded small RNA (EBER) *in situ* hybridization was positive in the infiltrating T cells (Fig. 3). Southern blotting of the DNA revealed no gene rearrangement bands when digested with BamH1 and EcoR1 and probed for TCR C β 1 or C γ -genes. Continuous high titres and unusual patterns of EBV antibodies and positive EBER *in situ* hybridization resulted in our diagnosing this case as CAEBV.

Low levels of IgG3 continued throughout the course

of the disease thus fulfilling the criteria for IgG subclass deficiency (i.e. serum IgG3 < 0.21 mg/dl (4)). However, there were no data of IgG3 levels before the diagnosis of CAEBV. Intravenous γ -globulin supplementation (5 g per week) was started, but without improving the serum IgG3 levels (see Table I). In addition, recurrence of the genital lesions and spiking fever became progressively more frequent. The necrotic papules and vesicles on his thighs gradually worsened. The genital erythema and ulcers became indurated and dark, and spread to the insides of the thighs. Inguinal lymph nodes became palpable and skin biopsies of necrotic papules and genital erythema about 2 years after

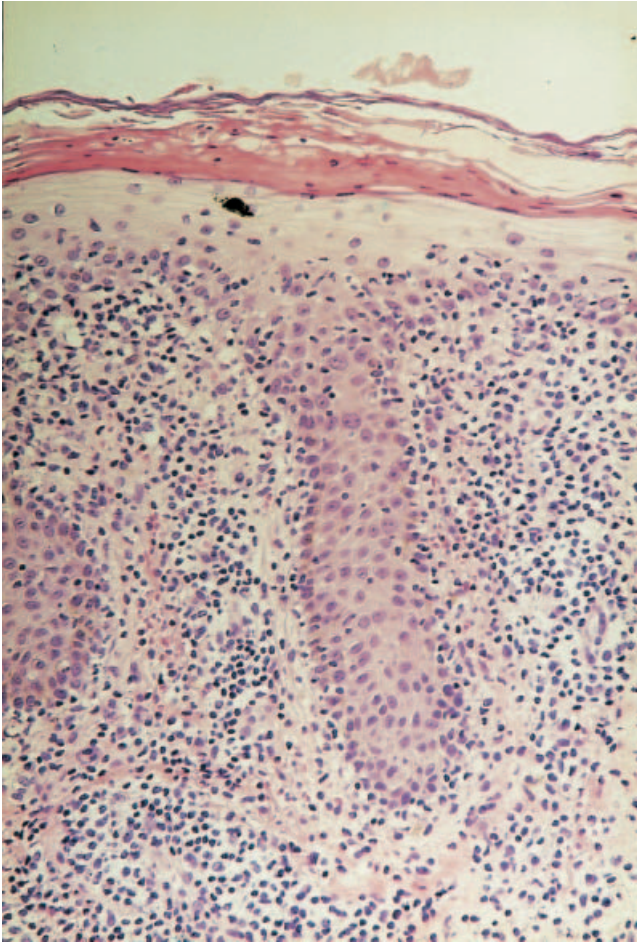


Fig. 2. Dense infiltration of mononuclear cells in the upper dermis and in the necrotic epidermis. The infiltrating cells were monotonous but no atypia was found.

admission showed much denser infiltration of lymphocytes. Some of the infiltrating cells showed nuclear atypia. However, no clonal rearrangement of the TCR- β or γ -chain was noted.

Because intravenous γ -globulin supplementation was not effective, we added intravenous IFN- α therapy to suppress the self-replication of EBV, according to the protocol of IFN- α therapy for chronic active hepatitis C virus infection. IFN- α was administered 6 million IU per shot, 6 times per week. Although there was no clinical improvement in the first 2 months, the spiking fever and skin and mucosal lesions gradually subsided during the 5 months of intravenous γ -globulin and IFN- α therapy (Table I), but without significant improvement of serum IgG3 levels.

Serum concentrations of IL-1 β , IL-2, IL-4, IL-6, TNF- α , IFN- γ and sIL-2R were measured before and after the therapy (Table I), but did not markedly improve despite clinical improvements. We also measured total blood concentrations of EBV-DNA as the marker of remission before and after the therapy

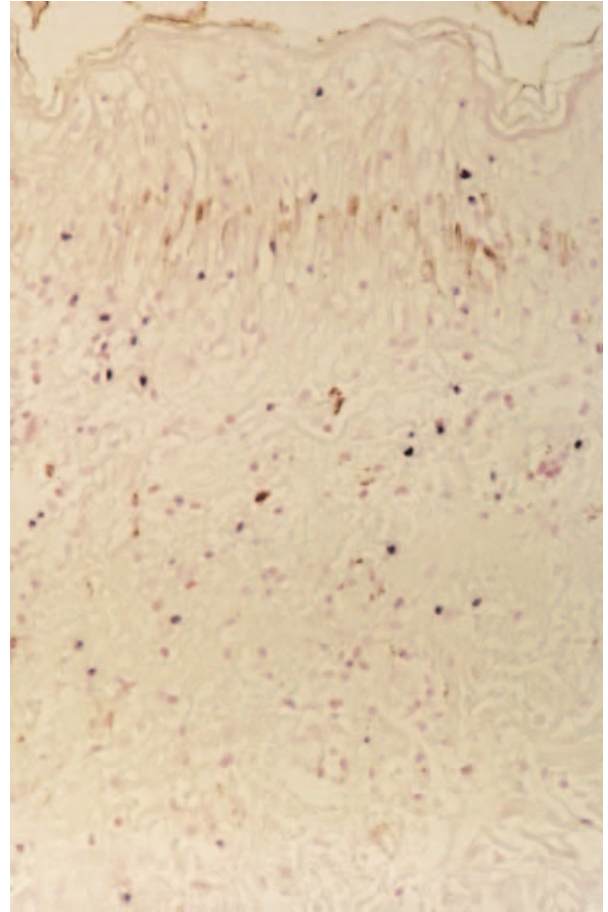


Fig. 3. EBV-encoded small RNA (EBER) *in situ* hybridization was positive in the infiltrating T cells.

(Table I), which showed only a slight decrease. The antibody titres against EBV were not improved.

IFN- α injection was stopped after 5 months of clinical improvement, and severe spiking fever developed again after 14 days. The fever did not respond to antibiotics or γ -globulin administration, and although additional IFN- α therapy was started the patient developed pulmonary effusion and died of cardiac insufficiency. Although erythema exacerbated after IFN- α withdrawal, other skin and mucosal lesions did not relapse. The size of lymph nodes remained unchanged. Autopsy was not performed because of the family's refusal.

DISCUSSION

CAEBV is characterized by recurrent infectious mononucleosis-like symptoms lasting for at least 1 year, and is known to show an unusual pattern of anti-EBV titres (5–7). This entity was first described by Rickinson (6) in 1986. Since then, many cases have been reported, especially in children, and usually with a poor prognosis (1). No adult patients over 60 years of age have

Table I. Clinical symptoms and laboratory data of the patient. Clinical symptoms were improved after the therapy of immunoglobulin (IG) and IFN- α therapy.^a

| | 1997.5 | 1998.2 | 1998.4 | 1998.10 | 1998.12 | 1999.3 |
|---|--------|--------|--------|-----------------|---------|-------------------|
| Spike fever $\geq 38^{\circ}\text{C}$ (times/month) | 13 | 15 | 11 | 21 | 5 | 4 |
| IgA (mg/dl) (107–363) | 621 | 544 | 262 | 510 | 392 | 324 |
| IgG (mg/dl) (739–1649) | 1585 | 1993 | 2314 | 2542 | 3602 | 3621 |
| IgM (mg/dl) (46–260) | 133 | 169 | 110 | 191 | 149 | 114 |
| IgG3 (mg/ml) (0.6–0.89) | nd | 0.11 | nd | 0.11 | 0.15 | n.d. |
| C3 (mg/dl) (44–102) | 57 | 64 | nd | 21 | nd | nd |
| C4 (mg/dl) (14–49) | 42 | 49 | nd | 37 | nd | nd |
| Copies/1000ngDNA (EB) | nd | nd | nd | 2×10^6 | nd | 0.9×10^6 |
| anti-VCA IgG | 1280 | 2560 | 640 | 640 | 1280 | 640 |
| anti-VCA IgM | 10 | 10 | 10 | nd | 10 | 10 |
| anti-EA IgG | 160 | 40 | 10 | 40 | 10 | 20 |
| anti-EBNA IgG | 10 | 10 | nd | 10 | nd | nd |
| IL-1 β (pg/ml) (<10) | 14 | nd | 12 | nd | 11 | nd |
| IL-2 (U/ml) (<0.8) | nd | nd | <0.8 | <0.8 | 0.87 | nd |
| IL-4 (pg/ml) (<6.0) | nd | nd | 18.1 | 7.7 | 3.7 | nd |
| IL-6 (pg/ml) (<4.0) | 19.7 | nd | 53.6 | 12.5 | 19.7 | nd |
| IL-10 (pg/ml) (<5) | nd | nd | 27 | nd | nd | nd |
| TNF- α (pg/ml) (<5) | nd | nd | nd | <5 | 5.7 | nd |
| IFN- γ (IU/ml) (<0.1) | 1.5 | nd | 18.9 | 2.6 | 1.5 | nd |
| sIL-2R (U/ml) (167–497) | 1144 | 855 | 43580 | 3109 | 4109 | 4915 |

^a1998.4: Immunoglobulin therapy; 1998.9: Immunoglobulin + IFN- α therapy; 1998.11–1999.3: Clinical symptoms were improved; 1999.5: Death. nd=no data.

been reported. In patients with EBV infection, various kinds of cutaneous manifestations are found, such as persistent erythema multiforme (8), mucocutaneous necrotizing dermatosis (9), maculopapular eruptions (10) and genital ulcers (11). All these manifestations were noted in our patient (Fig. 1), who also presented with IgG3 deficiency, which is possibly a cause of CAEBV, since IgG1 and IgG3 bind to Fc receptors on phagocytic cells and can activate the classical complement pathway (12). Wakiguchi et al. (13) measured the serum levels of IgG subclasses in 30 children with CAEBV. Although the serum levels of IgG1 were elevated, those of IgG2, IgG3 and IgG4 were decreased in 6, 3 and 4 cases, respectively. Linde et al. (14) reported that patients with IgG3 deficiency had an increased frequency of reactivated herpes virus infections. Grierson et al. (15) also reported that immune defects were present prior to EBV infection; 12 of 13 patients with EBV-related X-linked lymphoproliferative disease had decreased levels of one or more IgG subclasses. IgG3 deficiency occurred in all 12 cases while decreased IgG1 occurred in 7 out of 12 cases. It is not clear whether IgG3 subclass deficiency existed prior to the EBV infection in our case. Immunoglobulin supplementation failed to improve the clinical symptoms, and the clinical improvement was not accompanied by an IgG3 increase in our case, suggesting that the IgG3 level may not be important in relation to the cause of CAEBV.

Various treatment protocols, including oral prednisolone, acyclovir and IFN- α , have been used to treat patients with CAEBV, but most have been unsuccessful (1). In our case, IFN- α and immunoglobulin therapy caused a temporary improvement of the clinical symptoms. However, cytokine data showed only slight changes and the patient died 2.5 years after admission.

IFN- α is known to suppress viral replication by inhibiting basal transcription machinery, and the administration of IFN- α has been reported to be effective in patients with EBV-associated B-cell lymphoproliferative disorders (16). Sakai et al. (17) reported the application of IFN- α to patients with EBV-associated T-cell lymphoproliferative disorders, which resulted in unremarkable suppression of lymphocyte proliferation. In the case studied by us, neither EBV DNA nor antibody titres showed significant changes during the course of treatment. IFN- α modulates immunoglobulin production from human peripheral blood mononuclear cells and stimulates immunoglobulin synthesis by B cells *in vitro* (18), which may have helped improve the clinical symptoms in our patient.

In summary, we report here the first case of CAEBV in a patient with IgG3 subclass deficiency treated with IFN- α and immunoglobulin. We believe that IFN- α and immunoglobulin therapy was responsible for at least a temporary remission of the clinical symptoms and a longer survival time, and suggest that the effectiveness of this therapy in CAEBV should be further investigated.

ACKNOWLEDGEMENT

We thank Dr Satoshi Shinohara for diagnostic assistance.

REFERENCES

- Ishihara S, Okada S, Wakiguchi H, Kurashige T, Morishima T, Kawa-Ha K. Chronic active Epstein-Barr virus infection in children in Japan. *Acta Paediatr* 1995; 84: 1271–1275.
- Jones JF, Shurin S, Abramowsky C, Tubbs RR, Sciotto CG, Wahl R, et al. T-cell lymphomas containing Epstein-Barr viral DNA in patients with chronic Epstein-Barr virus infections. *N Engl J Med* 1988; 318: 733–741.
- Kawa-Ha K, Ishihara S, Ninomiya T, Yumura-Yagi K, Hara J, Murayama F, et al. CD-3-negative lymphoproliferative disease of granular lymphocytes containing Epstein-Barr viral DNA. *J Clin Invest* 1989; 84: 51–55.
- Plebani A, Ugazio AG, Avanzini MA, Massimi P, Zonta L, Monafò V, et al. Serum IgG subclass concentrations in healthy subjects at different age: age normal percentile charts. *Eur J Pediatr* 1989; 149: 164–167.
- Okano M, Matsumoto S, Osato T, Sakiyama Y, Thiele GM, Purtilo DT. Severe chronic active Epstein-Barr virus infection syndrome. *Clin Microbiol Rev* 1991; 4: 129–135.
- Rickinson AB. Chronic, symptomatic Epstein-Barr virus infections. *Immunol Today* 1986; 7: 13–14.
- Straus SE. The chronic mononucleosis syndrome. *J Infect Dis* 1988; 157: 405–412.
- Drago F, Romagnoli M, Loi A, Rebora A. Epstein-Barr virus-related persistent erythema multiforme in chronic fatigue syndrome. *Arch Dermatol* 1992; 128: 217–222.
- Okada N, Tei H, Yamamura T, Sato K, Negoro S, Yoshikawa K. Recurrent mucocutaneous lymphocytic infiltration possibly associated with Epstein-Barr virus infection. *Dermatologica* 1991; 183: 139–142.
- Katz BZ, Andiman WA. Infectious mononucleosis. In: Fitzpatrick TB, Eisen AZ, Wolff K, et al., editors. *Dermatology in general medicine*. New York: McGraw-Hill, 1987: 2372–2375.
- Portnoy J, Ahronheim GA, Ghibu F, Clecner B, Joncas JH. Recovery of Epstein-Barr virus from genital ulcers. *N Engl J Med* 1984; 311: 966–968.
- Heiner D. Significance of immunoglobulin G subclasses. *Am J Med* 1984; 76: 1–6.
- Wakiguchi H, Hisakawa H, Hosokawa T, Kubota H, Kurashige T. Analysis of IgG subclasses in chronic active Epstein-Barr virus infections. *Ped Int* 2000; 42: 21–25.
- Linde A, Soderstrom R, Smith CI, Sallberg M, Dahl H, Grubb R, et al. Herpesvirus serology, aberrant specific immunoglobulin G2 and G3 subclass patterns and Gm allotypes in individuals with low levels of IgG3. *Clin Exp Immunol* 1992; 90: 199–203.
- Grierson HL, Skare J, Hawk J, Pauza M, Purtilo DT. Immunoglobulin class and subclass deficiencies prior to Epstein-Barr virus infection in males with X-linked lymphoproliferative disease. *Am J Med Genetics* 1991; 40: 294–297.
- Trigg ME, de Alarcon P, Rumelhart S, Holida M, Giller R. α -interferon therapy for lymphoproliferative disorders developing in two children following bone marrow transplants. *J Biol Response Modifiers* 1989; 8: 603–613.
- Sakai Y, Ohga S, Tonegawa Y, Takada H, Nakao F, Nakayama H, et al. Interferon- α therapy for chronic active Epstein-Barr virus infection: potential effect on the development of T-lymphoproliferative disease. *J Ped Hematol/Oncol* 1998; 20: 342–346.
- Rodriguez MA, Prinz WA, Sibbitt WL, Bankhurst AD, Williams RC Jr. Alpha-interferon increases immunoglobulin production in cultured human mononuclear leukocytes. *J Immunol* 1983; 130: 1215–1219.