

Adult Multiple Xanthogranulomas with Spontaneous Resolution

Sung-Jan Lin and Hsien-Ching Chiu*

Department of Dermatology, National Taiwan University Hospital and National Taiwan University College of Medicine, 7 Chung-Shan South Road, Taipei, Taiwan 10016. *E-mail: hcc@ha.mc.ntu.edu.tw

Accepted October 19, 2002.

Sir,

Multiple xanthogranulomas in adults are rare, and complete resolution of this condition in adults has never been reported before. We report here on a case of multiple xanthogranulomas in a 60-year-old Taiwanese woman. The lesions spontaneously resolved in one year.

CASE REPORT

A 60-year-old Taiwanese woman was referred in August 1999 for evaluation of multiple papules. Two months earlier, she first noted a reddish papule on her left buttock. In the subsequent 2 months, multiple similar lesions developed on her back, abdomen, chest and face. The patient had a history of hypertension for 9 years, diabetes mellitus for 8 years and atrial fibrillation for 3 years, and had undergone a hysterectomy 9 years earlier because of uterine leiomyoma. There was no pertinent family history of similar cutaneous lesions. At onset of the skin lesions, the patient was taking Tenormin[®] (atenolol) at 100 mg daily, Capoten[®] (captopril) 25 mg t.i.d., Apresoline[®] (hydralazine) 50 mg t.i.d., and Euglucon[®] (glyburide) 5 mg t.i.d. for more than 3 years. On physical examination about 20 dome-shaped, smooth-surfaced, yellowish to erythematous papules measuring 2- to 5-mm were revealed on her face, trunk and buttocks (Fig. 1a). Neither café-au-lait spots nor other signs of neurofibromatosis were noted. The laboratory examinations, including a complete blood count, urinalysis, liver function tests and renal function tests, were all within the normal range. The patient's serum lipid profile, showing total cholesterol 168 mg/dl (normal range: 130–220 mg/dl), LDL-C 99 mg/dl (normal range: <150 mg/dl), HDL-C 51 mg/dl (normal range: >35 mg/dl) and triglycerides 89 mg/dl (normal range: <200 mg/dl), was also within normal limits. A chest X-ray and an ophthalmological examination were also normal. A skin biopsy specimen of a yellowish papule showed a dome-shaped nodular infiltration of foamy histiocytes admixed with many Touton giant cells and lymphocytes in the papillary and reticular dermis (Fig. 2). Some eosinophils were also noted. The epidermis was flattened with a collarette at the periphery. Stain for S-100 protein revealed no staining of the tumor cells.

After the patient's first visit, similar new lesions continued to develop. Physical examination at her follow-up visit in November 1999 revealed 58 lesions scattered over her face, trunk, buttocks and proximal thighs. A second skin biopsy specimen was obtained from a new lesion. Infiltration of histiocytes was found in the dermis admixed with lymphocytes. The histiocytes showed fewer foamy changes than those in the previous biopsy, and some Touton giant

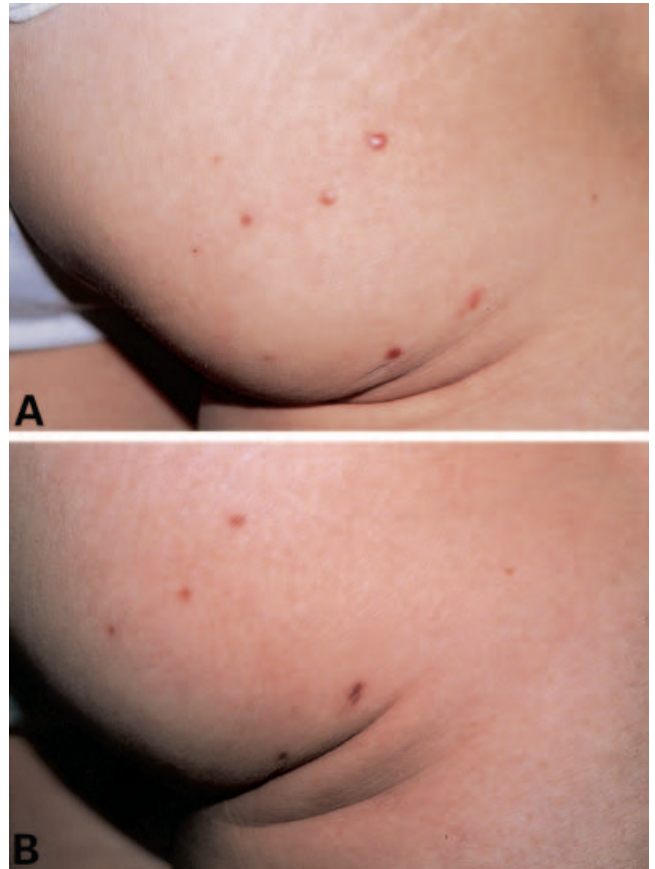


Fig. 1. Several yellowish to erythematous papules on the right buttock (a). The papules resolved with residual hyperpigmentation one year after their onset (b).

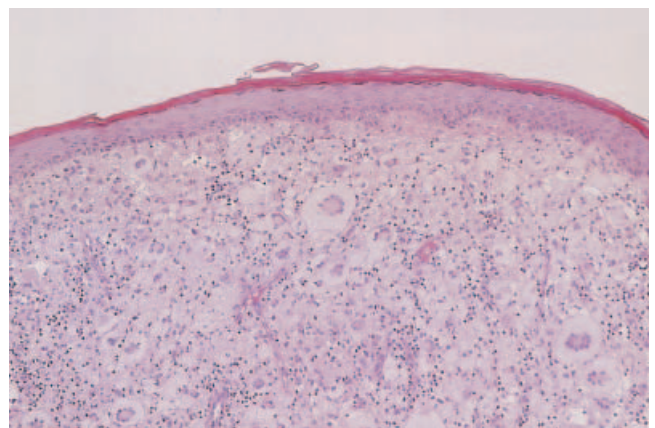


Fig. 2. Infiltration of foamy histiocytes, Touton giant cells and lymphocytes in the dermis. The epidermis is flattened. (H&E; original magnification $\times 100$).

cells were also present. The histological findings of the two biopsied specimens were consistent with xanthogranulomas (1).

In the subsequent 6 months, the patient's skin lesions gradually shrank and flattened. By June 2000, her skin lesions had completely resolved, leaving residual hyperpigmentation and scar-like atrophy, or no trace at all (Fig. 1b). The patient's medications did not change before or during the course of the cutaneous lesions. Repeated laboratory studies including a full blood count, urinalysis, chest X-ray, blood biochemistry and lipid profile were all within normal limits. There was no recurrence of similar lesions in the next two years and the residual hyperpigmentation faded further.

DISCUSSION

Xanthogranulomas occur mainly in infants and children (1, 2), and multiple cutaneous lesions are often present (1, 2). There is no underlying lipid abnormality (1, 2). Spontaneous resolution can usually be seen within a few years (1, 2). Cutaneous xanthogranulomas may rarely be accompanied by similar extracutaneous lesions in other organs (1, 2) and the eyes are the most common extracutaneous site (1, 2). The association of juvenile xanthogranuloma with childhood leukemia has been reported (1, 2). Neurofibromatosis type 1 and urticaria pigmentosa have also been reported to be associated with this disease (3, 4). Both single and multiple cutaneous lesions resolve spontaneously in a few years (1, 2), leaving residual pigmentation, scar-like atrophy, anetoderma-like areas or no trace at all (3). Surgical excision is not necessary, because the natural involution yields satisfactory final results (3).

Xanthogranulomas involve adults to a lesser extent and typically a solitary lesion is present (1, 2). Multiple xanthogranulomas in adults are rare, and as a rule, there is no spontaneous resolution of xanthogranulomas in adults (2, 5). Adult patients with xanthogranulomas have a normal lipid profile and no extracutaneous lesions (2, 5). Because the lesions are usually solitary and totally excised for pathological examination, long-term observation of the natural course of adult lesions cannot be done.

Reviewing the literature, we were able to find 9 cases of adult multiple xanthogranulomas provided with a detailed history (5–11). Though no spontaneous resolution was observed one to several years after the onset of the lesions in 6 cases (5–8), this may be due to a relatively short follow-up period. In the case reported by Davies & Marks (9), there was a slight decrease in the size of many of the lesions 22 months after onset, but further follow-up data were not available. In the case of Nakamura et al. (10), some of the xanthogranulomas disappeared spontaneously in 8 months, but other lesions persisted. Pehr et al. (11) treated a 77-year-old patient with 18 xanthogranulomas with intralesional steroid injections and cryotherapy, and those treated with cryotherapy showed good-to-moderate regression. However, long-term observation of the natural involution of the lesions became impossible after cryotherapy.

Our case should be differentiated from generalized eruptive histiocytomas and papular xanthomas. Generalized eruptive histiocytomas are characterized by many skin-colored to reddish-brown or even bluish papules, but yellowish discoloration is not a feature. Histologically, generalized eruptive histiocytoma can be differentiated from xanthogranuloma by the absence of foamy histiocytes and multinucleate giant cells (12). In papular xanthoma, the lesion is composed entirely of foamy cells and multinucleate giant cells without inflammatory cells, and early lesions are devoid of a non-lipidized histiocytic phase (13). In our case, many lymphocytes and some eosinophils were found histologically, and non-foamy histiocytes could be revealed in the second biopsy specimen taken from a newly onset lesion.

The etiology of xanthogranuloma is unknown, but most researchers believe xanthogranuloma is a reactive granulomatous response of histiocytes to infection (14), physical stimuli (8), or unknown stimuli (15). The spontaneous resolving course in our patient also suggests a reactive process, though we are unable to identify a possible cause.

REFERENCES

1. Caputo R. Juvenile xanthogranuloma. In: Text atlas of histiocytic syndromes. St. Louis: Mosby, 1998: 39–58.
2. Hernandez-Martin A, Baselga E, Drolet BA, Esterly NB. Juvenile xanthogranuloma. *J Am Acad Dermatol* 1997; 36: 355–367.
3. Torok E, Daroczy J. Juvenile xanthogranuloma: an analysis of 45 cases by clinical follow-up, light and electron microscopy. *Acta Derm Venereol* 1985; 65: 167–171.
4. De Villex RL, Limmer BL. Juvenile xanthogranuloma and urticaria pigmentosa. *Arch Dermatol* 1975; 111: 365–366.
5. Rodriguez J, Ackerman AB. Xanthogranuloma in adults. *Arch Dermatol* 1976; 112: 43–44.
6. Malbos S, Guilhou JJ, Meynadier J, Barneon G, Baldet P. Xanthogranuloma in the adult. Report of a case. *Dermatologica* 1979; 158: 334–342.
7. Whitmore SE. Multiple xanthogranulomas in an adult: case report and literature review. *Br J Dermatol* 1992; 127: 177–181.
8. Sueki H, Saito T, Iijima M, Fujisawa R. Adult-onset xanthogranuloma appearing symmetrically on the ear lobes. *J Am Acad Dermatol* 1995; 32: 372–374.
9. Davies MG, Marks R. Multiple xanthogranulomata in an adult. *Br J Dermatol* 1977; 97: 70–72.
10. Nakamura S, Izawa R, Nakayama K, Hoshi K, Onda S. Xanthogranuloma in the adult. *J Dermatol* 1983; 10: 151–156.
11. Pehr K, Elie J, Watters AK. Juvenile xanthogranuloma in a 77-year-old man. *Int J Dermatol* 1994; 33: 438–441.
12. Caputo R, Alessi E, Allegra F. Generalized eruptive histiocytoma. *Arch Dermatol* 1981; 117: 216–221.
13. Bundino S, Zina AM, Aloï F. Papular xanthoma. Clinical, histological and ultrastructural study. *Dermatologica* 1988; 177: 382–385.
14. Balfour HH, Speicher CE, McReynolds DG. Juvenile xanthogranuloma associated with cytomegalovirus infection. *Am J Med* 1971; 50: 380–383.
15. Seo IS, Min KW, Kirkin D. Juvenile xanthogranuloma. *Arch Pathol Lab Med* 1986; 110: 911–915.