

## A Case of Nevoid Acanthosis Nigricans

Mi-Yeon Kim, Ji Sun Lee, Hyung Ok Kim and Young Min Park

Department of Dermatology, Kangnam St. Mary's Hospital, College of Medicine, The Catholic University of Korea, 505 Banpo-Dong, Seocho-Gu, Seoul, 137-040, South Korea. E-mail: [knderma@cmc.cuk.ac.kr](mailto:knderma@cmc.cuk.ac.kr)

Accepted October 6, 2003.

Sir,

Naevoid acanthosis nigricans (AN) is an extremely rare form of AN that can manifest with a characteristic naevoid appearance at any age before puberty (1–3). It is not associated with any known syndrome, endocrinopathy, drugs or internal malignancy (1–3) and, thus far, there have been only 2 case reports in the literature of naevoid AN with a unilateral distribution (1, 2). We report a case of a naevoid AN closely resembling an epidermal naevus occurring on the midline of the abdomen, including the umbilicus, which is an unusual site.

### CASE REPORT

An 18-year-old female presented with dark-brownish pigmented plaques on the midline of the abdomen,

including her umbilicus. At the age of 13, a small-pigmented patch appeared on her abdomen, which slowly increased in size over a 4-year period. At that time, she first noticed a velvety hyperpigmented plaque on her umbilicus. It had remained asymptomatic throughout its course. She was not obese and there was no family history of similar lesions. She had not taken any medication over the previous 5 years and she has a normal menstrual cycle.

An examination demonstrated multiple brownish papules coalescing to form hyperpigmented, verrucous and velvety plaques on the abdomen involving the umbilicus (Fig. 1). There was no similar lesion on intertriginous areas, such as the axillae, neck, external genitalia, groin, inner thighs, antecubital and popliteal fossae or perianal area. No other cutaneous or mucosal lesion was observed.

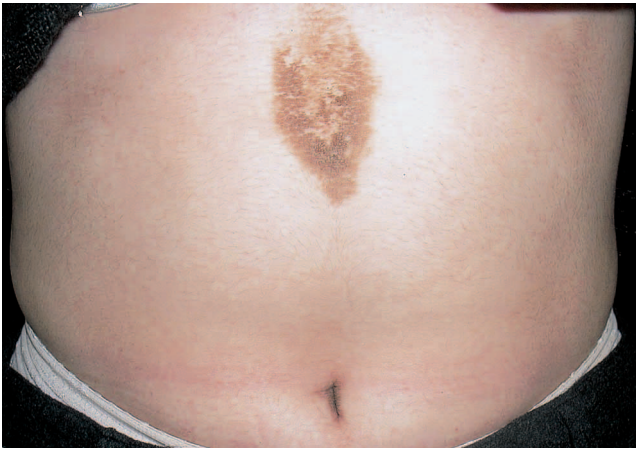

Fig. 1. Naevoid hyperpigmented verrucous velvety plaques on the midline of the abdomen including the umbilicus.

A routine laboratory evaluation, including a full blood count, serum chemistry, urine analysis and plasma glucose level, showed no abnormalities. Endocrine assessment revealed normal GH (1.96 ng/ml, normal, 0.57–4.73 ng/ml), T3 (0.93 ng/ml, normal, 0.78–1.82 ng/ml), T4 (7.59 µg/dl, normal, 4.68–12.48 µg/dl) and TSH (2.85 mU/l, normal, 0.17–4.05 mU/l) levels. Radiographic examination of the skull demonstrated no abnormal findings. A biopsy specimen of the skin lesion revealed hyperkeratosis, papillomatosis and slight acanthosis in the epidermis, and a mild perivascular lymphocytic infiltration in the superficial dermis (Fig. 2). But it also shows a relative lack of acanthosis and greater elongation of the rete ridges compared to epidermal naevi. These findings were interpreted as being most consistent with naevoid AN.

## DISCUSSION

Clinically, AN commonly presents as hyperpigmented, papillomatous, velvety-like plaques in any location, but most typically in the body folds such as the axillae, the back and sides of the neck, the anogenital region, the groin and the umbilicus (3–6). Based on the most common associations, AN is classified into 5 clinical subtypes: insulin resistance-related, malignancy-related, drug-induced, idiopathic and others, which include syndromic, acral and naevoid (4). The histology of AN is consistent regardless of its clinical type. The characteristic features include hyperkeratosis and slight acanthosis undulating with dermal papillomatosis (4).

Naevoid AN is an exceedingly rare true benign form of AN with an irregular autosomal-dominant

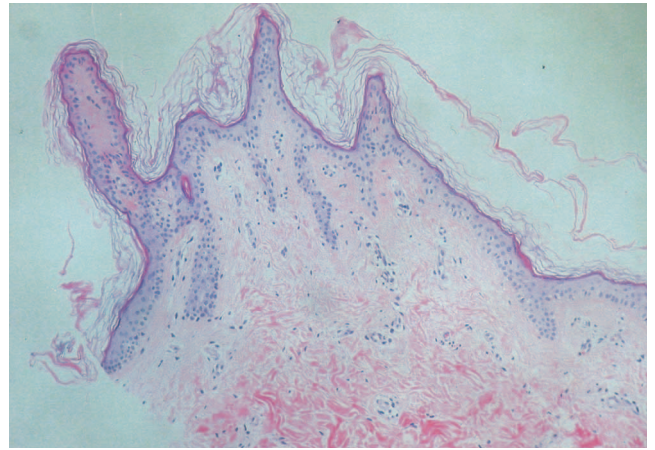


Fig. 2. Hyperkeratosis, slight acanthosis and papillomatosis in the epidermis (H&E, ×100).

inheritance, manifesting at birth, childhood or puberty (1–3). It tends to enlarge for a time and then remains stable or regresses (1–3). Thus far, naevoid AN has been reported as a unilateral presentation, which was called a unilateral AN (1–3). An associated neural element in the pathogenesis of the disease has been suggested.

Our case is unique in that the naevoid AN occurred on the midline of the abdomen, which is an unusual site. Clinically, our case may simulate a hyperpigmented naevus (Becker's, epidermal or melanocytic), a confluent and reticulated papillomatosis (Gougerot-Carteaud syndrome), or a reticulate pigmented flexural anomaly (Dowling-Degos disease).

## REFERENCES

1. Curth HO. Unilateral epidermal nevus resembling acanthosis nigricans. *Br J Dermatol* 1976; 95: 433–436.
2. Krishnam AS. Unilateral nevoid acanthosis nigricans. *Int J Dermatol* 1991; 30: 452–453.
3. Schwartz RA. Acanthosis nigricans. *J Am Acad Dermatol* 1994; 31: 1–19.
4. Houpt KR, Cruz PD, Jr. Acanthosis nigricans. In: Freedberg IM, Eisen AZ, Wolff K, Austen KF, Goldsmith LA, Katz SI, et al., editors. *Dermatology in general medicine*. 5th ed. New York: McGraw-Hill, 1999: 2121–2126.
5. Ebling FJ, Rook A. Disorder of keratinization. In: Rook A, Wilkinson DS, Ebling FJG, editors. *Text book of dermatology*. 3rd ed. Oxford: Blackwell, 1979: 1307–1310.
6. Domonkos AN, Arnold HL, Odom RB. Endocrine diseases, hypertrophies, atrophies and dermal elastosis. In: Odom RB, James WD, Berger TG, editors. *Andrews disease of the skin*. 7th ed. Philadelphia: WB Saunders, 1982: 631–633.