

CLINICAL REPORT

Ichthyosis Follicularis with Alopecia and Photophobia in a Girl with Cataract: Histological and Electron Microscopy Findings

Maria N. TSOLIA¹, Kyriaki ARONI², Ioanna KONSTANTOPOULOU¹, Themistokles KARPATIOS¹, Theano TSOUKATOU¹, Helen PARASKEVAKOU², Christodoulos STAVRINADIS¹ and Andrew FRETZAYAS¹

¹Second Department of Paediatrics, "P. and A. Kyriakou" Children's Hospital and ²Department of Pathology, University of Athens School of Medicine, Athens, Greece

A rare congenital ectodermal disorder characterized by ichthyosis follicularis, alopecia and photophobia has been designated the acronym IFAP. An X-linked recessive mode of inheritance was initially proposed but a few recent reports in girls suggested genetic heterogeneity of this syndrome. We herein describe a 3-year-old girl with clinical and histological features typical of IFAP. In addition to the already known features of the syndrome the patient also developed bilateral cataract. Electron microscopy examination of the skin showed partial disruption of the intercellular bridges, spongiotic changes and decrease in the number and size of desmosomes supporting the notion that IFAP may be a cell-to-cell adhesion disorder.

(Accepted June 23, 2004.)

Acta Derm Venereol 2005; 85: 51–55.

Maria N. Tsolia MD, Second Department of Paediatrics, "P. and A. Kyriakou" Children's Hospital, University of Athens School of Medicine, GR-115 27 Athens, Greece. E-mail: matsolia@ath.forthet.gr

Follicular hyperkeratosis is a constant feature in several dermatologic diseases. The term ichthyosis follicularis was initially coined by Lesser in 1885 to describe the thin, filiform projections protruding from the hair follicles of a patient who also had alopecia. McLeod (1) was the first to define ichthyosis follicularis with alopecia and photophobia (IFAP) as a distinct clinical entity in 1909. Since then a few more cases of this familial ectodermal dysplasia have been reported, most of them gathered during the past decade (2–12). An X-linked recessive mode of inheritance was considered initially but more recently an autosomal pattern was also suggested (4–9). The pathogenesis of this disorder still remains obscure and awaits further clarification as more cases are accumulated.

In this report we describe a girl who had all the clinical features and histological findings of this rare ectodermal dysplasia. Our purpose is to raise concern about the mode of inheritance and to delineate the electron microscopy findings which support the notion that IFAP may be a cell-to-cell adhesion disorder as has already been proposed (8, 9).

CASE REPORT

A 3-year-old girl was referred for further investigation of congenital scalp hypotrichosis in association with severe photophobia initially noticed at the end of the first year of life. The patient was the younger child of healthy non-consanguineous parents and she was born at term after an uneventful pregnancy and delivery. Prenatal exposure to toxic environmental substances, alcohol consumption or drug abuse was not indicated. Birth body measurements were within the established normal range. Her older sister, aged 6 years, was healthy. Photophobia was so severe that at the age of 30 months, due to constant conjunctival injection and corneal irritation, she was treated with contact lenses. Since the first year of life she showed proneness to frequent upper respiratory tract infections. At the age of 2 years she reportedly developed scaly plaques on the extensor aspects of her calves, which disappeared spontaneously after a year without treatment. At that time serum zinc level, determined at a local hospital, was found to be low and she was placed on zinc supplementation for 7 months without improvement of her alopecia.

On physical examination, at the time of initial presentation, her weight, height and head circumference were normal for her age. She had notable hypotrichosis with short hair over the scalp (Fig. 1a). She had marked photophobia and angular cheilitis. An erythematous, erosive, scaly area was noted in the perineum (Fig. 1b). Hyperkeratotic spinous papules involved the scalp, trunk and extremities and gave a thorn-like sensation at palpation. The skin as a whole was dry and harsh as in ichthyosis. Sweat secretion was normal, and no enamel dysplasia of the teeth or nail maldevelopment was seen. Hearing adequacy, psychomotor development and intelligence, properly checked, were normal.

The following laboratory data were within normal limits: complete blood count, liver and renal function tests, electrolytes, zinc level, urinalysis, thyroid function, vitamins A, D and E, immunoglobulin levels, bone age, heart and abdomen ultrasounds. She had normal 46XX karyotype and no abnormal bands were detected by chromosome G-band analysis. Hair examination revealed a short but normal hair. Group A

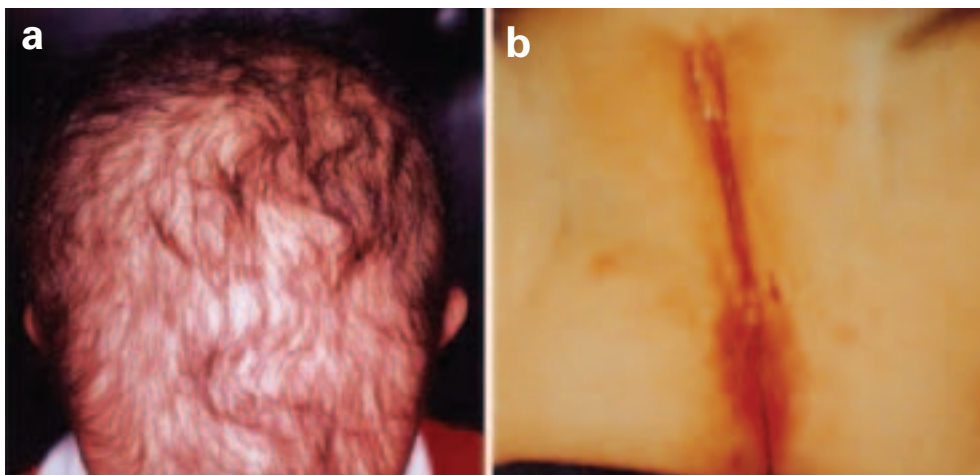


Fig. 1. Patient at the age of 3 years. Appearance of (a) scalp showing moderate hypotrichosis with sparse and short hair and (b) perineum with erythematous, erosive and scaly areas.

streptococcus was cultured from the perineal lesion but, although the infection was eradicated after treatment with cefadroxil, the lesion persisted. The child was evaluated by an ophthalmologist and was noted to have photophobia, reduced eyelashes, follicular hyperkeratosis and peripheral corneal neovascularization.

The patient has been followed for 2 years and her symptoms and signs have remained unchanged, with some exacerbations of scalp hypotrichosis after viral infections. Re-examination by ophthalmologist at the age of 5 revealed the presence of bilateral lamellar cataract. Ophthalmological examination of her parents and sister was normal. During the follow-up she also developed periodontal disease and severe caries requiring primary teeth extractions.

Biopsy specimens from the scalp in serial sections showed keratin plugs occupying dilated hair follicles and hyperkeratosis of the skin in between (Fig. 2a). In the dermis there were few hair follicles and most follicles were in telogen phase. The anagen follicles showed loose

cellular connections and increased intercellular spaces in the lower part and especially in the bulb (Fig. 2b). Sweat glands and a few sebaceous glands were present. A specimen was also obtained from the perineal lesion; it showed focal parakeratosis, spongiosis with vesicle formation, pustules, acanthosis with fusion of rete ridges, diffuse dyskeratotic and few acantholytic cells (Fig. 2c). In the dermis there were inflammatory cells such as lymphocytes and neutrophils also entering the epidermis (epidermotropism).

Tissues taken from the vulva and scalp were fixed in buffered 3% glutaraldehyde and embedded in Epon 8/2. Ultrathin sections were stained with uranyl acetate/lead citrate and examined in a Philips 300 electron microscope. The biopsy from the vulva showed moderate spongiotic changes, which were associated with partial disruption of the intercellular bridges (Fig. 3a). Desmosomes seemed to be decreased in number and size in scalp biopsy and some dyshesion of the cells could also be seen (Fig. 3b).

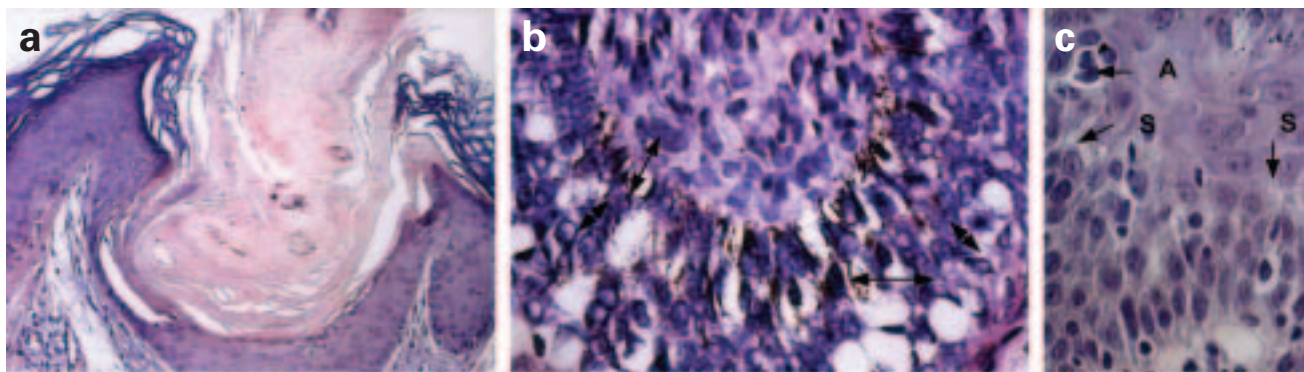


Fig. 2. Histological findings of scalp biopsy showing (a) follicular hyperkeratosis (haematoxylin eosin $\times 100$) and, (b) loose cellular connections and increased intercellular spaces (arrows) in the anagen hair follicle bulb (H&E $\times 400$). The epidermis of the perineal lesion (c) showing spongiosis (arrow S) and acantholysis (arrow A) (H&E $\times 400$).

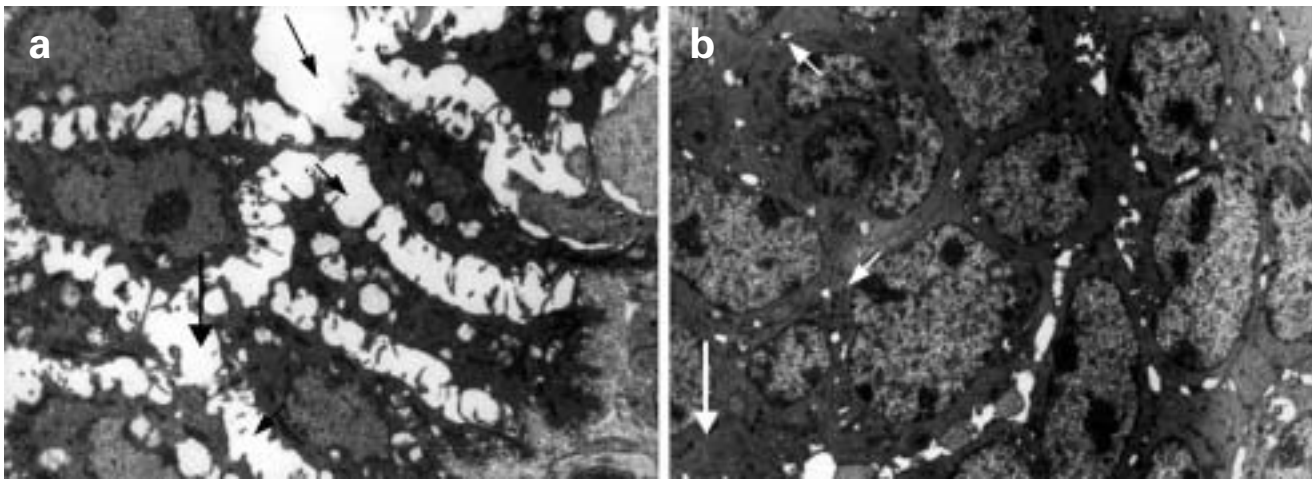


Fig. 3. Electron microscopy examination of (a) perineal lesion showing spongiotic changes and partial disruption of intercellular bridges in the stratum spinosum (arrows) ($\times 35,000$), and (b) lower part of anagen scalp hair follicle showing a decrease in the number and size of desmosomes (arrows) ($\times 20,000$).

DISCUSSION

McLeod's report in 1909 (1) included three brothers with generalized alopecia, photophobia, follicular hyperkeratosis and diffuse skin scaling. Since then, another 14 cases have been reported in the literature and their characteristics are summarized in Table I. In addition to these, one more case was described which shared the characteristics of IFAP and dermatrichic syndrome (13). The main features shared by all patients with IFAP are ichthyosis follicularis, alopecia, and photophobia. Alopecia is not associated with inflammation and scarring and in most cases it is complete in the scalp. Eyebrows and eyelashes are also involved in most reports. Common additional manifestations of the syndrome include corneal abnormalities causing the photophobia, hyperkeratotic plaques mainly in the extensor aspects of the extremities, cheilitis, scaling, skin erythema, onychodystrophy and recurrent respiratory and skin infections. Teeth and sweating were normal in all cases. Hearing was also normal in all but one patient (4). In addition to these manifestations some patients have mental retardation, seizures and failure to thrive (Table I).

The patient described in this report presented with ichthyosis follicularis, hypotrichosis, photophobia associated with corneal neovascularization, angular cheilitis, diffusely dry skin, an erosive scaly area in the perineum and reported hyperkeratotic plaques in the extensor aspects of the extremities. She also had frequent upper respiratory tract infections and later developed severe caries. This constellation of clinical symptoms and findings strongly suggests that the girl represents a typical but mild case of IFAP syndrome. She did not have atrichia but rather moderate hypotrichosis with exacerbations and periods of spontaneous improvement, and her growth and development were normal.

Although most patients reported with this syndrome had atrichia, some of them had hypotrichosis with sparse, atrophic, remaining hair (2, 4, 12). The erythematous, hyperkeratotic perineal lesion closely resembles those described in three of six cases previously reported in female patients (4, 9). Cataract is not known to be a feature of IFAP and our patient is the first among all reported cases to have this manifestation. Cataract has been described in patients with different ectodermal dysplasias, some of which share certain features with IFAP (14, 15).

The histological findings in this patient support the clinical diagnosis of IFAP. They were identical to those described in previous cases and include acanthosis, follicular hyperkeratosis, parakeratosis, cell dyshesion with spongiotic changes, abortive hair follicles and non-specific inflammatory cell infiltration in the dermis. Sweat and a few sebaceous glands were present. Sebaceous glands were absent in the initial reports of the syndrome, leading Zeligman & Fleisher to suggest that IFAP is a disorder of the pilosebaceous system (1-3); however, no comment was made about their existence in other cases in which a histological examination was performed (4, 5, 7, 8, 9).

Our patient is the second case in the literature for whom results of electron microscopy examination of the skin are reported. Decrease in the number of desmosomes, disruption of intercellular bridges and spongiotic changes were the main findings and are identical with those found after examination of the psoriasiform eruptions of another female patient (9). In a third male patient examination of the cornea with electron microscopy also revealed reduced number of desmosomes in the corneal epithelium, dispersed bundles of tonofilaments and dilated intercellular gaps with segregated desmosome remnants. These findings closely resemble those of hereditary mucoepithelial dysplasia syndrome

Table 1. Characteristics of patients described with IFAP syndrome, all having follicular keratosis and photophobia^a

Ref. no.	Case	Age (years)	Sex	Alopecia	Cornea	Cheilitis	Hyperkeratotic plaques	Nails	Infections	Additional findings	Proposed inheritance
1	1	10	M	Complete	-	-	+	Normal	-	-	X-linked
	2*	13	M	Complete	-	-	-	Normal	-	-	-
	3*	19	M	Complete	-	-	-	Normal	-	-	-
2	4	8	M	Complete	-	-	-	Dystrophic	Liver ^b	MR	-
	5	3.5	M	Partial	-	-	-	Normal	-	-	-
3	6	4.5	M	Complete	Keratitis vascular	-	-	Normal	Respiratory	MR, febrile seizures, FTT, MR	-
	7	5	M	Complete	Erosions	-	+	Normal	-	-	-
4	8	3	F	Partial	Scarring	+	+	Dystrophic	Skin	-	AD
	9	4	F	Partial	NE	+	+	Dystrophic	-	-	-
5	10	1.5	M	Complete	Keratitis, vascular	-	-	Dystrophic	Respiratory	MR, febrile seizures, FTT	-
6	11	1	M	Complete	Astigmatism	-	-	Onychoschizia	Skin	-	X-linked
7, 8	12	0-33	M	Complete	Scarring	-	-	-	Respiratory (died of)	MR, seizures, FTT	-
9	13**	5-26	F	Complete	Vascular, opacity	+	+	Deformed	Skin	-	AD
	14**	0	F	Complete	NE	+	+	Deformed	-	-	AD
10, 11	15	3.5	M	Complete	Vascular	+	+	Dystrophic	Respiratory, skin	MR, febrile seizures, FTT	X-linked
12	16	0-5	F	Partial	Vascular, opacity	+	-	Normal	-	-	-
	17	0-6	F	Partial	Erosions	-	-	Normal	-	-	-
This report	18	3	F	Partial	Vascular	+	+	Normal	-	-	-

M, male; F, female; NE, not evaluated; AD, autosomal dominant; MR, mental retardation; FTT, failure to thrive.

^aTeeth and sweating were normal in all patients; hearing was affected in patient 8.

^bAmoebic liver abscess caused death.

*Siblings.

**Mother and daughter.

and support the notion that IFAP may also be a disorder of desmosome and gap junction formation (9, 16).

Ectodermal dysplasia skin fragility syndrome is a recently described desmosomal disorder characterized by complete absence of the desmosomal protein plakophilin I (17). Patients with this syndrome have alopecia, thickened dystrophic nails and skin fragility with trauma-induced blistering leading to skin cracking. Hyperkeratosis of the palms and soles is a prominent feature of this syndrome but was absent in our patient. Skin fragility-woolly hair syndrome is another desmosomal disorder characterized by alopecia with woolly hair, palmoplantar keratoderma and hyperkeratotic plaques on the trunk and limbs. Complete absence of desmosomal protein desmoplakin has been shown by immunohistochemistry in patients with this syndrome (18). Our patient had hypotrichosis and transient hyperkeratotic plaques in the limbs but she did not have the characteristic woolly hair and palmoplantar keratoderma.

The first patients reported with IFAP were males and an X-linked recessive mode of inheritance was suggested (1). The documentation of linear lesions reflecting lyonization in heterozygous women supported this hypothesis (6). However, in recent reports, six cases were described in females – suggesting autosomal inheritance or genetic heterogeneity of the syndrome (4, 9, 12). Our patient's family history was unremarkable and examination of other family members was not contributory, suggesting that the manifestation of IFAP in this case most likely resulted from a new mutation.

In conclusion, the present case raises concern regarding the mode of inheritance of IFAP syndrome, supports the notion that IFAP may be a cell-to-cell adhesion disorder and calls for the accumulation of new cases in order to delineate the exact pathogenesis of this disorder.

REFERENCES

- McLeod JMH. Three cases of "ichthyosis follicularis" associated with baldness. *Br J Dermatol* 1909; 21: 165–189.
- Zeligman I, Fleisher T. Ichthyosis follicularis. *Arch Dermatol* 1959; 80: 312–320.
- Eramo LR, Esterly NB, Zieserl EJ, Stock EL, Herrmann J. Ichthyosis follicularis with alopecia and photophobia. *Arch Dermatol* 1985; 121: 1167–1174.
- Rothe MJ, Weiss DS, Dubner BH, Wetzneir JM, Lucky AW, Schachner L. Ichthyosis follicularis in two girls: an autosomal dominant disorder. *Pediatr Dermatol* 1990; 7: 287–292.
- Hamm H, Meinecke P, Traupe H. Further delineation of the ichthyosis follicularis, atrichia, and photophobia syndrome. *Eur J Pediatr* 1991; 150: 627–629.
- Konig A, Happle R. Linear lesions reflecting lyonization in women heterozygous for IFAP syndrome (Ichthyosis Follicularis with Atrichia and Photophobia). *Am J Med Genet* 1999; 85: 365–368.
- Cursiefen C, Schlotzer-Schrehardt U, Holbach LM, Pfeiffer RA, Naumann GOH. Ocular findings in Ichthyosis Follicularis, Atrichia and Photophobia syndrome. *Arch Ophthalmol* 1999; 117: 681–684.
- Keyvani K, Paulus W, Traupe H, Kiesewetter F, Cursiefen C, Huk W, et al. Ichthyosis follicularis, alopecia, and photophobia (IFAP) syndrome: clinical and neuropathological observations in a 33-year-old male. *Am J Med Genet* 1998; 78: 371–377.
- Sato-Matsumura KC, Matsumura T, Kumakiri M, Hosokawa K, Nakamura H, Kobayashi H, et al. Ichthyosis Follicularis with Atrichia and Photophobia in a mother and daughter. *Br J Dermatol* 2000; 142: 157–162.
- Boente M, Bibas-Bonet H, Coronel AM, Asial RA. Atrichia, ichthyosis, follicular hyperkeratosis, chronic candidiasis, keratitis, seizures, mental retardation and inguinal hernia: a severe manifestation of IFAP syndrome? *Eur J Dermatol* 2000; 10: 98–102.
- Bibas-Bonet H, Fauze R, Boente MC, Coronel AM, Asial R. IFAP syndrome "plus" seizures, mental retardation, and callosal hypoplasia. *Pediatr Neurol* 2001; 24: 228–231.
- Cambiaghi S, Barbareschi M, Tadini G. Ichthyosis follicularis with atrichia and photophobia (IFAP) syndrome in two unrelated female patients. *J Am Acad Dermatol* 2002; 46: S156–S158.
- Martino F, D'Eufemia P, Pergola MS, Finocchiaro R, Celli M, Giampa A, et al. Child with manifestations of dermatotrichic syndrome and ichthyosis follicularis alopecia-photophobia (IFAP) syndrome. *Am J Med Genet* 1992; 44: 233–236.
- Appell ML, Shererzt EF. A kindred with alopecia, keratosis pilaris, cataracts and psoriasis. *J Am Acad Dermatol* 1987; 16: 89–95.
- Wallis C, Ip FS, Beigton P. Cataracts, alopecia, and sclerodactyly: a previously apparently undescribed ectodermal dysplasia syndrome on the island of Rodrigues. *Am J Med Genet* 1989; 32: 500–503.
- Witkop CJ Jr, White JG, King RA, Dahl MV, Young WG, Sauk JJ Jr. Hereditary mucoepithelial dysplasia: a disease apparently of desmosome and gap junction formation. *Am J Hum Genet* 1979; 31: 414–427.
- McGrath JA, McMillan JR, Shemanko CS, Runswick SK, Leigh IM, Lane EB, et al. Mutations in the plakophilin 1 gene result in ectodermal dysplasia/skin fragility syndrome. *Nature Genet* 1997; 17: 240–244.
- Whitlock NV, Wan H, Morley SM, Garzon MC, Kristal L, Hyde P, et al. Compound heterozygosity for non-sense mutations in desmoplakin underlies skin fragility/woolly hair syndrome. *J Invest Dermatol* 2002; 118: 232–238.