

Facial Erythema Alone as a Manifestation of Chronic Graft-versus-host Disease

Hiroo Hata, Daisuke Sawamura*, Akihiko Shibaki and Hiroshi Shimizu

Department of Dermatology, Hokkaido University Graduate School of Medicine, N15 W7, Sapporo, 060-8638, Japan.

*E-mail: smartdai@med.hokudai.ac.jp

Accepted November 19, 2003.

Sir,

Graft-versus-host disease (GVHD) is a complex multi-system disorder that occurs in an immunocompromised host who is the recipient of histo-incompatible lymphocytes (1). Recent increases in transplantation procedures require careful follow-up of patients by dermatologists, as the skin is the earliest and most frequent target in GVHD. We report a case of chronic GVHD who exhibited only facial eruptions after allogeneic peripheral blood stem cell transplantation (PBSCT) with reduced-intensity conditioning (RIC).

CASE REPORT

A 53-year-old man with a 3-year history of acute promyelocytic leukaemia received allogeneic PBSCT with RIC from an HLA-matched brother. The RIC regime comprised fludarabine (30 mg/m²) on days -8 to -3 and busulfan (4 mg/kg) on days -6 to -5, followed by the PBSCT procedure on day 0. After transplantation, 100 mg of cyclosporine was given as the sole immunosuppressive agent. Acute GVHD did not appear during the first 3 months, and then cyclosporine was stopped. Approximately 200 days after PBSCT, an eruption developed on his face.

Examination revealed infiltrated, slightly pigmented erythema that caused slight itching (Fig. 1, top). There were no eruptions elsewhere on the body. Laboratory findings showed liver dysfunction with γ -GTP of 165 U/l and LDH of 649 U/l. Antinuclear antibodies were negative. A skin biopsy of the facial lesion showed slight liquefaction degeneration and dermal lymphocytic infiltration, which was much stronger below the midpoint of the hair follicle just outside the hair bulb, probably corresponding to the bulge area (Fig. 1, bottom). Fibrinoid material and mucin deposition were found in some areas of the dermis. There was little or no infiltration around the eccrine sweat glands.

On a clinical basis, the differential diagnoses for chronic GVHD included lupus erythematosus and drug eruptions. However, at that time there were no potential drugs that might have caused a drug eruption, and laboratory data showed negative antinuclear antibodies. Histology showed lymphocytic infiltration into the hair bulge region consistent with the typical features of GVHD (2). Thus, we made the diagnosis of chronic GVHD based on the above findings and the patient was given oral prednisolone at a dose of 60 mg/day. Subsequently the facial erythema reduced in intensity,

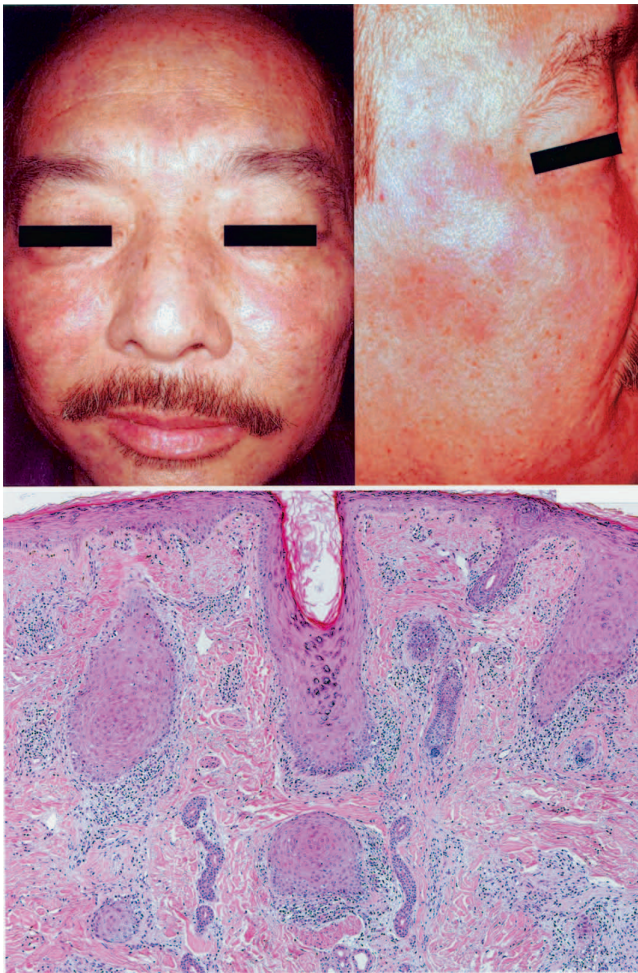


Fig. 1. Clinical and histological findings. *Top:* Infiltrated, slightly pigmented erythema with minimal itching was found on the face. *Bottom:* Mild liquefaction degeneration and mild lymphocytic infiltration were observed in the upper dermis. The lymphocytic infiltration was much stronger below the midpoint of the hair follicle and outside the hair bulb, most likely corresponding to the bulge area. There was little or no lymphocytic infiltration around the eccrine glands.

leaving only slight pigmentation, and his liver function returned to normal within 3 weeks.

DISCUSSION

Chronic GVHD induces manifestations that usually develop 3 months after the transplantation procedure (1). The facial erythema in our patient was diagnosed as a chronic form of GVHD because it appeared 200 days

after transplantation. As far as we know, only two cases of chronic GVHD that presented as facial erythema alone have been reported (3). The manifestation of GVHD may be modulated by new types of immunosuppressive agents and new therapeutic protocols. RIC allografts, using non-myeloablative conditioning, have recently been undertaken for a variety of haematological malignancies (4). This procedure has a lower mortality rate, but the potential disadvantage is less antitumour effectiveness. In addition, RIC allografts have been associated with less acute and chronic GVHD (5). The increasing use of RIC allografts may yield new forms of cutaneous GVHD including the facial erythema found in the present case.

Chronic GVHD is well known to have clinical and pathological similarities to autoimmune diseases. As this case actually only showed facial erythema, we could not easily rule out lupus erythematosus even in combination with histological findings. Although liquefaction degeneration and fibrinoid material and mucin depositions were consistent with lupus erythematosus, lymphocytic infiltration in hair bulges, not in the eccrine glands, was suggestive of GVHD (2). These are important histological findings, suggesting GVHD in such cases.

REFERENCES

1. Aractingi S, Chosidow O. Cutaneous graft-versus-host disease. *Arch Dermatol* 1998; 134: 602–612.
2. Sale GE, Beauchamp MD, Akiyama M. Para-follicular bulges, but not hair bulb keratinocytes, are attacked in graft-versus-host disease of human skin. *Bone Marrow Transplant* 1994; 14: 411–413.
3. Tokura Y, Yagi H, Iwasaki K, Takigawa M. Facial erythema and pigmentation as an initial manifestation of chronic graft-versus-host disease. *J Dermatol* 1994; 21: 185–188.
4. Giralt S, Thall PF, Khouri I, Wang X, Braunschweig I, Ippolitti C, et al. Melphalan and purine analog-containing preparative regimens: reduced-intensity conditioning for patients with hematologic malignancies undergoing allogeneic progenitor cell transplantation. *Blood* 2001; 97: 631–637.
5. Parker JE, Shafi T, Pagliuca A, Mijovic A, Devereux S, Potter M, et al. Allogeneic stem cell transplantation in the myelodysplastic syndromes: interim results of outcome following reduced-intensity conditioning compared with standard preparative regimens. *Br J Haematol* 2002; 119: 144–154.