

## Nerve Involvement in Indian Post Kala-Azar Dermal Leishmaniasis

Sujay Khandpur<sup>1</sup>, M. Ramam<sup>1</sup>, Vinod K. Sharma<sup>1</sup>, Poonam Salotra<sup>2</sup>, Manoj K. Singh<sup>3</sup> and Amit Malhotra<sup>1</sup>

Departments of <sup>1</sup>Dermatology & Venereology and <sup>3</sup>Pathology, All India Institute of Medical Sciences, New Delhi and <sup>2</sup>Molecular Biology Laboratory, Institute of Pathology (ICMR), Safdarjung Hospital Campus, New Delhi, India.

E-mail: shaifalikhandpur@eth.net

Accepted November 17, 2003.

Sir,

Post kala-azar dermal leishmaniasis (PKDL) is a well-recognized sequel of kala-azar in India, developing in approximately 20% cases after a variable time interval of 1–5 years (1). The disease occurs chiefly in the eastern parts of India, an area that also has a high prevalence of leprosy. PKDL manifests as symmetrically distributed hypopigmented macules, papules, infiltrated plaques and nodules, that bear a close resemblance to leprosy, with which it is often confused. Clinical and pathological features to differentiate the two diseases have been described (2).

Nerve inflammation on skin biopsy is considered a diagnostic feature of leprosy. We describe a case of Indian PKDL with lesional nerve infiltration, histologically mimicking tuberculoid leprosy. The diagnosis of PKDL was confirmed by serological and gene amplification techniques. Nerve involvement has been reported in the Sudanese variety of PKDL (3). As far as ascertained, this feature has not been previously reported in Indian PKDL.

### CASE REPORT

A 25-year-old migrant labourer from Bihar presented with widespread, asymptomatic macular and papular lesions of 2 years duration. It was not associated with tingling, numbness or paraesthesia, fever or constitutional symptoms. He had kala-azar 10 years ago and was treated with 24 intramuscular injections of sodium antimony stibogluconate, with complete cure.

Dermatological examination revealed multiple, discrete and coalescent, symmetrically distributed hypopigmented macules and papules, distributed on the face including ear lobes, the trunk and extremities (Fig. 1). There was no lesional or glove and stocking anaesthesia or peripheral nerve enlargement. Mucous membranes were spared. Examination of the abdomen, cardiovascular and central nervous systems revealed no abnormality.

The haematological and biochemical investigations were normal. Focal calcifications in the spleen were observed on ultrasonography of the abdomen, suggestive of previous kala-azar. Slit skin smears from the papular lesions stained with Giemsa, acridine orange and Ziehl Neelsen stains failed to demonstrate Leishman-Donovan (LD) bodies or acid-fast bacilli. A skin biopsy obtained from a papule, revealed a superficial and deep dermal, moderately dense,

granulomatous infiltrate composed of epithelioid cells and lymphocytes around the blood vessels, appendages and nerve twigs. There were no plasma cells or macrophages; LD bodies could not be demonstrated. On S-100 staining, fibrillar structures, suggestive of nerve twigs, could be identified within the granulomas (Fig. 2). The histopathological features were suggestive of tuberculoid leprosy. Enzyme-linked immunosorbent assay (ELISA) for PKDL and a strip test based on recombinant K39 antigen (4) were positive. A 600-bp fragment of the *Leishmania donovani*-specific kinetoplast mini-circle DNA was amplified from the skin sample by polymerase chain reaction (PCR) (5).

The diagnosis of PKDL was confirmed by serological and DNA amplification procedures. However, the patient refused therapy, as he had to go back to his village for financial reasons.

### DISCUSSION

The remarkable clinical similarity between PKDL and leprosy is well known. The differentiating features include predilection of PKDL lesions for the centrofacial region, absence of neurological deficit both clinically and histologically and demonstration of LD bodies in slit skin smears or histological sections. However, in various series on PKDL reported from different parts of the world, the parasite could be demonstrated by slit smears in only 20–66.6% of lesions and on histopathology, the detection rate was sometimes as low as 20% (6, 7). Under such circumstances, establishing the diagnosis of PKDL and

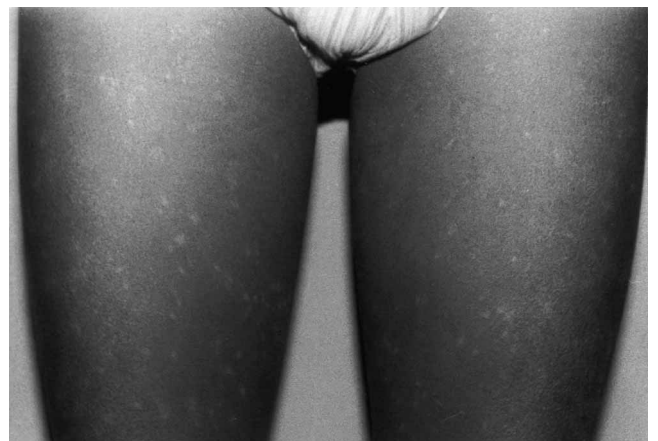

Fig. 1. Symmetrically distributed hypopigmented macules and papules over lower limbs.

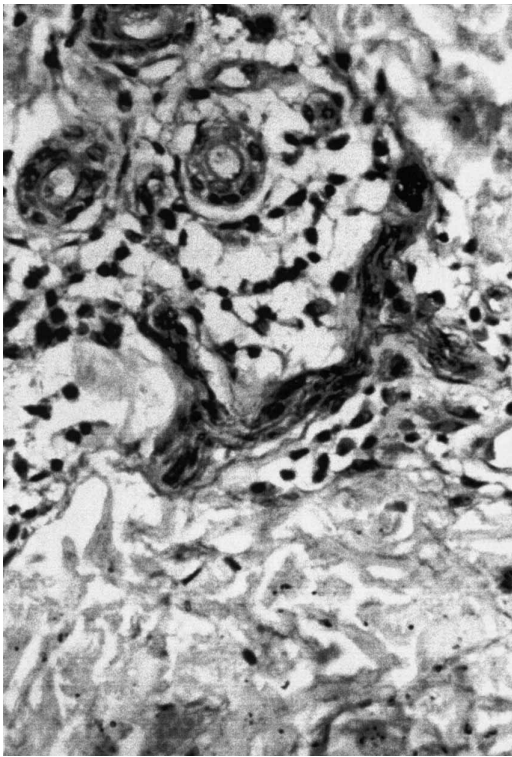


Fig. 2. Photomicrograph showing granulomatous infiltrate around S-100 positive nerve fibres in the papillary dermis (S-100 stain  $\times 40$ ).

differentiating it from leprosy becomes even more difficult.

Lesional or peripheral nerve involvement with consequent sensory loss is considered diagnostic of leprosy. Similarly, the demonstration of inflammation in and around the nerves on skin biopsy is considered to be highly suggestive of leprosy. Rarely this finding has been reported in other diseases including cutaneous leishmaniasis and Sudanese PKDL (3, 8). In a study to determine the utility of the S-100 stain to detect nerve twigs within granulomas as a diagnostic aid in leprosy, Singh et al. (9) observed S-100-positive nerve fibres within and in between the granulomas in many non-leprosy granulomatous dermatoses including necrobiosis lipoidica, cutaneous leishmaniasis, secondary syphilis, lupus vulgaris, granuloma annulare, deep mycoses and donovanosis. They proposed that tuberculoid leprosy could be histologically differentiated from other granulomatous diseases by the demonstration of two reaction patterns; either complete absence of nerve fibres or their presence only within the granulomas and not in between them.

Nerve involvement in PKDL has so far been reported in four cases from Sudan (3). In these patients, the disease developed 1–6 months after apparently successful treatment of kala-azar, with clinical evidence of generalized depigmented macules, papules and nodules, preferentially localized to the face.

In two patients, histopathology revealed a pleomorphic infiltrate comprising parasitized macrophages, lymphocytes and plasma cells in the papillary dermis and mononuclear cells containing LD bodies around the nerves. In the other two cases, well organized epithelioid cell granulomas with Langhans' giant cells and lymphocytes were identified both in the papillary dermis and around the nerves, with disorganization and hypertrophy of the Schwann cells. The histological picture in our patient was quite similar to the latter two Sudanese cases. S-100 staining allowed easy recognition of the nerve twigs within the granulomatous infiltrate. Although the histology raised the possibility of tuberculoid leprosy occurring concomitantly with PKDL, this appears unlikely because the patient did not have a large, well- to ill-defined, dry, scaly hypoaesthetic lesion of tuberculoid leprosy. In fact, skin biopsy was obtained from a small papule that showed no sensory loss, clinically suggestive of PKDL. PKDL was confirmed by sophisticated diagnostic modalities such as PCR, strip test and ELISA. The species-specific PCR assay used in our study has been shown to be 93.8% sensitive and 100% specific for PKDL (5). Similarly the strip test has a sensitivity and specificity of 91% and 100%, respectively (4).

## REFERENCES

1. Mukherjee A, Ramesh V, Misra RS. Post-kala-azar dermal leishmaniasis: a light and electron microscopic study of 18 cases. *J Cutan Pathol* 1993; 20: 320–325.
2. Kubba R, Al-Gindan Y. Leishmaniasis. *Dermatol Clin* 1989; 7: 331.
3. El Hassan AM, Ali MS, Zijlstra E, Eltoum IA, Ghalib HW, Ahmed HMA. Post-kala-azar dermal leishmaniasis in the Sudan: peripheral neural involvement. *Int J Dermatol* 1992; 31: 400–403.
4. Salotra P, Sreenivas G, Ramesh V, Sundar S. A simple and sensitive test for field diagnosis of post kala-azar dermal leishmaniasis. *Br J Dermatol* 2001; 145: 630–632.
5. Salotra P, Sreenivas G, Pogue GP, Lee N, Nakhasi HL, Ramesh V, et al. Development of a species-specific PCR assay for detection of *Leishmania donovani* in clinical samples from patients with kala-azar and post kala-azar dermal leishmaniasis. *J Clin Microbiol* 2001; 39: 849–854.
6. Zijlstra EE, Khalil EAG, Kager PA, El Hassan AM. Post kala-azar dermal leishmaniasis in the Sudan: clinical presentation and differential diagnosis. *Br J Dermatol* 2000; 143: 136–143.
7. Sharma MC, Gupta AK, Verma N, Das VNR, Saran R, Kar SK. Demonstration of leishmania parasites in skin lesions of Indian post kala-azar dermal leishmaniasis cases. *J Commun Dis* 2000; 32: 67–68.
8. Kubba R, El-Hassan AM, Al-Gindan Y, Omer AH, Busra M, Kutty MK. Peripheral nerve involvement in cutaneous leishmaniasis (Old World). *Int J Dermatol* 1987; 26: 527–531.
9. Singh N, Arora VK, Ramam M, Tickoo SK, Bhatia A. An evaluation of the S-100 stain in the histological diagnosis of tuberculoid leprosy and other granulomatous dermatoses. *Int J Leprosy* 1994; 62: 263–267.