

Fluorouracil Does Not Improve the Outcome of Imiquimod Treatment of Vulval Intraepithelial Neoplasia

Anthony M. R. Downs¹, John M. Geraghty² and Cheryl Jones²

¹Department of Dermatology, Royal Devon & Exeter Hospitals, Exeter EX2 5DW and ²Department of Dermatology & Pathology, Musgrove Park Hospital, Taunton TA1 5DA, UK. E-mail: amr.downs@btinternet.com

Accepted December 6, 2004.

Sir,

Vulval intraepithelial neoplasia (VIN) is a form of squamous cell carcinoma (SCC) in situ. The condition presents as smooth or warty plaques on the vulva which are either erythematous or white in colour. The lesions can be asymptomatic or cause pruritus, vulval pain or sexual dysfunction. The disease is often multi-focal and almost always associated with human papilloma virus (HPV) type 16 (1). The incidence of VIN is rising (2), and it is becoming a therapeutic challenge because it is more resistant to standard treatments that cure most forms of cutaneous SCC in situ (Bowen's disease). An association with oncogenic HPV types (e.g. 16 and 18) may explain this difference (3). VIN is segregated into three types (I–III) reflecting an increasing progression of trans-epidermal dysplasia. Severe VIN (III) is premalignant, but a transformation to SCC can take many years. In contrast, VIN I is much easier to treat, but recurrences still occur in all three types. In one retrospective study of 23 genital SCCs in women, 2 were associated with VIN III; however, the majority were associated with chronic lichen sclerosis et atrophicans or lichen planus (4).

Standard VIN treatments include 5-fluorouracil (5-FU) cream, photodynamic therapy, CO₂ laser ablation, cryotherapy and excision. Wide surgical excision – the gold standard treatment – is often complex, disfiguring and expensive (5), but despite this, surgical margins are often positive and high recurrence rates are common. One prospective study of VIN III showed a recurrence rate of 46% post-excision with positive histological margins and a 17% post-excision recurrence with negative histological margins at 7 months follow-up (6). Imiquimod (IMD) 5% cream has been used as a single treatment agent in four published studies and one case report (7–11) (Table I). The most favourable study showed that eight patients with VIN II or III (61%) had a complete regression (9). IMD enhances the development of protective innate antiviral and anti-tumour responses. It induces the local production of interferon- α and tumour necrosis factor and 2'5-oligoadenylate synthetase that confers antiviral protection and it stimulates natural killer cell activity (3, 12). 5-FU targets thymidylate synthase in tumour cells. Its selectivity for neoplastic and dysplastic cells relies upon increased DNA and RNA incorporation of 5-FU by the target cells (13).

In this prospective open study we assessed the efficacy of initial treatment with IMD cream followed by 5-FU

cream. Any residual VIN or SCC not eliminated by IMD should be targeted by the 5-FU cream. Cure rates were anticipated to be higher than those previously published, where IMD was used alone.

METHODOLOGY

Eight women with biopsy-proven VIN (I–III) were enrolled. Detailed diagrams and measurements documented the visual extent of the vulval problem prior to treatment and were reviewed with the patient on follow-up. IMD cream (Aldara[®], 3M Healthcare, Loughborough, UK) was applied three times a week for 16 weeks followed by 5-FU cream (Efudix[®], ICN Pharmaceuticals, Basingstoke, UK) applied daily for 4 weeks, to all of the vulva. If the vulva became too sore, the women were told to discontinue treatment cream application for 1 week then restart, but being sure to add an extra week onto the treatment schedule. Patients were encouraged to contact the dermatology department if they were concerned about any symptoms or soreness. Follow-up biopsies were taken 1 month after the end of the treatment schedule.

RESULTS

All patients were symptom-free prior to initiating treatment, but they had varying degrees of discomfort whilst using IMD cream. However, only one patient contacted the department because of discomfort during treatment (Table II). That patient took a 1-week treatment break on our advice because of soreness. All patients reported redness and soreness of the vulva, which was not confined to the area of their vulva that had been biopsied. Patients were not, however, visually inspected during the 16 weeks of IMD application. At the end of the 16 weeks, all patients were asymptomatic. No patient complained of discomfort whilst using 5-FU

Table I. Previous studies treating vulval intraepithelial neoplasia (VIN) with imiquimod cream alone

Ref.	Treatment schedule	Pre-treatment histology (VIN)	Outcome (n) cure improved	
10	Three times per week for 16 weeks (n=15)	All III	3	1
8	One to three times per week for 6–34 weeks (n=15)	II and III	4	9
9	Three times per week for 4–32 weeks (n=13)	II and III	8	2
7	For 4–16 weeks (n=4)	I and III	1	3

Table II. Results of imiquimoid cream followed by 5-fluorouracil cream to treat vulvar intraepithelial neoplasia (VIN)

Patient no.	Pre-treatment		Clinical outcome
	histology (clinical appearance)	Post-treatment histology	
1	VIN I (SP)	Clear	Clear
2	VIN I (SP)	Clear	Clear
3	VIN II (SP)	Clear	Clear
4	VIN II (MD)	Clear	Clear
5	VIN II (MD)	Clear	Clear
6	VIN II (MD)	VIN I	Reduced size, SP
7	VIN II (SP)	VIN II	Reduced size, SP
8	VIN III (SP)	VIN II	Reduced size, SP

SP, solitary plaque; MD, multifocal disease.

cream. All pre-treatment biopsies showed histological evidence compatible with HPV co-infection. Fig. 1 shows the pre- and post-treatment histology from patient 1.

Three of the six patients with VIN II or III (50%) and 6 of 8 with VIN I–III had histological clearance on post-treatment biopsies. The other three patients had a reduction in the extent of their lesions compared with their pre-treatment visual assessments. They subsequently underwent local surgical excision with clear surgical margins. Surgery was simpler than that anticipated prior to topical treatment. These patients had simple excision and direct closure of residual single plaques. All patients have remained disease-free for 8–24 months (mean 14). The location of the lesions, the visible extent or the presence of more than one affected site did not relate to the clearances observed.

DISCUSSION

The sequential treatment with both creams did not improve VIN cures compared to that which has been reported previously with IMD cream alone in other studies. In the three partially responsive cases with persistent histological evidence of post-treatment VIN,

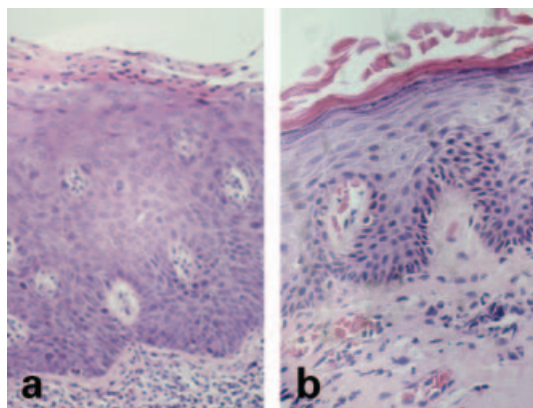


Fig. 1. Vulvar histology of patient 1 showing VIN I pre-treatment (a) and normal vulvar tissue post-treatment ($\times 200$ magnification) (b).

we would have expected these patients to have experienced discomfort with 5-FU cream application. The marked inflammation caused by IMD around the dysplastic cells might interfere with the preferential uptake of 5-FU by the dysplastic cells. 5-FU might therefore fail to reach its target sites – DNA and RNA within the dysplastic cells. Pre-treatment of VIN lesions with IMD will cure well over half of the cases identified and therefore avoid potentially difficult and disfiguring surgery. We conclude that the treatment is well tolerated given that only one patient complained of sufficient soreness to contact us during treatment. However, vulval soreness and discomfort outside a histologically confirmed area of VIN might suggest that subclinical disease around the solitary plaque of VIN or multifocal was being revealed by IMD application. These lesions can be reduced in size so making surgery simpler. Subclinical or multi-focal disease may be captured with IMD cream treatment, meaning that close excision margins should be more acceptable. This study contributes to the gathering evidence that IMD is an appropriate first-line treatment for VIN.

REFERENCES

- van Beurden M, ten Kate FJ, Smits HL, Berkhout RJ, de Craen AJ, van der Vange N, et al. Multifocal vulvar intraepithelial neoplasia grade III and multicentric lower genital tract neoplasia is associated with transcriptionally active human papillomavirus. *Cancer* 1995; 75: 2879–2884.
- Joura EA, Losch A, Haider-Angeler MG, Breitenacker G, Leodolter S. Trends in vulvar neoplasia: increasing incidence of vulvar neoplasia and squamous cell carcinoma of the vulva in young women. *J Reprod Med* 2000; 45: 613–615.
- Mackenzie-Wood A, Kossard S, de Launey J, Wilkinson B, Owens ML. Imiquimod 5% cream in the treatment of Bowen's disease. *J Am Acad Dermatol* 2001; 44: 462–470.
- Derrick EK, Ridley CM, Kobza-Black A, McKee PH, Neill SM. A clinical study of 23 cases of female anogenital carcinoma. *Br J Dermatol* 2000; 143: 1217–1223.
- Shafi MI, Luesley DM, Byrne P, Samra JS, Redman CW, Jordan JA, et al. Vulvar intraepithelial neoplasia: management and outcome. *Br J Obstet Gynaecol* 1989; 96: 1339–1344.
- Modesitt SC, Walters AB, Walton L, Fowler WC Jr, Van Le L. Vulvar intraepithelial neoplasia III: Occult cancer and the impact of margin status on recurrence. *Obstet Gynecol* 1998; 92: 962–966.
- Davis G, Wentworth J, Richard J. Self-administered topical imiquimod treatment of vulvar intraepithelial neoplasia. *J Reprod Med* 2000; 45: 619–623.
- van Seters M, Fons G, van Beurden M. Imiquimod in the treatment of multifocal vulvar intraepithelial neoplasia 2/3. *J Reprod Med* 2002; 47: 701–705.
- Jayne CJ, Kaufman RH. Treatment of vulvar intraepithelial neoplasia 2/3 with imiquimod. *J Reprod Med* 2002; 47: 395–398.

10. Todd RW, Ethrington IJ, Luesly DM. The effects of 5% imiquimod cream on high-grade vulval intraepithelial neoplasia. *Gynecol Oncol* 2002; 85: 67–70.
11. Campagne G, Roca M, Martinez A. Successful treatment of high-grade intraepithelial neoplasia with imiquimod, with vulvular pemphigus as a side-effect. *Eur J Obstet Gynecol Reprod Biol* 2003; 109: 224–227.
12. Slade HB, Owens ML, Miller RL. Imiquimod 5% cream (Aldara). *Exp Opin Invest Drugs* 1998; 7: 437–449.
13. Patel M, Ardalan K, Hochman I, Tian EM, Ardalan B. Cytotoxic effects and mechanisms of an alteration in the dose duration of 5-fluorouracil. *Anticancer Res* 2003; 23: 447–452.