

Vestibular Papillomatosis: Case Report and Literature Review

Evren Sarifakioglu¹, Emel Erdal¹ and Canan Gunduz²

¹Department of Dermatology, Fatih University Faculty of Medicine, and ²Department of Obstetrics & Gynecology, Fatih University Faculty of Medicine, Ankara, Turkey. E-mail: esarifakioglu@fatih.edu.tr

Accepted September 26, 2005.

Sir,

The origin of vestibular papillomatosis (VP) is controversial. VP describes the condition of multiple papillae that may cover the entire surface of the vestibule (1). Our literature search for vestibular papillomatosis revealed 13 reports in gynaecological journals and only one in a dermatological journal. Furthermore, searching for vulvar squamous papillomatosis revealed 6 reports in gynaecological journals and again only one in a dermatological journal. We therefore conclude that it is worthwhile drawing the attention of dermatologists to this entity.

CASE REPORT

A 46-year-old sexually active married woman was referred to our clinic for suspected vulvar condyloma acuminatum. The patient was unaware of the presence of the papillae. On dermatological examination, she showed multiple smooth-surfaced small papillomatous projections on the inner side of the labia minora. The colour of the lesions was the same as the adjacent mucosa. The affected areas were not painful to touch. Lavage with 5% acetic acid caused diffuse whitening of the mucosa, which did not specifically involve the papillae (Fig. 1). A biopsy was performed after the patient had given informed consent.

Histologically, the papillary fronds consisted of squamous epithelium characterized by papillomatosis, acanthosis and focal parakeratosis. Within the fibrous stroma, the capillaries were congested. A small number of lymphocytes and plasma cells were present. Additionally, many cells with a clear perinuclear halo, probably glycogenated cells, mimicking koilocytes were observed (Fig. 2). However, the lack of clear-cut nuclear atypia did not permit the identification of these cells as koilocytes. There was no evidence of papillomavirus antigens in the nuclei of koilocytes by immunohistochemical technique (polyclonal human papillomavirus (HPV) stain, DAKO, USA). Polymerase chain reaction (PCR) technique for HPV could not be performed because of the cost of this technique to the patient. The patient's husband did not show clinical features of genital HPV infection.

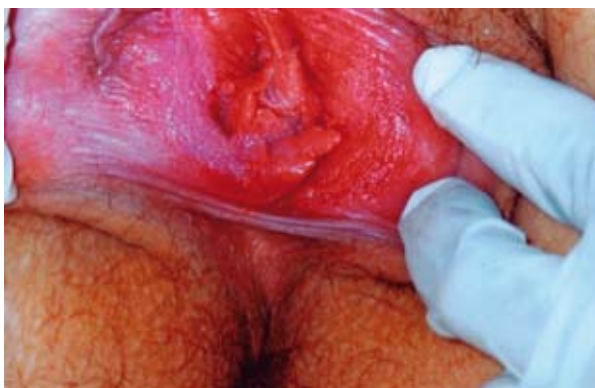

Fig. 1. Diffuse whitening of vestibular papillae following lavage of the labia minora with 5% acetic acid.

DISCUSSION

VP is allegedly presented by 1% of women (1). Altmeyer et al. (2) first ascribed these small projections as pseudocondylomata of the vulva. Since then they have been reported under a variety of names: hirsutoid papillomas of vulvae (2), vulvar squamous papillomatosis (3), micropapillomatosis labialis (4) and squamous vestibular micropapilloma (5). Vestibular papillae are probably the female equivalent of the smooth, flesh-coloured projections of the corona of the glans penis, known as pearly penile papules (6–7).

The clinical resemblance of VP to genital warts has led to controversy about its aetiology. Some authors believe that the lesions are HPV-associated (3, 8). Various molecular biology techniques have been used recently to clarify the origin of VP, but the results have not been unanimous. Two main series of cases have been reported by Wang et al. (8) and Bergeron et al. (4). Wang et al.

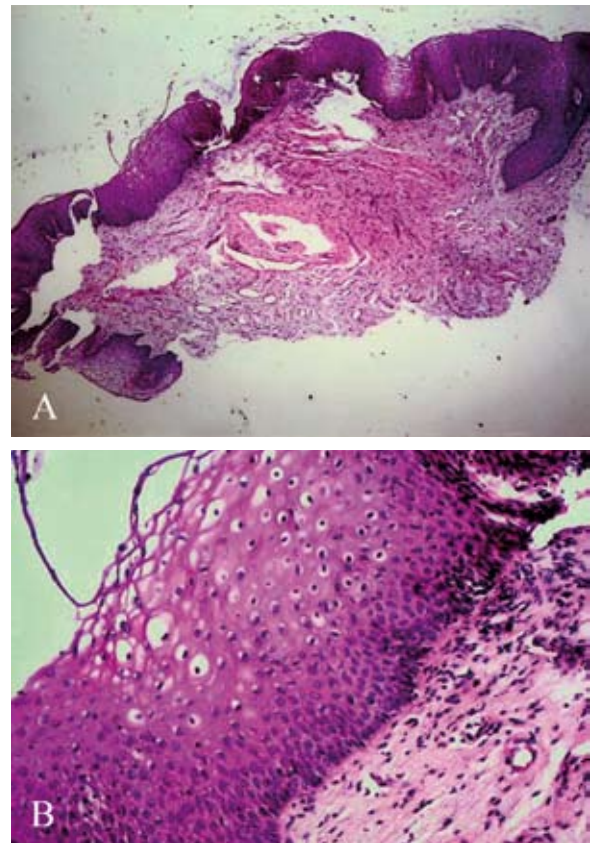


Fig. 2. Histopathological view of the vestibular papillomatosis. (A) Note papillomatosis, acanthosis and focal parakeratosis. (B) Many cells have a perinuclear halo, probably glycogenated cells, mimicking koilocytes (haematoxylin-eosin stain: (A) $\times 50$; (B) $\times 100$).

found a 55% prevalence of HPV, whereas Bergeron et al. found an incidence of 23%. Wang et al. (8) concluded that these lesions should be referred as "micropapillary condylomata". In other studies, Growdon et al. (3) found a 12% and Tribbia et al. (9) a 77.7% incidence of HPV-positive VP lesions using the immunoperoxidase and the *in situ* hybridization techniques, respectively. On the other hand, some consider the lesions as asymptomatic normal anatomical variants of the pelvic architecture (10) and others explained VP as an exaggerated situation of the mucosal epithelium to chronic irritation (11). Most recent studies have shown the independence of this entity with respect to HPV infection (12–14). Moyal-Barracco et al. (12), analysed the biopsy specimen of 29 patients; HPV sequences were detected only in 6.9% of cases. Fallani et al. (10), did not reveal any HPV sequences in 44 women with VP lesions. In order to facilitate the differential diagnosis of VP from genital warts, Moyal-Barracco et al. (12) proposed five clinical parameters of VP. Vestibular papillae are pink-coloured (the same as the adjacent mucosa), soft, linear and symmetrically distributed. The bases of individual vestibular papillae projections remain separate and no circumscribed whitening is seen by the acetic acid test. Condyloma acuminatum, however, is firm and randomly localized. The colour of the condyloma acuminatum lesions can vary and individual projections can coalesce in a common base. In most cases of condyloma acuminata whitening can be observed by the acetic acid test (12).

Our case demonstrated histological koilocytosis. However, histological koilocytosis can overdiagnose HPV infection and demonstrate low specificity. The authors believe that the vestibular epithelium of women is strongly influenced by glycogen production that causes a paling of the cell cytoplasm, which is easily misinterpreted as koilocytosis. Wilkinson et al. (15) reported a 16% histological positivity compared with 9% by DNA identification.

In our patient a diffuse acetowhitening of the vulvar mucosa was observed. A non-specific, diffuse acetowhitening of the vulvar mucosa can be observed with VP. The application of 5% acetic acid to VP does not produce whitening confined to these projections, whereas vestibular condylomata generally show specific acetowhitening. When the surface of the vestibular papillae of the patient was compared with condylomata acuminata, the lesions were more regular. Condylomata are generally scattered haphazardly over the vulvar mucosa (12).

Although VP is considered by some as an asymptomatic clinical entity, a syndrome complex of premonitory vulvar vestibular pruritus, pain or burning, dyspareunia was noted among some patients. Often their symptoms were interfering with their work and sexual activity. These local symptoms made the patients seek help (3). Co-existing vulvar vestibulitis syndrome with VP has also been reported (13). Vulvar vestibulitis syndrome is defined as severe pain on vestibular touch or vaginal

entry, tenderness located within the vulvar vestibulae. Sometimes physical findings of various degrees of vestibular erythema may accompany the syndrome. The pathogenesis of this troublesome clinical entity is unclear.

Growdon et al. (3) has observed that patients with VP can be divided into two groups: asymptomatic patients and those with vulvar pruritus, burning and dyspareunia. On the basis of histological and *in situ* hybridization data, they proposed that symptomatic VP was HPV-induced and asymptomatic VP a variant of normal mucosa. These proposals, however, have not been confirmed by other authors (8). Indeed it seems unlikely that symptoms could be a good marker of HPV infection.

REFERENCES

1. Welch JM, Nayagam M, Parry G, Das R, Campbell M, Whatley J, et al. What is vestibular papillomatosis? A study of its prevalence, aetiology and natural history. *Br J Obstet Gynaecol* 1993; 100: 939–942.
2. Altmeyer P, Chiff GN, Holzmann H. Hirsuties papillaris vulvae (pseudocondylomata of the vulva). *Hautarzt* 1982; 33: 281–283.
3. Growdon WA, Fu YS, Leberer TB, Rapkin A, Mason GD, Parks G. Pruritic vulvar squamous papillomatosis: evidence for human papillomavirus etiology. *Obstet Gynecol* 1985; 66: 564–568.
4. Bergeron C, Ferenczy A, Richart RM, Guralnick M. Micropapillomatosis labialis appears unrelated to human papillomavirus. *Obstet Gynecol* 1990; 76: 281–286.
5. Potkul RK, Lancaster WD, Kurman RJ, Lewandowski G, Weck PK, Delgado G. Vulvar condylomas and squamous vestibular micropapilloma. Differences in appearance and response to treatment. *J Reprod Med* 1990; 35: 1019–1022.
6. Winer JH, Winer LH. Hirsutoid papillomas of coronal margin of glans penis. *J Urol* 1955; 74: 375–378.
7. Ackerman AB, Kronberg R. Pearly penile papules. Acral angiofibromas. *Arch Dermatol* 1973; 108: 673–675.
8. Wang AC, Hsu JJ, Hsueh S, Sun CF, Tsao KC. Evidence of human papillomavirus deoxyribonucleic acid in vulvar squamous papillomatosis. *Int J Gynecol Pathol* 1991; 10: 44–50.
9. Tribbia T, Crescini C, Pezzica E, Marchesi L, Cainelli T. Papillomatosis squamosa pruriginosa vulvae. *Minerva Ginecol* 1990; 42: 499–501.
10. Fallani MG, Penna C, Cioffi M, Gordigiani R, Sonni L, Maggiorelli M, et al. Vulval vestibular papillomatosis: anatomical-clinical study. *Pathologica* 1993; 85: 497–501.
11. Ferenczy A, Richart RM, Wright TC. Pearly penile papules: absence of human papillomavirus DNA by the polymerase chain reaction. *Obstet Gynecol* 1991; 78: 118–122.
12. Moyal-Barracco M, Leibowitch M, Orth G. Vestibular papillae of the vulva. Lack of evidence for human papillomavirus etiology. *Arch Dermatol* 1990; 126: 1594–1598.
13. Origoni M, Rossi M, Ferrari D, Lillo F, Ferrari AG. Human papillomavirus with co-existing vulvar vestibulitis syndrome and vestibular papillomatosis. *Int J Gynaecol Obstet* 1999; 64: 259–263.
14. Prieto MA, Gutierrez JV, Sambucety PS. Vestibular papillae of the vulva. *Int J Dermatol* 2004; 43: 143–144.
15. Wilkinson EJ, Guerrero E, Daniel R, Shah K, Stone IK, Hardt NS, et al. Vulvar vestibulitis is rarely associated with human papillomavirus infection types 6, 11, 16, or 18. *Int J Gynecol Pathol* 1993; 12: 344–349.