

Subungual Basal Cell Carcinoma in an Elderly Japanese Woman

Ryuhei Okuyama, Hiroshi Watanabe, Setsuya Aiba and Hachiro Tagami

Department of Dermatology, Tohoku University Graduate School of Medicine, 1-1 Seiryomachi, Aoba-ku, Sendai, 980-8574, Japan. E-mail: ryuhei@gonryo.med.tohoku.ac.jp

Accepted October 5, 2005.

Sir,

Basal cell carcinoma (BCC) is the most common type of skin cancer. However, BCC that develops in less common locations presents a diagnostic difficulty, even in Caucasians who have a much higher incidence of BCC than do Japanese people. We describe here an elderly Japanese woman who developed subungual BCC in her thumb, which showed clinically as nail deformity associated with dark brownish pigmentation.

CASE REPORT

A 90-year-old Japanese woman had noted brownish nail pigmentation and nail deformity 1 year before in the nail-bed of her left thumb. The pigmentation had enlarged gradually, together with partial nail destruction. Clinical examination revealed a well defined ulcer, 8×6 mm in size and darkly pigmented spots on the ulnar side of the proximal nail-bed of the left thumb (Fig. 1a). The nail was partially lost and covered with crusty debris. Biopsy of the lesion showed the typical features of BCC, consisting of epidermal budding of basaloid cells with peripheral palisading and the occasional formation of superficial nodules (Fig. 1b). The tumour cells were immunohistochemically positive for Ber-EP4, an immunological marker for BCC, without showing any signs for squamous cell carcinoma or malignant melanoma (1, 2) (Fig. 1c). A radiograph of the thumb appeared normal, showing no suggestion of bony change. We surgically removed the fingernail together with the pigmentation including a 5-mm safety margin, and covered the defect with a full-thickness skin graft. Further histological examination of the removed skin revealed that the BCC was chiefly located in the nail-bed extending partially into the nail fold.

DISCUSSION

Squamous cell carcinoma and acral lentiginous melanoma are common tumours involving the nail unit. However, BCC is an extremely rare malignant tumour involving the nail unit (3–7). Therefore, such lesions developing on the fingers could easily be misdiagnosed as chronic dermatitis or mycotic/bacterial infections. There have been several reports of subungual BCC (3–7), in which a correct diagnosis was made only after repeated failure in the treatment made for paronychia that subsequently progressed to skin ulcer. Although subungual BCC occurring in a Japanese patient has not been reported before, the presence of dark brownish pigmentation associated with nail destruction in this case prompted us to perform a skin biopsy, which was critical for reaching the correct diagnosis.

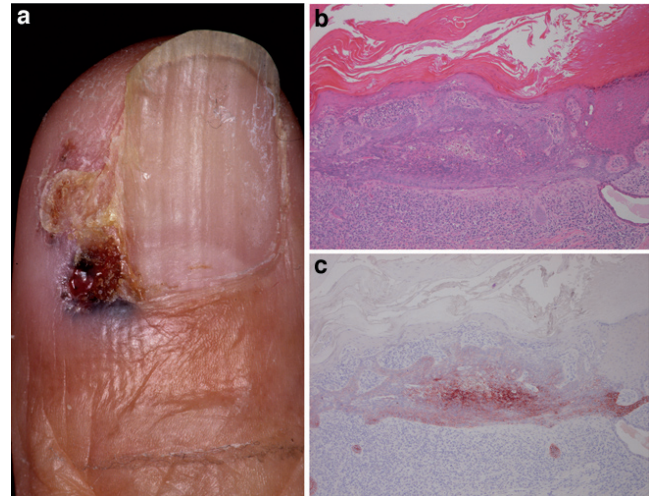


Fig. 1. (a) Dark brownish pigmentation with nail destruction on the nail-bed of the patient's left thumb. (b) Basophilic cells form budding tumour proliferations extending from the undersurface of the epidermis (haematoxylin-eosin stain; original magnification ×100). (c) The tumour cells were positive for Ber-EP4 (×100).

REFERENCES

1. Tellechea O, Reis JP, Domingues JC, Baptista AP. Monoclonal antibody Ber EP4 distinguishes basal-cell carcinoma from squamous-cell carcinoma of the skin. *Am J Dermatopathol* 1993; 15: 452–455.
2. Swanson PE, Fitzpatrick MM, Ritter JH, Glusac EJ, Wick MR. Immunohistologic differential diagnosis of basal cell carcinoma, squamous cell carcinoma, and trichoepithelioma in small cutaneous biopsy specimens. *J Cutan Pathol* 1998; 25: 153–159.
3. Nelson LM, Hamilton CF. Primary carcinoma of the nail bed. *Arch Dermatol* 1970; 101: 63–67.
4. Rudolph RI. Subungual basal cell carcinoma presenting as longitudinal melanonychia. *J Am Acad Dermatol* 1987; 16: 229–233.
5. Guana AL, Kolbusz R, Goldberg LH. Basal cell carcinoma on the nailfold of the right thumb. *Int J Dermatol* 1994; 33: 204–205.
6. Grine RC, Parlette HL 3rd, Wilson BB. Nail unit basal cell carcinoma: a case report and literature review. *J Am Acad Dermatol* 1997; 37: 790–793.
7. Serrano-Ortega S, Fernandez-Angel I, Dulanto-Campos E, Rodriguez-Archilla A, Linares-Solano J. Basal cell carcinoma arising in professional radiodermatitis of the nail. *Br J Dermatol* 2002; 147: 628–629.