

Necrotizing Livedo Related to Neoplastic Microvascular Embolism

Myriam Marque¹, Olivier Dereure¹, Luc Durand², Céline Girard¹ and Bernard Guillot¹

¹Department of Dermatology, and ²Laboratory of Pathology, University Hospital of Montpellier, 80 Avenue Augustin Fliche, FR-34295 Montpellier Cedex 5, France. E-mail: o-dereure@chu-montpellier.fr

Accepted November 11, 2005.

Sir,

A 64-year-old woman was admitted for evaluation of a necrotic livedo of the perineal area. She had developed fluctuating erosive lesions of the buttocks within the past 3 months, initially considered as sacral herpes zoster and treated with oral aciclovir without significant results. Her medical history included multi-complicated type 2 diabetes mellitus, elevated blood pressure, atrial flutter, inter-atrial communication, and chronic exposure to tobacco (40 packs (7300 cigarettes) per year).

At initial evaluation, she displayed erythematous, exquisitely painful, necrotic and livedoid lesions of the buttocks, lumbar areas, vulva and perineum. No other skin lesions were noticed, especially on the extremities. Physical examination also showed a reduction in intensity of pulses on lower limbs, effort-related claudication, a mitral heart murmur and a mild alteration of the intellectual capabilities.

Biological explorations disclosed increased inflammatory parameters but no significant abnormality regarding standard and coagulation tests (absence of anti-phospholipid antibodies or cryoglobulinaemia; serum levels of protein C and S, anti-thrombin III and homocysteine within normal limits; no resistance to activated C protein). Echocardiography was normal except for the inter-atrial communication already known. Skin biopsies revealed obstructions of the dermal vessels by clusters of neoplastic cells further identified by immuno-histological methods as adenocarcinoma cells with positive results for cytokeratins AE1-AE3 and 7 and no staining with cytokeratin 20 and CA-125. However, renal, abdominal and pelvic ultrasound, endoscopic exploration of upper and lower digestive tract, total-body scan and mammography failed to identify any primary neoplastic lesion. Instead, the scanner disclosed an aortic sub-renal thrombosis with complete luminal occlusion along with a highly reduced perfusion in the hypogastric and iliac territories contrasting with the development of a collateral circulation directed to the lower limbs.

Anticoagulant therapy was then introduced without any significant clinical improvement and the livedo slowly spread during the following month, resulting in severe necrotic lesions while small, painful ulcerations of the legs and weakness of the lower limbs appeared as well. In the meantime, intellectual alterations quickly worsened with increasing negligence without any evidence of brain metastasis, cerebral infarct, neoplastic, viral or

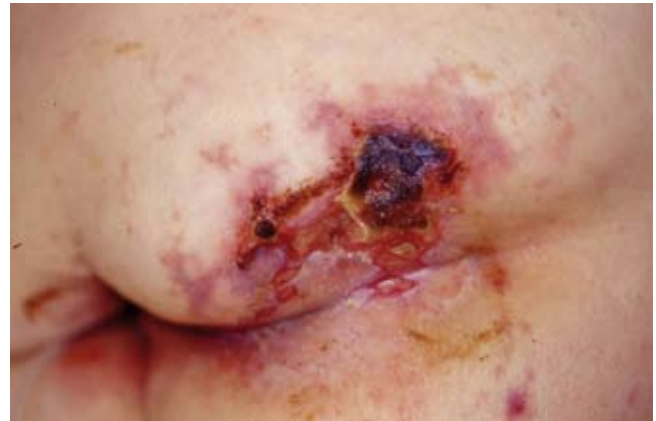

Fig. 1. Necrotizing livedo of the perineal area.

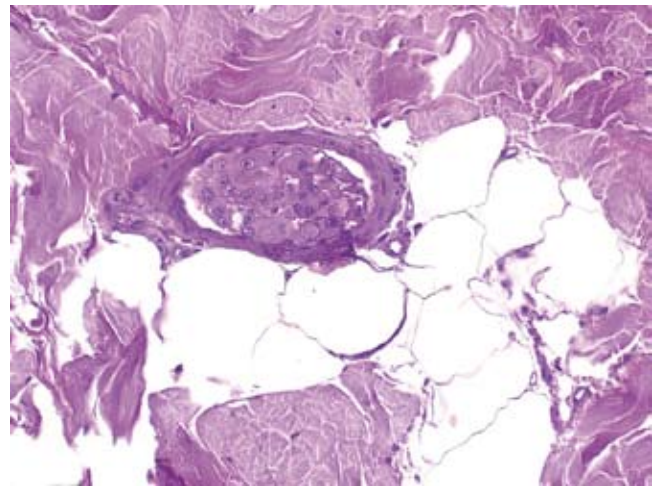


Fig. 2. Clusters of neoplastic cells resulting in occlusion of small vessels.

bacterial meningitis or meningo-encephalitis according to comprehensive investigations including cerebrospinal fluid analysis and brain magnetic resonance imaging (MRI). Two courses of gemcitabine were eventually performed due to the undetermined origin of the causal neoplasia, but the patient died 2 months after admission and 5 months after the occurrence of the first cutaneous signs. No post-mortem examination was performed.

DISCUSSION

Necrotizing livedo occurring in a neoplastic setting is most often related to a secondary anti-phospholipid

syndrome (1). However, repeated explorations failed to disclose any anti-phospholipid antibodies or other coagulation disorders in our patient. Instead, in our case, the histological pattern of dermal vessel occlusion by clusters of neoplastic cells highly suggests a previously undescribed mechanism of micro-embolization by cells originating from a primary, remote or regional malignant tumour. A similar mechanism has only been described or hypothesized in two previous reports of livedo associated with solid neoplasia, i.e. a renal carcinoma (but no skin biopsy was performed) (2) and a breast carcinoma with a localized livedo and a prominent lymphatic involvement by clusters of neoplastic cells as demonstrated by skin biopsies (3). However, in both cases, no occlusion of the dermal arteries was noticed, highlighting the unique pattern of the likely pathomechanism of livedo in our observation. The precise origin of the neoplastic cells is debatable in the absence of a clear primary tumour (a probable adenocarcinoma according to immunohistochemical data) despite in-depth and repeated investigations. The massive occlusion of the subrenal abdominal aorta with development of a collateral circulation might support the hypothesis of a systemic dissemination by a remote tumour, with paradoxical embolism because of the inter-atrial communication already known in our patient; in this view, the aortic thrombus, possibly infiltrated by neoplastic

cells, might act as a relay for secondary, perineal embolism in the area perfused by the hypogastric arteries. However, a local invasion by a regional tumoural process after arterial erosion cannot be ruled out despite inconclusive morphological investigations.

Finally, it is of interest to note that two other entities may display both a similar clinical pattern and a close mechanism of tumoral endovascular occlusion, i.e. tumours with endovascular proliferation such as aortic angiosarcoma (4) and endovascular lymphoma (5). However, immunohistochemical analysis easily ruled out these hypotheses in our patient.

REFERENCES

1. Gibson GE, Su D, Pittelkow M. Antiphospholipid syndrome and the skin. *J Am Acad Dermatol* 1997; 36: 970–982.
2. Erel A, Ozsoy E. Livedo reticularis associated with renal cell carcinoma. *Int J Dermatol* 2001; 40: 299–300.
3. Spiers EM, Fakharzadeh SS. Livedo reticularis and inflammatory carcinoma of the breast. *J Am Acad Dermatol* 1994; 31: 689–690.
4. Rudd R, Fair K, Patterson J. Aortic angiosarcoma presenting with cutaneous metastasis: case report and review of the literature. *J Am Acad Dermatol* 2000; 43: 930–933.
5. Wolter M, Badoual C, Wechsler J, Lambolez T, Haioun C, Bouloc A, et al. Lymphome intravasculaire révélé par des télangiectasies diffuses et un syndrome de la queue de cheval. *Ann Dermatol Venerol* 2002; 129: 320–324.