

LETTERS TO THE EDITOR

Basal Cell Carcinomas in Port-wine Stains Treated with Thorium X

Bernd Algermissen¹, Hans-Peter Berlien¹ and Norbert Haas^{2*}

¹Department of Laser Medicine, Krankenhaus Neukölln, Berlin and ²Department of Dermatology and Allergy, Charité, Humboldt-University Berlin, Schumannstrasse 20/21, DE-10117 Berlin, Germany. *E-mail: norb.haas@charite.de
Accepted June 7, 2004.

Sir,

Thorium X, a natural isotope of radium, was the main radiotherapeutic modality for treating vascular lesions of the skin including port-wine stain (PWS) available to dermatologists during the 1930s to 1950s. It disappeared from dermatological practice around the 1960s, and the chapter on thorium X was considered closed (1, 2). However, occasionally long-term sequelae have been described (2). Here we report three further patients with basal cell carcinomas (BCCs) arising in PWS.

CASE REPORTS

Patient 1

A 61-year-old woman had been treated for a facial PWS at the age of 11 years with a monthly series of thorium X paints which was stopped after 1 year since the PWS persisted. At age 40, a BCC within the PWS was excised, and 20 years later a second solid BCC was removed.

Patient 2

A 71-year-old woman with a PWS on the left cheek had been painted with thorium X from age 5 to 12 years until 1944, when the Berlin thorium X plant was destroyed in an air attack. At age 65, a BCC within the treated area of the left cheek was removed. Later scars were revised by plastic surgeons and the remaining PWS was successfully treated with a flashlamp-pumped dye laser.

Patient 3

A 65-year-old woman reported that at the age of 15 years a PWS had been treated with applications of thorium X at 4–6 week intervals for about a year, until the stain had mostly disappeared. From the age of 45 a progressively tuberous degeneration appeared in the form of numerous smooth, soft facial nodules. When a hard nodule on the temple (above the left eyebrow) was excised, a solid BCC was found.

DISCUSSION

BCC in PWS has been reported both in the absence of any previous therapy (3) and in patients treated with thorium X (4–6). BCC appeared at varying time spans (5–75 years) after therapy (4–6). In most cases, however, this time span could not be determined exactly, and the number of applications and the cumulative dose remained unknown (6).

Thorium X was routinely applied in vehicles such as aqueous or alcohol paints and ointments. Before treatment, the skin area was degreased, then the solution or ointment was applied. At 24–48 h later, an erythema and oedema-like sunburn developed, regardless of the vehicle used. The treatment was repeated at 6–8 week intervals, until the desired result was achieved (7).

Thorium X applications used in Germany contained 1000 e.s.u. (electrostatic units) per mg, in England 500 e.s.u. with an average cumulative dose of 6000 e.s.u. (7).

Thorium X was primarily used for the treatment of flat vascular naevi, but also for facial pigmented or verrucous naevi. Furthermore, it was employed in a wide range of dermatoses such as atopic dermatitis, lupus erythematosus, alopecia areata, psoriasis, hyperpigmentations and keloids (7).

In Eastern Germany, regular treatment was possible due to a continuous supply that was available from 1953 onwards. From 1953 to 1956 the department of dermatology in Dresden treated 134 PWSs, mostly in small children, but also in older children and adults (7).

The association of the two lesions – BCC and PWS – raises the question of thorium X as a causative factor in the occurrence of BCC. The authors felt that cutaneous malignancy may become more common in this group of patients (7). Tuberous or nodular alterations within a PWS and a history of thorium X application should be subject to further examination before laser treatment.

REFERENCES

1. Mohajerin AH. Thorium X in the treatment of nevus flammeus. *Acta Derm Venereol* 1966; 46: 186–189.
2. Scerri L, Allen BR. Thorium X in dermatology: a closed chapter. *Int J Dermatol* 1996; 35: 142–144.
3. Magana-Garcia M, Magana-Lozano M. Multiple basal cell carcinomas arising in port-wine haemangiomas. *Br J Dermatol* 1988; 119: 393–396.
4. Rogers J. Thorium X induced BCC: a case report. *Br J Dermatol* 1954; 66: 31.
5. Scerri L, Navaratnam AE. Basal cell carcinoma presenting as a delayed complication of thorium X used for treating a congenital hemangioma. *J Am Acad Dermatol* 1994; 31: 796–797.
6. Shah M, Lewis FM, Palmer IR. Three cases of multiple basal cell carcinoma arising in port-wine stains previously treated with thorium X. *Br J Dermatol* 1996; 135: 861–862.
7. Frühwald R. Welche Hautkrankheiten soll man mit Thorium X behandeln? *Dermatologische Wochenschrift* 1956; 133: 184–185.

Subungual Hyperkeratosis of the Big Toe Due to *Bipolaris hawaiiensis*

Clara Romano, Alberto Ghilardi and Lucia Massai

Institute of Dermatological Science, University of Siena, Via Monte Santo, 3, IT-53100 Siena, Italy. E-mail: mondelli@unisi.it
Accepted 5 March 2004.

Sir,

Mycetes of the genus *Bipolaris* are phaeohyphomycetes with worldwide distribution, present in decomposing plants and soil. They are plant pathogens and may cause various disorders in animals and humans, such as mycetoma in mammals and allergic sinusitis and keratitis, as well as subcutaneous, sinus, intracranial and disseminated infections in humans. Here we report a case of onychomycosis of the big toe due to *Bipolaris hawaiiensis* in a healthy 35-year-old woman.

CASE REPORT

A healthy 35-year-old woman presented with a 2-year history of distal-lateral subungual hyperkeratosis of the left big toe, with onycholysis and perionyx (Fig. 1). The patient complained of recurrent episodes of perionyx. One year previously, she had been unsuccessfully treated with 250 mg/day terbinafine for 2 months.

We obtained a specimen of nail from the hyperkeratotic area for mycological examination. Direct light microscope observation of the material, after soaking in 30% potassium hydroxide, revealed large, non-dermatophytic hyphae. Culture on Sabouraud dextrose agar with chloramphenicol (CAF) or CAF and cycloheximide produced cottony grey colonies after a week of incubation. The colonies turned blackish in time. Microscope examination showed dark brown-pigmented conidiophores and smooth brown cylindrical conidia disposed in sympodial order and divided by 5–7 pseudosepta (Fig. 2). The mycete was identified as *B. hawaiiensis*. Culture, repeated twice more at intervals of 7 days, produced pure cultures of colonies of the same mycete from many inoculations. The patient was diagnosed with onychomycosis due to *B. hawaiiensis* and treated with pulsed itraconazole, 400 mg/day for 7 days/month, for 3 months. Clinical and mycological recovery were achieved. The patient did not have other

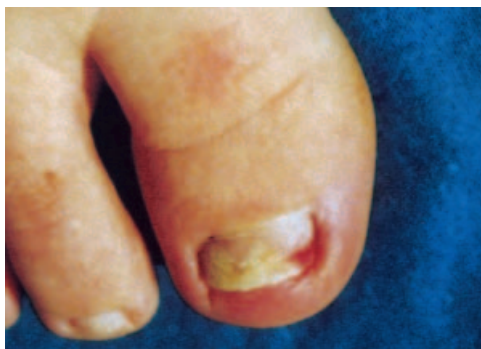

Fig. 1. Distal-lateral subungual hyperkeratosis of the left toenail.

skin lesions or signs or symptoms that could be ascribed to mycosis. Routine blood chemistry was normal and no immune deficit was found.

DISCUSSION

Known species of the genus *Bipolaris* include *B. hawaiiensis*, *B. spicifera*, *B. papendorfii* and *B. australiensis*. They are distinguished on the basis of macro and microscopic characteristics of the colonies. The conidia of *B. hawaiiensis* are cylindrical or cigar-shaped with up to seven septa.

B. hawaiiensis has been responsible for cases of sinusitis (1), osteolysis (2), keratitis (3), endophthalmitis (4), subcutaneous infections (5) and meningoencephalitis (6). *B. spicifera* has been isolated in skin infections, sinus infections, keratitis and endocarditis. *B. australiensis* has been isolated in cases of peritonitis, sinusitis and subcutaneous infections; *B. papendorfii* has been isolated in a case of keratitis.

Cases of nail infection due to *Bipolaris* have never been reported, but Negroni (7) discussed three cases of onychomycosis due to *Drechslera cactivora*. The three strains of *Drechslera* were subsequently reclassified as *Exserohilum* by McGinnis et al. (8). Indeed, *Bipolaris*, *Drechslera* and *Exserohilum* have many similarities, to the extent that *Drechslera* and *Bipolaris* are used as synonyms by some authors in describing mycoses in humans and animals (1). In the first edition of the *Atlas of Clinical Fungi*, *Bipolaris* is described under *Drechslera* (9). However, the genus *Bipolaris* has curved conidia that only arise from polar cells, whereas *Drechslera* has straight conidia that arise from all cells. *Bipolaris* lacks protuberant conidial hyla, which are a character

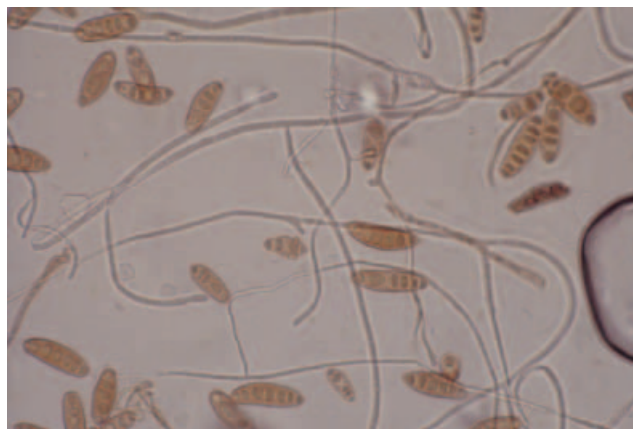


Fig. 2. Cylindrical conidia with 5–7 pseudosepta (potassium hydroxide, $\times 250$).

of the genus *Exserohilum*. In the three cases reported by Negroni (7), the nails of the big toes were affected and the clinical manifestations were indistinguishable from those of dermatophyte infections. At the present time, most cases of onychomycosis are caused by dermatophytes. In our patient there was also distolateral hyperkeratosis; however, it was associated with recurrent perionyx which does not usually occur in dermatophytic onychomycosis. The diagnosis of onychomycosis was based on the criteria by English: repeated isolation of pure cultures of the mycete from numerous inoculations (10), which demonstrates the pathogenicity of the mycete. The microscopic appearance of the colonies was typical of the genus *Bipolaris*, the absence of true conidial septa enabling us to exclude the genus *Curvularia*.

In our case, the response to 2 months of terbinafine therapy was poor, whereas pulsed itraconazole therapy was successful. Itraconazole has also been found to be more effective than terbinafine in *in vitro* studies (11) and, combined with surgery, it is reported to be useful in the treatment of sinusitis due to *B. hawaiiensis*.

Onychomycoses due to non-dermatophytes are reported with increasing frequency (12–14) and are considered important because of the capacity of certain mycetes to cause disseminated infections and the fact that the mycete may enter the body as a pathogenic agent through infection of the skin and nails (15), a rare route of entry in healthy subjects but is described prevalently in immunosuppressed patients. This is why correct diagnosis and follow-up of patients with nail infections due to hyphomycetes such as *Bipolaris* are important.

REFERENCES

1. Fryen A, Mayser P, Glanz H, Fussle R, Breithaupt H, de Hoog GS. Allergic fungal sinusitis caused by *Bipolaris (Drechslera) hawaiiensis*. *Eur Arch Otorhinolaryngol* 1999; 256: 330–334.
2. Young CN, Swart JG, Ackerman D, Davidge-Pitts K. Nasal obstruction and bone erosion caused by *Drechslera hawaiiensis*. *J Laryngol Otol* 1978; 92: 137–143.
3. Anandi V, Surja Washi NB, Koshi G, Padhye AA, Ajello L. Corneal ulcer caused by *Bipolaris hawaiiensis*. *J Med Vet Mycol* 1988; 26: 301–306.
4. Pavan PR, Margo CE. Endogenous endophthalmitis caused by *Bipolaris hawaiiensis* in a patient with acquired immunodeficiency syndrome. *Am J Ophthalmol* 1993; 116: 644–645.
5. Costa AR, Porto E, Tabuti AH, Lacaz Cda S, Sakai-Valente NY, Maranhao WM, et al. Subcutaneous phaeoophomycosis caused by *Bipolaris hawaiiensis*. A case report. *Rev Inst Med Trop Sao Paulo* 1991; 33: 74–79.
6. Fuste FJ, Ajello L, Threlkeld R, Henry JE Jr. *Drechslera hawaiiensis*: causative agent of a fatal fungal meningoencephalitis. *Sabouraudia* 1973; 11: 59–63.
7. Negroni P. *Drechslera cactivora*, nuevo agente de micosis oportunista de las ungas. *Rev Arg Micologia* 1985; 8: 17–20.
8. McGinnis MR, Rinaldi MG, Winn RE. Emerging agents of phaeoophomycosis: pathogenic species of *Bipolaris* and *Exserohilum*. *J Clin Microbiol* 1986; 24: 250–259.
9. de Hoog GS, Guarro J. Hyphomycetes: *Bipolaris*. In: de Hoog GS, Guarro J, eds. *Atlas of clinical fungi*. Baarn, Centraalbureau Voor Schimmelcultures, 1995: 155–157.
10. English MP. Nails and fungi. *Br J Dermatol* 1976; 94: 697–701.
11. McGinnis MR, Pasarel L. *In vitro* evaluation of terbinafine and itraconazole against dematiaceous fungi. *Med Mycol* 1998; 36: 243–246.
12. Gianni C, Cerri A, Crosti C. Non-dermatophytic onychomycosis. An underestimated entity? A study of 51 cases. *Mycoses* 2000; 43: 29–33.
13. Escobar ML, Carmona-Fonseca J. Onychomycosis by common non-dermatophyte moulds. *Rev Iberoam Micol* 2003; 20: 6–10.
14. Garcia-Martos P, Dominguez I, Marin P, Linares M, Mir J, Calap J. Onicomycosis por hongos filamentosos no dermatofitos en Cadiz. *Enf Infecc Microbiol Clin* 2000; 18: 319–324.
15. Arrese A, Pierard-Franchimont JE, Pierard GE. Fatal hyalohyphomycosis following *Fusarium* onychomycosis in an immunocompromised patient. *Am J Dermatopathol* 1996; 18: 196–198.

Successful Treatment of Multicentric Reticulohistiocytosis with a Combination of Infliximab, Prednisolone and Methotrexate

Mi-Woo Lee¹, Eun-Young Lee², Young Il Jeong¹, Jee-Ho Choi¹, Kee-Chan Moon¹ and Jai-Kyoung Koh¹

Departments of ¹Dermatology and ²Internal Medicine, Asan Medical Center, College of Medicine, University of Ulsan, 388-1, Poongnap-Dong, Songpa-Gu, Seoul, 138-736, Korea. E-mail: miumiu@www.amc.seoul.kr

Accepted March 15, 2004.

Sir,

Multicentric reticulohistiocytosis (MR) is a rare disorder characterized by epithelioid granulomas affecting various tissues or organs, most commonly the skin and joints (1, 2). It has been difficult to assess different treatment regimens because MR is rare. There have been case reports of sustained responses to methotrexate and cyclophosphamide (3, 4), but treatment regimens depending exclusively on alkylating agents may be too toxic for routine use. Corticosteroids have shown varying efficacy in MR, with some investigators reporting no benefit of corticosteroids (4), and others reporting success (5). Treatment of MR with non-steroidal anti-inflammatory drugs, D-penicillamine (6), azathioprine (7) and cyclosporine (8) has yielded disappointing results. We here report a case of MR successfully treated with anti-tumour necrosis factor (TNF)- α monoclonal antibody (infliximab), prednisolone and methotrexate.

CASE REPORT

A 53-year-old woman presented with a 2-month history of polyarthralgias and limitation of movements in her shoulders, wrists, hands, and knees and a 1-month history of skin lesions. On examination of the skin, red, confluent, non-pruritic patches were seen on the V area of the neck and upper back. Small erythematous papules were present on the pinna of the left ear, and the dorsum of the fingers, particularly around the nail folds (Fig. 1a). Large erythematous to violaceous nodules occurred on the arthroscopy sites of the knees (Fig. 1c). Joint examination

was significant for general swelling involving hands and wrists, pain on motion, plus decreased range of motion of the shoulders, wrists, and metacarpophalangeal and interphalangeal joints. Her knees showed moderate effusion bilaterally, with decreased mobility. Numerous laboratory tests including peripheral blood count, biochemistry, serum lipids, serum protein electrophoresis and complement profile were normal. The erythrocyte sedimentation rate and C-reactive protein were not elevated. Testing for both rheumatoid factor and anti-nuclear antibodies yielded negative results. Radiology of the hands and knees at presentation showed no abnormalities. Two biopsies from the nodules of the knees, one from the hand and one from the anterior chest, showed densely packed giant cells and histiocytes with little intervening collagen in the entire dermis and extending to the subcutaneous tissues. The cells were moderately large, oval, polygonal, or slightly elongated, and predominantly mononuclear, generally 10–25 μ in diameter. Multinucleate cells were common, usually containing 2–4 nuclei and rarely, up to 30 nuclei (Fig. 2). Cytoplasm was abundant and strongly PAS-positive. Immunohistochemical staining showed that the histiocytic cells and giant cells were CD68-positive, S-100 protein-negative and CD1a-negative. A diagnosis of MR was established. Investigations for malignancy, such as computerized tomography of abdomen, pelvis, upper gastrointestinal series, barium enema and liver-spleen scan were normal. We decided to initiate infliximab, 300 mg/day (5 mg/kg), intravenously in combination with methotrexate (7.5 mg/week) and prednisolone

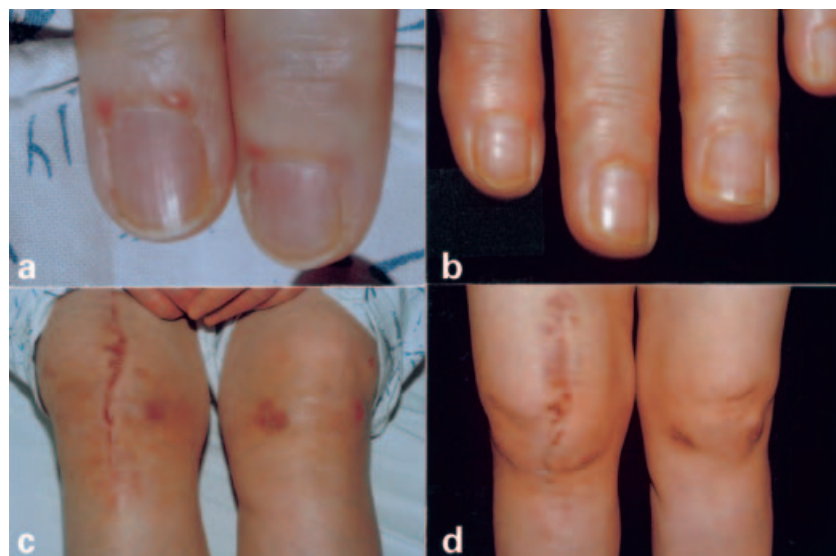


Fig. 1. Periungual papules and nodules on the knees before therapy (a and c), which disappeared within 2 months after infliximab treatment (b and d).

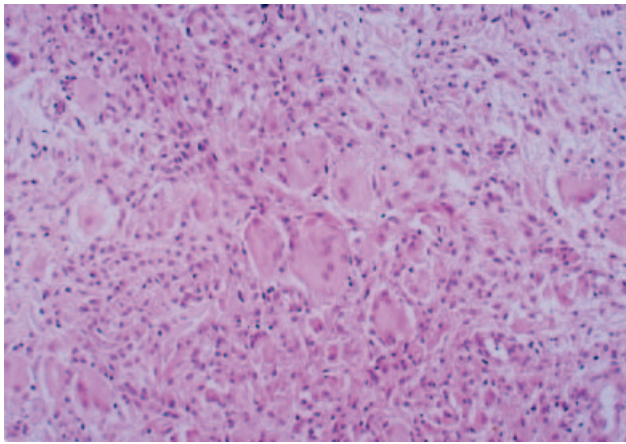


Fig. 2. Histiocytic multinucleate giant cells containing pale eosinophilic cytoplasm with a granular, ground-glass appearance (H&E, $\times 200$).

30 mg/day. After 2 weeks of treatment, prednisolone was tapered to a maintenance dose of 5 mg/day. Infliximab was given at 4, 8, 12 and 16 weeks. The clinical response to treatment was rapid, with noticeable regression of the papulo-nodules after the first infusion and further continuous improvement after subsequent injections (Fig. 1b, d). No new lesions appeared within 2 months. Arthralgias and decreased hand, wrist and shoulder functions were improved within 3 months. The patient experienced no side effects.

DISCUSSION

MR is a multi-system inflammatory disorder of unknown cause. Increasing evidence indicates that monocytes-macrophages and immunoregulatory cytokines may play a role in the pathogenesis (9–11). Zagala et al. (9) demonstrated enhanced secretion of interleukin-1 (IL-1), prostaglandin E₂ and IL-2 from peripheral blood mononuclear cells in MR. Other investigators detected IL-1 β and platelet-derived growth factor B in multinucleate giant cells in the tissue of MR (10). Gorman et al. (11) demonstrated synovial tissue staining in macrophages positive for several cytokines, including TNF- α . TNF- α indirectly induces cartilage and bone destruction by stimulating macrophages to produce destructive protease (11, 12). It can therefore be assumed that up-regulation of soluble factors, such as TNF- α , IL-1, and IL-2, and hypersensitivity of macrophages as well as lymphocytes are involved in the pathogenesis of MR.

Infliximab is a chimeric IgG monoclonal antibody against human TNF- α in clinical use primarily for rheumatoid arthritis, Crohn's disease, and sarcoidosis (12). Information on the use of infliximab in MR is sparse and consists solely of case reports. Matejicka

et al. (13) described a case of MR unresponsive to multiple interventions that was subsequently successfully treated with another TNF- α antagonist, etanercept. Infliximab appears to be a safe and effective agent in the treatment of MR that is refractory to conventional drug therapies. Methotrexate and prednisolone were given to suppress the potential development of antibodies to infliximab and potentiate the drug efficacy. The long-term toxicity from infliximab is still being evaluated. There is increased risk of infection, including tuberculosis (12).

REFERENCES

1. Barrow MV, Holubar K. Multicentric reticulohistiocytosis. A review of 33 patients. *Medicine* 1969; 48: 287–305.
2. Hsiung SH, Chan EF, Elenitsas R, Kolasinski SL, Schumacher HR, Werth VP. Multicentric reticulohistiocytosis presenting with clinical features of dermatomyositis. *J Am Acad Dermatol* 2003; 48: 11–14.
3. Liang GC, Granston AS. Complete remission of multicentric reticulohistiocytosis with combination therapy of steroid, cyclophosphamide, and low-dose pulse methotrexate. *Arthritis Rheum* 1996; 39: 171–174.
4. Franck N, Amor B, Ayrat X, Lessana-Leibowitch M, Monsarrat C, Kahan A. Multicentric reticulohistiocytosis and methotrexate. *J Am Acad Dermatol* 1995; 33: 524–525.
5. Pandhi RK, Vaswani N, Raman M, Singh MK, Bhutani LK. Multicentric reticulohistiocytosis: response to dexamethasone pulse therapy. *Arch Dermatol* 1990; 126: 251–252.
6. Doherty M, Martin MFR, Dieppe PA. Multicentric reticulohistiocytosis associated with primary biliary cirrhosis: successful treatment with cytotoxic agents. *Arthritis Rheum* 1984; 27: 344–348.
7. Krey PB, Comerford FR, Cohen AS. Multicentric reticulohistiocytosis: fine structural analysis of the synovium and synovial fluid cells. *Arthritis Rheum* 1974; 17: 615–633.
8. Kuramoto Y, Iizawa O, Aiba S. Multicentric reticulohistiocytosis in a child with sclerosing lesion of the leg. *J Am Acad Dermatol* 1989; 20: 329–335.
9. Zagala A, Guyot A, Bensa JC, Phelip X. Multicentric reticulohistiocytosis: A case with enhanced interleukin-1, prostaglandin E₂ and interleukin-2 secretion. *J Rheumatol* 1988; 15: 136–138.
10. Nakajima Y, Sato K, Morita H, Torikai S, Hidano A, Nishioka K, et al. Severe progressive erosive arthritis in multicentric reticulohistiocytosis: possible involvement of cytokines in synovial proliferation. *J Rheumatol* 1992; 19: 1643–1646.
11. Gorman JD, Danning C, Schumacher HR, Klippel JH, Davis JC. Multicentric reticulohistiocytosis. *Arthritis Rheum* 2000; 43: 930–938.
12. Mallbris L, Ljungberg A, Hedblad MA, Larsson P, Ståhle-Bäckdahl M. Progressive cutaneous sarcoidosis responding to anti-tumor necrosis factor- α therapy. *J Am Acad Dermatol* 2003; 48: 290–293.
13. Matejicka C, Morgan GJ, Schlegelmilch JG. Multicentric reticulohistiocytosis treated successfully with an anti-tumor necrosis factor agent: comment on the article by Gorman et al. *Arthritis Rheum* 2003; 48: 864–866.

Vegetating Iododerma and Pulmonary Eosinophilic Infiltration. A Simple Co-occurrence?

Guglielmo Pranteda¹, Miriam Grimaldi¹, MariaLina Salzetta¹, Michele Di Molfetta², Enzo Palese¹, Giuseppe Panasiti¹ and Ugo Bottoni¹

¹Department of Skin and Sexually-transmitted Diseases and Plastic and Reconstructive Surgery, University of Rome "La Sapienza", II School of Medicine, S. Andrea Hospital, Via di Grottarossa 1035, Rome, Italy and ²Department of Pulmonary Disease, Carlo Forlanini Hospital, Rome, Italy. E-mail: cpranteda@hotmail.com

Accepted April 27, 2004.

Sir,

Iodine derivatives are used as contrast media in radiology and as drugs to treat pulmonary disorders as well as erythema nodosum (1, 2). Their use may cause side effects such as dysfunction of the thyroid and salivary glands or allergic reactions. Other side effects are the so-called 'iodides', skin eruptions, characterized by papules and pustules. These lesions can evolve towards characteristic nodules, seen in typical vegetating pyodermitis or iododerma (3). Recently, we observed a case of vegetating iododerma with noticeable pulmonary infiltration.

CASE REPORT

A 62-year-old woman presented with vegetating, soft nodular lesions sited on her ears and fingers (Figs 1 and 2). On the scalp there were crusts, whereas on the forearms and on the head there were several scattered papules, considered to be the initial sign appeared 2 months before our examination. Other specialists had herpes zoster as the diagnosis; however, treatment with acyclovir produced no clinical response.

At examination, the patient had fever (38°C), a mild dyspnoea and whistlings and wheezings. She had been suffering from allergic asthma for 20 years. Prick tests had been positive for house dust mite. Corticosteroids had been given systemically during acute relapses. Ten years earlier a therapy with potassium iodide 25% solution (20 drops three times per day) was started.

General laboratory tests showed leucocytosis (12,700 leucocytes/ μ l), eosinophilia (40.5%) and high ESR (90 mm/1 h), while all the other tests were in the normal range.

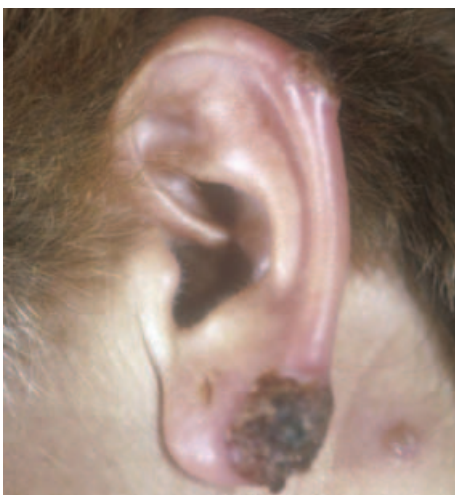

Fig. 1. Vegetating nodular lesion covered by crusts sited on left ear. In the retroauricular area a papulo-pustular lesion is present.

A chest X-ray and CT scan showed several infiltrates in different pulmonary segments. The cytological exams on smears from broncho-alveolar washing revealed 70% eosinophils and 30% lymphocytes while tumour cells were absent.

Multiple cultures on material collected from cutaneous pustules and on the broncho-alveolar smears were negative for fungi, bacteria and mycobacteria. A skin biopsy was taken from a papular pustule on the left forearm. Histological examinations showed pseudoepitheliomatous superficial hyperplasia and a subepidermal pustule formed by neutrophils and eosinophils (Fig. 3). Intradermal skin tests with potassium iodide (50 μ g in 1 ml of NaCl 0.9%), and human serum albumin plus potassium iodide (50 μ g) were all negative after 30 min, 48 h and 72 h. Also the lymphocyte transformation test was negative. This test evaluates the proliferative

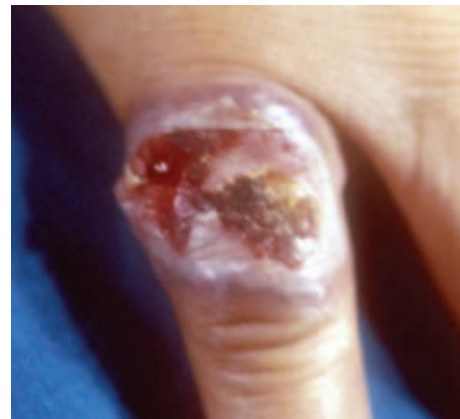

Fig. 2. Vegetating nodular lesion, partially ulcerated and covered by crusts, sited on the right little finger.

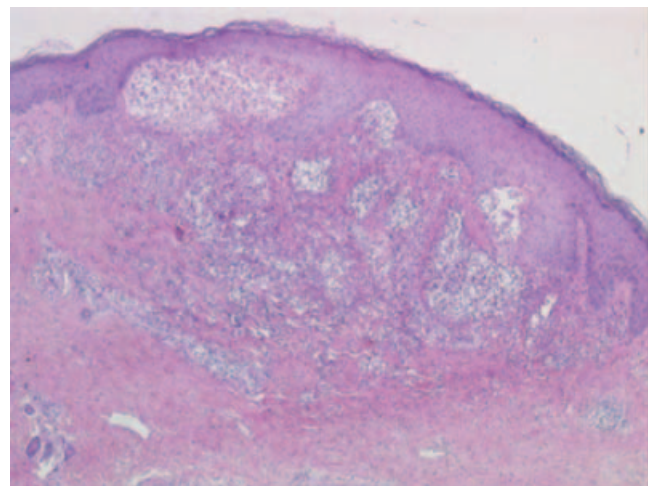


Fig. 3. Pseudoepitheliomatous superficial hyperplasia and a subepidermal pustule (haematoxylin and eosin, $\times 10$).

activity of patient's lymphocytes after incubation with the same substances as in the skin tests, measuring the uptake of ^3H -thymidine.

Other tests, including serum electrophoresis, urinalysis and the faecal test for helminths were all negative.

The cutaneous lesions disappeared within 10 days from suspension of potassium iodide and administration of clarithromycin (250 mg per os twice daily for 20 days). Since respiratory symptoms persisted after clarithromycin, treatment with prednisolone was started at the dosage of 40 mg/day for 15 days, followed by 20 mg/day for 15 days. After 1 month her dyspnoea subsided and the pulmonary infiltrates regressed. No clinical relapses of vegetating iododerma occurred during the 12-month follow-up period, during which eosinophilia and ESR normalized, and the pulmonary infiltrates on X-ray disappeared.

DISCUSSION

Iododerma is a rare event nowadays, since iodine-containing drugs are infrequently used compared to in the past (1, 4). Cases of vegetating iododerma are occasionally reported (5–8). In its initial phase this disease is characterized by papules and pustules that evolve in pseudotumoral vegetating lesions. In our patient such lesions had appeared after 10 years of daily treatment with potassium iodide and promptly disappeared after its suspension.

Different pathogenetic hypotheses have been proposed to explain the onset of iododerma in patients exposed to contrast media or drugs containing iodine. An immunological mechanism was suggested by Rosenberg et al. (9) and Cape (10), due to the frequent presence of eosinophils in both skin lesions and in peripheral blood. On the contrary, Stone (11) hypothesized that iodine may directly activate eosinophils, which is more in line with our case as the specific immunological tests performed were all normal. Eosinophilia was present not only in peripheral blood but also in cutaneous and pulmonary lesions. After the suspension of potassium iodide this eosinophilia normalized.

Iododerma have been reported associated with multiple myeloma, lymphomas, arthritis, panarteritis nodosa and subacute glomerulonephritis (6). Also an association with pulmonary disorders has been reported (7, 8, 11–13). A very similar case to ours was reported by Wellenreuther et al. in 1987 (14), although they did not describe the pulmonary alterations in detail. In our case, CT scans revealed the presence of multiple pulmonary infiltrates, and the cytological examination of the broncho-alveolar washing smears showed the prevalence of eosinophils. As all laboratory examinations were negative for other underlying disorders,

skin and pulmonary lesions may have a common aetiopathogenesis.

Clarithromycin was administered in our case, not only for the necessity of an antibiotic therapy to prevent severe pulmonary infection, but also for its well-known activity to inhibit the migration of eosinophils and to suppress bronchial hyper-responsiveness associated with eosinophilic inflammation in patients with asthma (15).

REFERENCES

1. Surks MI, Sievert R. Drugs and thyroid function. *N Engl J Med* 1995; 333: 1688–1694.
2. Schulz EJ, Whiting DA. Treatment of erythema nodosum and nodular vasculitis with potassium iodide. *Br J Dermatol* 1976; 94: 75–78.
3. Baumgartner TG. Potassium iodides and iododerma. *Am J Hosp Pharm* 1976; 33: 601–603.
4. Bernecker C. Intermittent therapy with potassium iodide in chronic obstructive disease of the airways. *Acta Allergol* 1969; 24: 216–225.
5. Hollander L, Fetterman GH. Fatal iododerma: the eleventh case reported in the literature. *Arch Derm Syph* 1936; 34: 228–241.
6. Soria C, Allegue F, Espana A, Rocamora A, Harton R, Ledo A. Vegetating iododerma with underlying systemic diseases: report of three cases. *J Am Acad Dermatol* 1990; 22: 418–422.
7. Vaillant L, Pengloan J, Blanchier D, De Muret A, Lorette G. Iododerma and acute respiratory distress with leucocytoclastic vasculitis following the intravenous injection of contrast media. *Clin Exp Dermatol* 1990; 15: 232–233.
8. Huang TY, Peterson GH. Pulmonary edema and iododerma induced by potassium iodide in the treatment of asthma. *Ann Allergy* 1981; 46: 264–266.
9. Rosenberg FR, Einbinder J, Walzer RA, Nelson CT. Vegetating iododerma: an immunologic mechanism. *Arch Dermatol* 1972; 105: 900–905.
10. Cape RDT. Iododerma of face and marked eosinophilia. *BMJ* 1954; 1: 255–257.
11. Stone OJ. Proliferative iododerma: a possible mechanism. *Int J Dermatol* 1985; 24: 565–566.
12. Eller JJ, Fox EC. Fatal iododerma. *Arch Derm Syphilol* 1931; 24: 745–757.
13. Miranda-Romero A, Sánchez-Sambucety P, Esquivias Gómez JI, Martínez Fernández M, Bajo del Pozo C, Aragonese Fraile H, et al. Vegetating iododerma with fatal outcome. *Dermatology* 1999; 198: 295–297.
14. Wellenreuther U, Toppe F, Haas N, Stüttgen G. Iodides végétantes après ingestion prolongée d'iode de potassium. *Ann Dermatol Venereol* 1987; 114: 1466–1467.
15. Amayasu H, Yoshida S, Ebana S, Yamamoto Y, Nishikawa T, Shoji T, et al. Clarithromycin suppresses bronchial hyperresponsiveness associated with eosinophilic inflammation in patients with asthma. *Ann Allergy Asthma Immunol* 2000; 84: 594–598.

Mirtazapine for Chronic Urticaria

Henrik Thormann and Carsten Bindslev-Jensen

Allergy Center, Department of Dermatology, Odense University Hospital, Odense C, Sdr. Boulevard 29, DK-5000 Odense, Denmark. E-mail: thormann@dadlnet.dk
Accepted April 13, 2004.

Sir,

Mirtazapine is a new drug used for major depression. It is a presynaptic central α_2 blocker which enhances noradrenergic and serotonergic neurotransmission. The raised serotonergic transmission works on the 5-HT1 receptors only, as the 5-HT2 and 5-HT3 receptors are blocked by mirtazepine (1).

We report two patients with chronic urticaria elicited by physical activities and one patient with delayed pressure urticaria where the psychotropic drug mirtazapine was tried. In two of the three patients the drug was effective.

CASE REPORTS

Case 1

A 36-year-old woman with a history of atopic dermatitis was referred with severe urticaria. Over the last 10 years the patient had suffered from recurrent, pruritic periorbital swelling up to twice weekly. The swelling prevented the patient from opening her eyes and was accompanied by sneezing. The symptoms were always elicited by physical activity or sweating. Activities such as a fast walking, skiing or use of solarium could trigger the symptoms. Swimming never elicited symptoms. For periods the patient was given prednisolone up to 30 mg daily with good effect, whereas antihistamines in standard dosages were without any effect.

The disease had had a dramatic impact on the patient's quality of life. Skin prick testing with the patient's own sweat was negative. Exercising on a bike for 30 min produced a severely itching periorbital oedema. No effect on this exercise-induced reaction was found by pre-treatment with atropine (0.3 mg s.c) or aspirin (1 g p.o.), but the patient's swelling could not be elicited by application of a 34°C warm towel on the patient's forehead. Fexofenadine (180 mg \times 2 p.o.), topical pimecrolimus and tacrolimus had no protective effect.

Two hours after intake of 30 mg mirtazapine the exercise test was repeated without eliciting any symptoms – skin prick testing with histamine hydrochloride 10 mg/ml was then negative.

The patient was treated with mirtazapine 30 mg daily for 2 weeks. No symptoms were elicited despite physical activities or sunbathing. As side effects a weight gain of 3 kg forced a reduction of mirtazapine dosage to 15 mg a day with sustained efficacy on symptoms.

For the first time during the last 10 years the patient

is now able to take part in all kinds of physical activities by taking 15 mg of mirtazapine 2–3 h prior to activity.

Case 2

A 39-year-old man was referred for treatment for severe delayed pressure urticaria of 3 years duration. The daily outbreaks of painful hives were localized to palms and soles and interfered with his work as an industrial painter. There was a dramatic improvement in symptoms in periods without work. Prior treatment included H1 antihistamines (loratadine 20 mg daily and fexofenadine 180 mg three times daily).

Montelukast, cyclosporine, azathioprine and loratadine were tried alone and in combination but with no effect. Methylprednisolone 80 mg i.m. had a dramatic but short-lived effect, whereas neither occlusive therapy with clobetasole nor plasmapheresis had any effect.

Mirtazapine 30 mg was then tried. After 2 weeks of treatment there was total absence of flares, swellings and pain from the areas usually involved. No delayed pressure urticaria was reported in the period. The patient had been able to work normally without restrictions. Adverse effects (change in mood and slight increase in weight) led to dose adjustment to 15 mg daily with sustained efficacy of the drug.

Case 3

A 40-year-old woman had a 7-year history of severe cold urticaria. The patient had been treated with different kinds of antihistamines without effect. The ice cube test was positive showing wheal and flare after 120 s of application.

The patient received mirtazapine 30 mg daily for 9 days and the tests were repeated. The reaction was still just as before mirtazapine intake with itch, oedema, wheal and flare. The conclusion was that mirtazapine did not have any effect on the patient's cold urticaria.

CONCLUSION

Mirtazapine demonstrates significant effect on the H1-receptor and has antipruritic activity (2, 3).

The drug was tried successfully in two of the three patients who all suffered from different types of severe urticaria. It has not previously been described in the treatment of chronic urticaria in the literature. We suggest mirtazapine to be tried in selected cases of severe urticaria.

REFERENCES

1. Anttila SA, Leinonen EV. A review of the pharmacological and clinical profile of mirtazapine. *CNS Drug Rev* 2001; 7: 249–264.
2. Mellar PD, Frandsen JL, Walsh D, Andresen S, Taylor S. Mirtazapine for pruritus. *J Pain Symptom Manage* 2003; 25: 288–291.
3. Twycross R, Greaves MW, Handwerker H, Jones EA, Libretto SE, Szepletowski JC, et al. Itch: scratching more than the surface. *Q J Med* 2003; 96: 7–26.

Solitary Premature Sebaceous Hyperplasia Associated with Acneiform Eruption

Moon Jung Choi, Jin Wou Kim and Bo Kyung Koh

Department of Dermatology, College of Medicine, the Catholic University of Korea, Uijongbu St Mary's Hospital, 65-1 Kumoh-dong, Uijongbu, Kyunggido, 480-130, Korea. E-mail: kohbo@catholic.ac.kr

Accepted April 13, 2004.

Sir,

Premature sebaceous gland hyperplasia (PSH) is a benign entity with an onset at puberty. It presents as multiple yellow papules on the face, neck and upper trunk. The absence of acneiform lesions has been regarded as one of the characteristics of this disorder. We report a man who simultaneously presented with a solitary PSH on the eyebrow and inflammatory papulopustules on the face.

CASE REPORT

An 18-year-old Korean man presented with a solitary yellow umbilicated papule 3 mm in diameter on his left eyebrow (Fig. 1). It had developed at the age of 8 and remained unchanged. A biopsy of the yellow papule showed mild acanthosis and sebaceous gland hyperplasia with normal cellular and glandular maturation (Fig. 2). There was no seasonal variation nor was there family history of similar skin problems. No evidence of a medical illness could be found. The patient also complained of multiple papulopustules on the face that had developed recently. He had not been treated previously for these lesions. No biopsy of the papulopustules on the forehead and cheeks was performed

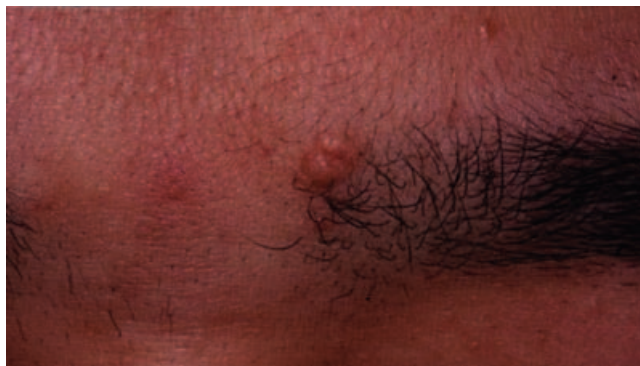

Fig. 1. A yellow papule, 3 mm in diameter, with a central umbilication on the medial side of the left eyebrow.

because they were clearly discriminated as those observed in acne vulgaris. The papule showed no evidence of recurrence during the 18 months follow-up.

DISCUSSION

Senile sebaceous hyperplasia is a benign condition that occurs in people over the age of 40, particularly in men. It presents as multiple yellowish papules or nodules on the face with central umbilication. It is a well-documented and frequently observed clinical condition. In contrast, PSH is a rare benign entity with an onset at puberty. It is characterized by multiple yellow papules on the face, neck and upper trunk. It is chronic and progressively worsens. The reported age of onset ranges from 12 to 26, with a mean age of 19.

In 1980, Dupre et al. (1) characterized this disorder as follows: an appearance during puberty or just afterwards, the selective localization on the face, neck and upper thorax, the lack of involvement of the peri-orificial regions, the absence of acneiform lesions, the slow progressive nature of the disorder ultimately leading to an extremely unpleasant appearance, the

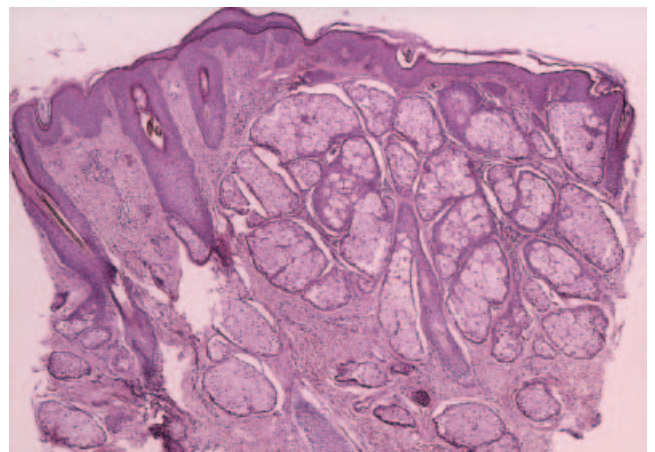


Fig. 2. Diffuse sebaceous gland hyperplasia with normal cellular and glandular maturation (H&E × 40).

ineffectiveness of conventional acne treatments and, histopathologically, a voluminous sebaceous hyperplasia with a lack of inflammation. Since Dupre et al.'s report, eight cases of PSH have been reported in the English literature and the authors have emphasized these characteristics as being essential diagnostic elements (2–5). Of the eight previously reported cases, there was one case with a simultaneous acneiform eruption (6). Our case had a solitary PSH on his eyebrow for 10 years and simultaneous acneiform lesions. We propose that the absence of an acneiform eruption is not essential for a diagnosis of PSH. A solitary PSH is rare, but it can develop as an early presentation of multiple PSH or as a solitary PSH itself. There is no report presenting as a solitary PSH.

REFERENCES

1. Dupre A, Bonafé JL, Lamon P. Functional familial sebaceous hyperplasia of the face. Reverse of the Cunliffe acne-free nevus? Its inclusion among naevoid sebaceous receptor diseases. *Clin Exp Dermatol* 1980; 5: 203–207.
2. Dupre A, Bonafé JL, Lamon P. Functional familial sebaceous hyperplasia of the face and premature sebaceous gland hyperplasia: a new and unique entity. *J Am Acad Dermatol* 1983; 9: 768–769.
3. Burton CS, Sawchuk WS. Premature sebaceous gland hyperplasia: successful treatment with isotretinoin. *J Am Acad Dermatol* 1985; 12: 182–184.
4. Grimalt R, Ferrando J, Mascaro JM. Premature sebaceous hyperplasia: successful response to oral isotretinoin in three patients. *J Am Acad Dermatol* 1997; 37: 996–998.
5. Bhawan J, Calhoun J. Premature sebaceous gland hyperplasia. *J Am Acad Dermatol* 1983; 8: 136.
6. Villez RL, Roberts LC. Premature sebaceous gland hyperplasia. *J Am Acad Dermatol* 1982; 6: 933–935.

Sequential Reactivation of Herpesvirus in Drug-induced Hypersensitivity Syndrome

Yoko Kano and Tetsuo Shiohara

Department of Dermatology, Kyorin University School of Medicine, 6-20-2 Shinkawa, Mitaka, Tokyo 181-8611, Japan. E-mail: kano@kyorin-u.ac.jp

Accepted May 3, 2004.

Sir,

Human herpesvirus 6 (HHV-6) reactivation has been implicated in the development of a drug-induced multi-organ system reaction that has been reported under a variety of names (1–3), such as anticonvulsant hypersensitivity syndrome and drug reaction with eosinophilia and systemic symptoms (DRESS). Recently we (2) and Hashimoto et al. (4) have demonstrated that HHV-6 reactivation is a reliable marker for an increased risk of developing this reaction and proposed to use the term 'drug-induced hypersensitivity syndrome (DIHS)'. We report here a patient with DIHS, in which not only anti-HHV-6 antibody titres but also other herpesvirus antibody titres were increased in sequential order during the course of the syndrome. Interestingly, similar sequential occurrence of herpesvirus reactivation has been well documented in immunocompromised patients after bone marrow transplantation (5, 6).

CASE REPORT

A 43-year-old man with a brain aneurysm had been treated with phenobarbital 300 mg daily. After 44 days, he noticed flu-like symptoms and erythematous rashes on his trunk. He was admitted to our hospital with suspicion of having acute hepatitis 3 days after the onset. Examination revealed a high-grade fever, bilateral cervical and inguinal lymphadenopathy, and hepatomegaly. No mucosal lesions were observed. Laboratory studies gave the following values: white

blood cell count $11.8 \times 10^9/l$ with eosinophil count $3.08 \times 10^9/l$; aspartate aminotransferase (AST) 273 IU/l (normal range 8–33); alanine aminotransferase (ALT) 770 IU/l (3–30); lactate dehydrogenase (LDH) 582 IU/l (200–470); C-reactive protein 12.7 mg/dl (<0.4). Serum IgG, IgA and IgM levels were 769 mg/dl, 47 mg/dl and 76 mg/dl (IgG 778–1794, IgA 80–413, IgM 37–254), respectively. A skin biopsy specimen obtained from the trunk revealed a dense infiltration consisting mainly of mononuclear cells and eosinophils in the upper dermis.

Generalized erythematous rashes coalesced to form erythroderma. The patient was treated with intravenous fluids for dehydration; neither systemic corticosteroids nor antibiotics were given during the admission period. Initially phenobarbital was not suspected as a causative drug, because the increased AST, ALT and LDH started to decrease after admission despite an increase in eosinophil number. These discrepant results are features of DIHS and often lead to a delay in diagnosis. Phenobarbital was finally discontinued, because his rash continued to deteriorate. Nevertheless, this was not followed by a prompt improvement of all symptoms, but 4 weeks later his manifestations finally subsided. Decreased serum immunoglobulin levels returned to normal 3 weeks after the onset.

Virological investigations were carried out on sequentially collected serum samples. The dramatic increase in anti-HHV-6 IgG titre was observed at first in the serum sample at 19 days after the onset. A similar increase was

detected in the anti-cytomegalovirus (CMV) IgM level. Anti-HHV-7 IgG titre was also markedly increased following the increase in HHV-6 IgG and CMV IgM levels. In contrast, no increases in either IgM or IgG antibodies against Epstein–Barr virus (EBV) or antibodies against EBV nuclear antigen were observed. Serological tests for hepatitis C virus, human immunodeficiency virus and human T-cell leukemia virus-1 were negative.

DISCUSSION

HHV-6 reactivation has frequently been observed in DIHS (1–3, 7, 8) but not in other severe drug-induced reactions, such as Stevens-Johnson syndrome and toxic epidermal necrolysis (9). Furthermore, recent articles have suggested that reactivation of other herpesviruses besides HHV-6 might also be involved in the development of DIHS (10, 11). We previously demonstrated that reactivation of HHV-7 together with HHV-6 occurred in a patient with DIHS (2). Aihara et al. (10) reported that reactivation of CMV, but not HHV-6, may occur in phenytoin-induced hypersensitivity syndrome. Descamps et al. (11) implicated EBV infection in the development of DIHS. HHV-7, CMV and EBV, along with HHV-6, are members of the herpesvirus family and share a propensity to cause illness characterized by fever and rash, and the capacity to reactivate under immunosuppressed conditions.

Considering the clinical similarity between DIHS and graft-versus-host disease (GVHD) (12) and the sequential occurrence of herpesvirus reactivation in these conditions, reactivation of HHV-6 and other herpesviruses may be responsible for the clinical manifestations of DIHS and result from immunosuppressive conditions. Indeed, we have provided evidence that DIHS could result when long-term use of anticonvulsants causes a decrease in immunoglobulin production and circulating B cells, probably via HHV-6 reactivation (9). If sequential reactivation is a possibility, then one may expect that higher incidence of HHV-6 reactivation detected around the third week after onset of DIHS may represent a secondary event that requires prior reactivation of other herpesviruses. Whether these herpesviruses reactivate from latency in obligate sequential order in DIHS, as demonstrated in GVHD (5, 6), is however unknown. A more frequent

sampling of serum samples and peripheral blood in patients with DIHS is required to better determine the ordered sequential reactivation of these herpesviruses.

REFERENCES

1. Descamps V, Bouscarat F, Laglenne S, Aslangul E, Descamps D, Sarau JL. Human herpesvirus 6 infection associated with anticonvulsant hypersensitivity syndrome and reactive haemophagocytic syndrome. *Br J Dermatol* 1997; 137: 606–608.
2. Suzuki Y, Inagi R, Aono T, Yamanishi K, Shiohara T. Human herpesvirus 6 infection as a risk factor for the development of severe drug-induced hypersensitivity syndrome. *Arch Dermatol* 1998; 134: 1108–1112.
3. Tohyama M, Yahata Y, Yasukawa M, Inagi R, Urano Y, Yamanishi K, et al. Severe hypersensitivity syndrome due to sulfasalazine associated with reactivation of human herpesvirus 6. *Arch Dermatol* 1998; 134: 1113–1117.
4. Hashimoto K, Yasukawa M, Tohyama M. Human herpesvirus 6 and drug allergy. *Curr Opin Allergy Clin Immunol* 2003; 3: 255–260.
5. Maeda T, Teshima T, Yamada M, Shinagawa K, Nakao S, Ohno Y, et al. Monitoring of human herpesviruses after allogeneic peripheral blood stem cell transplantation and bone marrow transplantation. *Br J Haematol* 1999; 105: 295–302.
6. Maeda T, Teshima T, Yamada M, Harada M. Reactivation of human herpesviruses after allogeneic peripheral blood stem cell transplantation and bone marrow transplantation. *Leuk Lymphoma* 2000; 39: 229–239.
7. Descamps V, Collot S, Mahe E, Houhou N, Crickx B, Ranger-Rogez S. Active human herpesvirus 6 infection in a patient with drug rash with eosinophilia and systemic symptoms. *J Invest Immunol* 2003; 121: 215–216.
8. Masaki T, Fukunaga A, Tohyama M, Koda Y, Okuda S, Maeda N, et al. Human herpes virus 6 encephalitis in allopurinol-induced hypersensitivity syndrome. *Acta Derm Venereol* 2003; 83: 128–131.
9. Kano Y, Inaoka M, Shiohara T. Association between anticonvulsant hypersensitivity syndrome and human herpesvirus 6 reactivation, and hypogammaglobulinemia. *Arch Dermatol* 2004; 140: 183–188.
10. Aihara M, Sugita Y, Takahashi S, Nagatani T, Arata S, Takeuchi K, et al. Anticonvulsant hypersensitivity syndrome associated with reactivation of cytomegalovirus. *Br J Dermatol* 2001; 144: 1231–1234.
11. Descamps V, Mahe E, Houhou N, Abramowitz L, Rozenberg F, Ranger-Rogez S. Drug-induced hypersensitivity syndrome associated with Epstein–Barr virus infection. *Br J Dermatol* 2003; 148: 1032–1034.
12. Appleton AL, Peiris JSM, Taylor CE, Sviland L, Cant AJ. Human herpesvirus 6 DNA in skin biopsy tissue from marrow graft recipients with severe combined immunodeficiency. *Lancet* 1994; 344: 1361–1362.

Granuloma Faciale Associated with Sinonasal Tract Eosinophilic Angiocentric Fibrosis

Patricia A.V. Chinelli, Milka Y. Kawashita, Mirian N. Sotto and Marcello M.S. Nico

Department of Dermatology, Hospital das Clinicas, Faculdade de Medicina, Universidade de Sao Paulo, I. Av dr Eneas de Carvalho Aguiar, 255, 05403-090 São Paulo, Brazil. E-mail: patchinelli@hotmail.com

Accepted May 12, 2004.

Sir,

Granuloma faciale (GF) is a chronic form of leukocytoclastic vasculitis of unknown origin and poorly understood pathogenesis characterized by red, violaceous or brownish macules, papules, plaques or nodules usually in the face. The course of the disease is chronic, there is no uniform response to any of the proposed therapies and spontaneous remission sometimes occurs (1, 2).

Eosinophilic angiocentric fibrosis (EAF) is an unusual fibrotic condition affecting the mucosa of the upper respiratory tract. It is characterized by a history of progressive nasal obstruction, affecting both nostrils and external swelling of the nose. Holmes & Panje (3) reported this entity for the first time in 1983 and called it 'intranasal granuloma faciale' and in 1985 Roberts & McCann (4) coined it as EAF. There are 15 case reports of EAF in the literature, 9 women and 6 men (4–12). The simultaneous occurrence of GF and EAF has been reported in only four cases (3, 4, 9, 12).

CASE REPORT

A 31-year-old Brazilian white woman had a 2-year history of cutaneous lesions. Clinical examination revealed severe brownish-red, infiltrated, indurated, well-circumscribed plaques with telangiectatic vessels on her back and face (Fig. 1), which had been slowly progressing in size. Bilateral nasal obstruction began in the previous year with progressive external swelling of the nose. The patient had no history of respiratory disease; she was taking no medication and was otherwise healthy.

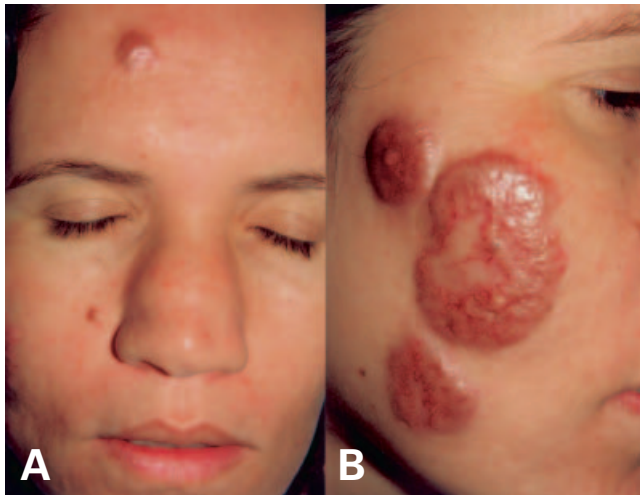


Fig. 1. Granuloma faciale lesion on the forehead and facial appearance of eosinophilic angiocentric fibrosis with external swelling of the nose (A) and chin (B). Permission given by the patient.

Biopsy specimens from cutaneous lesions showed a very dense polymorphous inflammatory infiltrate composed of polymorphonuclear leukocytes, lymphocytes, plasma cells and eosinophils distributed diffusely throughout the involved dermis with a narrow uninvolved grenz zone beneath the epidermis and around pilosebaceous follicles. There was also vessel wall damage and in places fibrinoid necrosis could be seen (Fig. 2A). In addition, some focal fibrosis was observed. Special stains for acid-fast bacilli and fungi were negative. Tissue cultures for mycobacteria, fungi and aerobic and anaerobic bacteria were also negative. The diagnosis of GF was made on the basis of the clinical picture, the histological findings and the negative microbial stains and culture results.

A video-assisted nasofibrosopic examination of the upper respiratory tract demonstrated partial obstruction of both nasal sinuses, with a thickened nasal septum. A CT scan showed thickening of soft tissues at the nasal fossa without osteolytic lesions. A nasal mucosal biopsy was performed and the histopathologic examination of the nasal mucosa showed a mild inflammatory infiltrate with lymphocytes and scant eosinophils in the subepithelial stroma and perivascular onion-skin fibrosis (Fig. 2B). Granulomas were absent. The

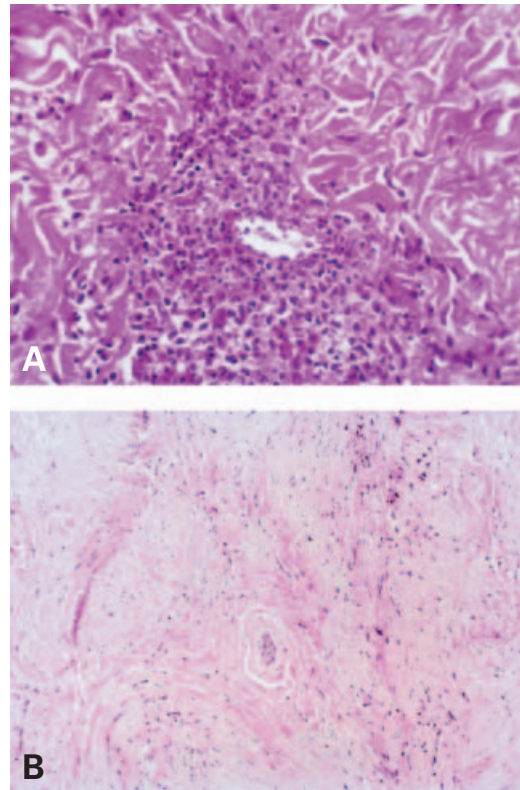


Fig. 2. Granuloma faciale: a dense polymorphous perivascular inflammatory infiltrate rich in eosinophils (A). Eosinophilic angiocentric fibrosis: inflammatory infiltrate with lymphocytes and scant eosinophils in the subepithelial stroma and perivascular hyalinizing onion-skin fibrosis (B). (H&E, $\times 200$ original magnification.)

septal cartilage was spared. These histological findings correspond to a later stage in the evolution of the EAF (5–8).

All laboratory tests, including differential blood counts, coagulation tests, ANCA, ANA, ESR, and serum electrophoresis were unremarkable.

Oral dapsone therapy was initiated at a dosage of 100 mg/day. Monthly intralesional injections of 5 mg/ml triamcinolone were administered to the cutaneous lesions. After eight injections the lesions showed significant improvement, leaving only red-brown atrophic residual lesions with a few telangiectatic vessels.

The patient did not want to be submitted for nasal surgery for the EAF and nasal injection of steroids was not done. Improvement in nasal obstruction was remarkable during dapsone treatment, and nasal breathing became possible. She has been followed up for 1 year now with no relapse.

DISCUSSION

GF occurs almost exclusively in the face. To our knowledge, only 14 previous cases of extrafacial lesions have been reported (13). Treatment with intralesional steroids provided good cosmetic and functional outcome in our case.

EAF is an extremely rare fibrosing lesion that mainly affects the sinonasal tract of young to middle-aged patients, leading to obstruction of the upper airways. There might also be epistaxis and pain. Clinical differential diagnosis of EAF includes Churg-Strauss syndrome, Wegener's granulomatosis, sarcoidosis, infectious granulomatous conditions and juvenile nasopharyngeal angiofibroma. Most of the above conditions have characteristic clinical and laboratory features (1, 8–10).

The aetiology of EAF remains obscure. The presence of eosinophils in the lesions, its predominance in women and a clinical history of allergy in some patients may suggest an allergic aetiology. Some patients have had a history of surgical procedures such as septal surgery before the diagnosis (4, 5) but no histopathological studies were performed prior to surgery. Besides, EAF generally does not appear to be a response to trauma (4, 6–10). The histopathologic studies of EAF show rich inflammatory infiltrate with eosinophilic vasculitis without necrosis in the early lesion and dense fibrosis, thickening of the subepithelial stroma with a characteristic obliterative perivascular onion skin whorling of collagen fibres and reticulin in the late lesion. There is thus considerable morphological similarity between GF and EAF.

Various treatments have been tried in EAF with only partial success, including surgical excision, which tends to lead to recurrence, and oral or intralesional steroid injections, with little or no response (5, 6, 8–10). Dapsone is known to improve neutrophil-mediated disorders such as GF and acute leukocytoclastic vasculitis (1, 14, 15). Dapsone interferes with neutrophil chemotactic migration, and suppresses local production

of toxic respiratory and secretory products, including oxygen-derived radicals (14, 15). In addition, this drug reduces the release of prostaglandins and leukotrienes, blocking their inflammatory effects (15).

The obstructive symptoms of EAF in our patient significantly improved with dapsone. These findings may also suggest an association between EAF and GF, which both run a chronic, indolent course, with considerable histological similarity, but occurring in different sites. If patients with GF have sinus symptoms, the diagnosis of EAF is very likely; conversely, if patients with suspected destructive sinopulmonary disease (i.e. Wegener or lymphoma) have cutaneous lesions, a biopsy is essential as the answer may be EAF and GF.

REFERENCES

- Guill MA, Aton JK. Facial granuloma responsive to dapsone therapy. *Arch Dermatol* 1982; 118: 332–335.
- Pedace FJ, Perry HO. Granuloma faciale. A clinical and histopathologic review. *Arch Dermatol* 1966; 94: 387–395.
- Holmes DK, Panje WR. Intranasal granuloma faciale. *Am J Otolaryngol* 1983; 4: 184–186.
- Roberts PF, McCann BG. Eosinophilic angiocentric fibrosis of the upper respiratory tract: a mucosal variant of granuloma faciale? A report of three cases. *Histopathology* 1985; 9: 1217–1225.
- Roberts PF, McCann BG. Eosinophilic angiocentric fibrosis of the upper respiratory tract: a postscript. *Histopathology* 1997; 31: 385–386.
- Matal V, Baer S, Barnes S, Boxer M. Pathology in focus. Eosinophilic angiocentric fibrosis. *J Laryngol Otol* 2000; 114: 563–564.
- Loane J, Jaramillo M, Young HA, Kerr KM. Eosinophilic angiocentric fibrosis and Wegener's granulomatosis: a case report and literature review. *J Clin Pathol* 2001; 54: 640–641.
- Thompson LDR, Heffner DK. Sinonasal tract eosinophilic angiocentric fibrosis. A report of three cases. *Am J Clin Pathol* 2001; 115: 243–248.
- Burns BV, Roberts PF, De Carpentier J, Zarod AP. Eosinophilic angiocentric fibrosis affecting the nasal cavity. A mucosal variant of granuloma faciale. *J Laryngol Otol* 2001; 115: 223–226.
- Pereira EM, Millas I, Reis-Filho JS, Maeda AS, Franco M. Eosinophilic angiocentric fibrosis of the sinonasal tract: report on the clinicopathologic features of a case and review of the literature. *Head Neck* 2002; 24: 307–311.
- Owa AO, Boyle S, Gallimore AP. Eosinophilic angiocentric fibrosis as a cause of nasal obstruction. *Rhinology* 2002; 40: 41–43.
- Tabae A, Zadeh MH, Proytcheva M, LaBruna A. Eosinophilic angiocentric fibrosis. *J Laryngol Otol* 2003; 117: 410–413.
- Inanir I, Alvir Y. Granuloma faciale with extrafacial lesions. *Br J Dermatol* 2001; 145: 360–362.
- Zhu YI, Stiller MJ. Dapsone and sulfones in dermatology: overview and update. *J Am Acad Dermatol* 2001; 45: 420–434.
- Coleman MD. Dapsone: modes of action, toxicity and possible strategies for increasing patient tolerance. *Br J Dermatol* 1993; 129: 507–513.

Female Androgenetic Alopecia Treated by Finasteride: A Case Forward

Rossano Valsecchi¹, Paolo Leghissa² and Matteo Riva²

Departments of ¹Dermatology and ²Occupational Medicine, Bergamo General Hospital, I-24100 Bergamo, Italy. E-mail: dermaambf@ospedaliriuniti.bergamo.it

Accepted May 14, 2004.

Sir,

A 54-year-old woman in good health presented in May 2002 with an 8-month history of progressive hair thinning and loss, particularly evident on the crown. Menopause started at the age of 51 years. She had no associated history of hirsutism or acne and there is no family history of androgenetic alopecia. She had no regular medication.

On physical examination, the patient showed a hair loss over the crown and frontal scalp, with a moderate frontal and temporal recession. Her history revealed two colourations with a hair-dye containing paraphenylenediamine during the past 3 months without side-effects. Her blood count, iron and ferritin levels, results of thyroid and liver function, prolactin levels, testosterone, dehydroepiandrosterone sulphate and sex-hormone-binding globulin levels were all within normal values. Computerized tomography scanning of the abdomen and a hysteroscopy showed no abnormalities. She had used topical treatment with 2% minoxidil solution for 8 months without effect.

The patient started treatment with finasteride 1 mg/day. The therapy was well tolerated with no side-effects. Her hair loss then stabilized after 8 months, and an improvement in hair density, compared with the baseline, was observed after 12–13 months of therapy (Fig. 1).

It is known that dihydrotestosterone (DHT) is the primary androgen implicated in the pathogenesis of androgenetic alopecia (1). It is formed by the peripheral conversion of testosterone by the enzyme 5 α -reductase. It has been shown that balding scalp skin contains increased DHT levels (2). These findings provided a rationale for the use of finasteride, specific inhibitor of

type 2 5 α -reductase, in the treatment of androgenetic alopecia. Shum et al. (3) described four women with central scalp hair loss who responded to finasteride 1.25 mg/day therapy for 24–30 months. All four patients had increased androgen levels, and were hirsute; in addition to the improvement of their alopecia, they showed improvement in their hirsutism. Thai & Sinclair (4) reported on finasteride in a 67-year-old woman with crown hair loss and normal androgen levels. They observed an increased hair density when using 5 mg/weekly for 12 months. A double-blind placebo-controlled and multicentre trial (5) evaluated the efficacy of finasteride 1 mg/day for 12 months in a group of post-menopausal women with androgenetic alopecia. The authors found that finasteride did not increase hair growth or slow the progression of hair thinning. In our patient, finasteride 1 mg/day was effective in stopping hair loss and in reversing the progress of alopecia. Most women with hair loss show no biochemical or clinical evidence of hyperandrogenism (6). Our case also had androgen levels within normal values.

The anecdotal case histories which have been reported, including the present one, could indicate that finasteride may cause hair growth in post-menopausal women with androgenetic alopecia and normal androgen levels. These few data about improvement of hair loss in post-menopausal women without hyperandrogenism could support the idea that not all types of hair loss in females have the same pathogenesis. On the other hand, we agree with Olsen et al. (7) that definitive data about finasteride treatment in female hair loss should be determined with a large and well controlled trial.

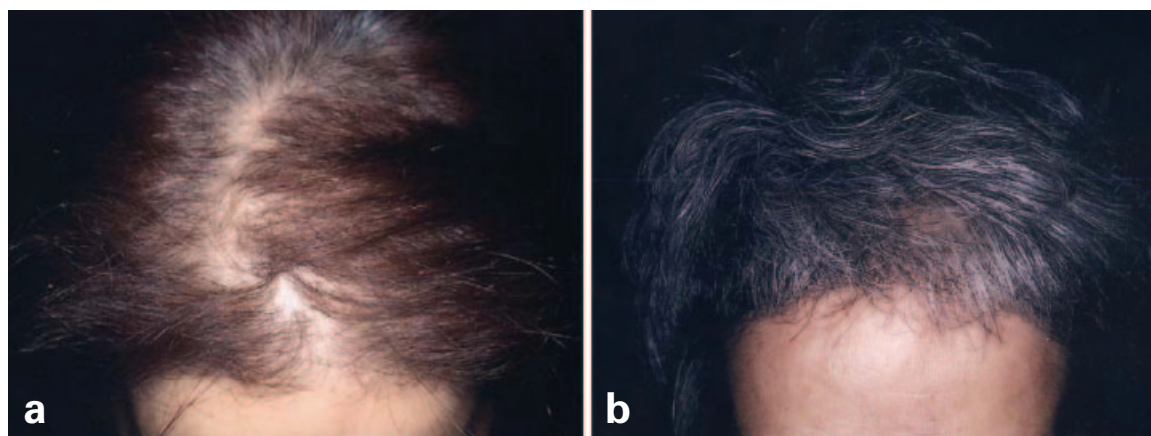


Fig. 1. The patient before (a) and after (b) finasteride treatment.

REFERENCES

1. Kaufman KD. Androgen metabolism as it affects hair growth in androgenetic alopecia. *Dermatol Clin* 1996; 14: 697–711.
2. Drake L, Hordinsky M, Fiedler V, Swinehart J, Unger WP, Cotterill PC, et al. The effects of finasteride on scalp skin and serum androgen levels in men with androgenetic alopecia. *J Am Acad Dermatol* 1999; 41: 550–554.
3. Shum KW, Cullen DR, Messenger AG. Hair loss in women with hyperandrogenism: four cases responding to finasteride. *J Am Acad Dermatol* 2002; 47: 733–739.
4. Thai KE, Sinclair RD. Finasteride for female androgenetic alopecia. *Br J Dermatol* 2002; 147: 812–813.
5. Price VH, Roberts JL, Hordinsky M, Olsen EA, Savin R, Bergfeld W, et al. Lack of efficacy of finasteride in post-menopausal women with androgenetic alopecia. *J Am Acad Dermatol* 2000; 43: 768–776.
6. Orme S, Cullen DR, Messenger AG. Diffuse female hair loss: are androgens necessary? *Br J Dermatol* 1999; 141: 521–523.
7. Olsen EA, Hordinsky M, Roberts JL, Whiting DA. Female pattern hair loss. *J Am Acad Dermatol* 2002; 47: 791.

Acquired Perforating Primary Osteoma Cutis

NagaPrasad Grandhe¹, Sunil Dogra¹, UmaNahar Saikia² and Sanjeev Handa^{1*}

Departments of ¹Dermatology, Venereology and Leprology and ²Pathology, Postgraduate Institute of Medical Education & Research, Chandigarh – 160 012, India. *E-mail: handa_sanjeev@yahoo.com
Accepted May 28, 2004.

Sir,

Osteoma cutis is a rare benign skin disorder characterized by bone formation in the dermis. Primary osteoma cutis represents 15% of all cases, having no prior underlying cutaneous disorder. The secondary form accounts for 85% of all cases, and occurs following inflammation from an underlying disorder (1, 2). Primary osteoma cutis can be divided into two subgroups: one in association with Albright's hereditary osteodystrophy (AHO) and the other without this association. Few authors restrict the use of the term 'osteoma cutis' to primary cutaneous ossification in which there is no evidence of AHO (3). We report an unusual case of plate-like primary osteoma cutis with onset in the fifth decade, which was progressive and not associated with any underlying cutaneous or systemic abnormalities.

CASE REPORT

A 50-year-old man presented with a rapidly growing asymptomatic linear plaque over the scalp of 1 year's duration. The lesions started as small grouped papulonodular lesions over the forehead, and rapidly grew in a linear fashion across the frontal and occipital scalp. The patient also noticed spontaneous ulceration in some of the lesions with chalky white discharge. No history of a prior traumatic or inflammatory process was forthcoming. He denied any systemic complaints. There was no family history of pseudohypoparathyroidism. Physical examination revealed multiple skin-coloured to erythematous hard papulonodular lesions arranged in a linear plaque, measuring about 20 × 3 cm, extending from forehead to occiput, just lateral to the midline on the right side (Fig. 1). The lesions were

mobile and not fixed to the underlying bone. There was extrusion of yellowish hard material through surface ulceration in some places. No other cutaneous abnormalities were detected. General physical, neurological and ophthalmic examinations were normal. Results of liver function tests, renal function tests, complete blood counts, serum calcium/phosphorus, parathyroid hormone and thyroid stimulating hormone (TSH) were normal. Roentgenographic examination of the skull showed faint radiodense lesions in the underlying soft tissue. A biopsy of the skin lesion revealed normal epidermis except at the areas of ulceration and foci of mature bone formation surrounding the appendages in the dermis. The osseous tissue showed a number of osteocytes enclosed within their individual lacunae (Fig. 2). With this clinical morphology and histological findings, a diagnosis of plate-like osteoma cutis was established.

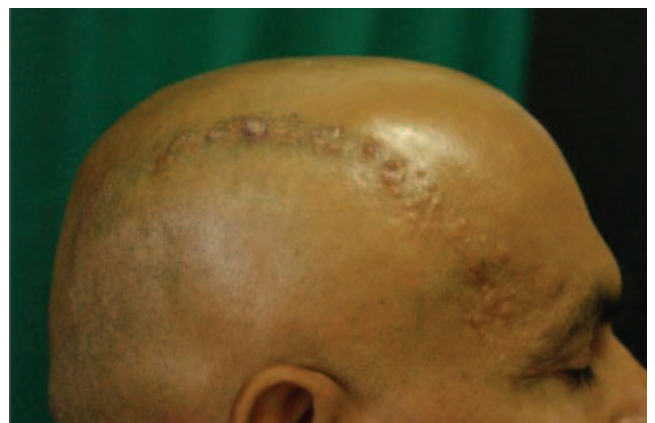

Fig. 1. Papulonodular lesions present in a linear plaque over scalp.

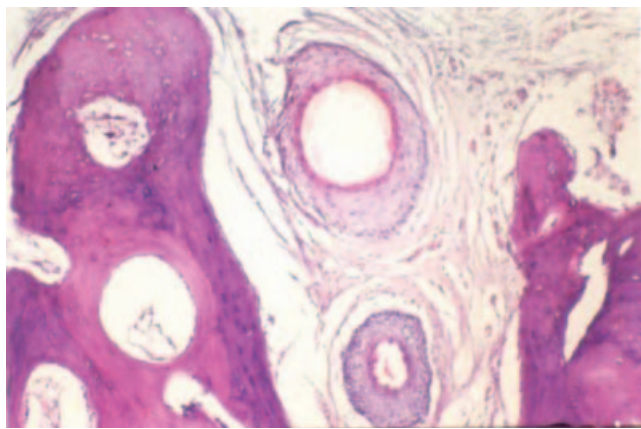


Fig. 2. Photomicrograph showing mature lamellar bone entrapping the hair follicles (H&E \times 540).

DISCUSSION

The exact histogenesis of bone formation in osteoma cutis is not known. The current speculated hypothesis is that the fibroblasts have the ability to differentiate into osteoblast cells, but the stimulus for this remains unknown (4). Histologically primary osteoma cutis shows mature spongy bone located in the dermis and subcutis. In case of secondary osteomas, the calcified tissue shows neither lamellar nor osteogenic organization.

Clinically there are four subtypes of primary osteoma cutis: isolated osteoma, generalized or widespread osteoma, multiple miliary osteoma of the face and plate-like cutaneous osteoma (4). Worret & Burgdorf (5) first introduced the term congenital plate-like cutaneous osteoma according to the following diagnostic criteria: lesions present at birth or within the first year of life, no evidence of abnormal calcium or phosphorus metabolism, absence of infection, trauma or other predisposing events and the presence of at least one bony plate with or without other cutaneous osteomas. Clinically plate-like osteoma cutis presents as asymptomatic, usually single, occasionally multiple, skin-coloured papulonodular lesions forming plaques with stony hard consistency. The size of the lesions can vary from 1 to 15 cm. The scalp was the most frequently involved site in the majority of the published reports, followed by the limbs and trunk (6). The tumour is usually benign, localized, and grows slowly without any associated physical or endocrine abnormality. A recently described entity 'progressive osseous heteroplasia', in which progressive cutaneous ossification occurs in deeper tissues like muscle or fascia, is considered a variant of plate-like osteoma cutis (7).

Wide surgical excision is the definitive treatment for primary plate-like osteoma cutis.

As there was no clinical and histopathological evidence of any underlying cutaneous pathology, the index case was diagnosed as primary osteoma cutis. Further, the presence of mature bone in histopathological sections, absence of any stigmata of AHO or feature of fibrodysplasia ossificans progressiva, myositis ossificans progressiva or other hormonal disturbances confirmed the diagnosis of primary osteoma cutis.

According to Worret & Burgdorf (5), primary plate-like cutaneous osteoma usually presents after birth or within the first year of life. Our case can be considered as an exception in this regard. To the best of our knowledge, ours is the first case of primary plate-like cutaneous osteoma with onset in the fifth decade. Rapid progression is another unique feature of our case. All the reported cases of primary plate-like osteoma cutis have been localized and non-progressive except a single case reported by Davis et al. (8), which was associated with dysmorphic features. We have excluded the possibility of progressive osseous heteroplasia as deeper structures were spared. Perforating lesions, which are not frequently seen with primary plate-like osteoma cutis, are another interesting feature of our case.

REFERENCES

1. Monroe AB, Burgdorf WH, Sheward S. Plate-like cutaneous osteoma. *J Am Acad Dermatol* 1987; 16: 481–484.
2. Roth SL, Stowell RE, Helwig EB. Cutaneous ossification. Report of 120 cases and review of the literature. *Arch Pathol* 1963; 76: 44–53.
3. Orlow SJ, Watsky KL, Bolognia JL. Skin and bones. II. *J Am Acad Dermatol* 1991; 25: 447–462.
4. Oikarinen A, Tuomi ML, Kallionen M, Sandberg M, Vaananen K. A study of bone formation in osteoma cutis employing biochemical, histochemical and in situ hybridization techniques. *Acta Derm Venereol* 1992; 72: 172–174.
5. Worret WI, Burgdorf WH. Congenital plate-like osteoma of the skin in an infant. *Hautarzt* 1978; 29: 590–596.
6. Sanmartin O, Alegre V, Martinez-Aparicio A, Botella-Estrada R, Aliaga A. Congenital plate-like osteoma cutis: case report and review of the literature. *Pediatr Dermatol* 1993; 10: 182–186.
7. Miller ES, Esterly NB, Fairley JA. Progressive osseous heteroplasia. *Arch Dermatol* 1996; 132: 787–791.
8. Davis MD, Pittelkow MR, Lindor NM, Lundstrom CE, Fitzpatrick LA. Progressive extensive osteoma cutis associated with dysmorphic features: a new syndrome? Case report and review of the literature. *Br J Dermatol* 2002; 146: 1075–1080.

Dramatic Efficacy of Oral Aromatic Retinoid in Long-standing Hypertrophic Lupus Erythematosus

Satoko Shimizu, Chikako Yasui, Hiroyuki Kawasaki and Kikuo Tsuchiya

Department of Dermatology, Sapporo City General Hospital, North 11, West 13, Chuo-Ku, Sapporo 060-8604, Japan. E-mail: satoko.shimizu@nifty.com

Accepted May 24, 2004.

Sir,

In 1940, Bechet described hypertrophic lupus erythematosus (LE) as a variant of discoid lupus erythematosus (DLE) characterized by erythematous verrucous plaques with indurated borders (1). Similar lesions were also described as verrucous LE (2, 3), or keratotic LE (4). Hypertrophic LE accounted for 2% of chronic LE (5). Various treatments have been tried including intralesional corticosteroids, hydroxychloroquine (2), retinoids (4, 6), thalidomide (7) and cryotherapy (8); however, hypertrophic LE is often resistant to these treatments. Here, we describe a patient with hypertrophic LE who was refractory to various treatments over a period of 24 years, but responded quickly to oral etretinate.

CASE REPORT

The patient is a 58-year-old Japanese woman. At the age of 28, she experienced a recurrent fever, malar erythema, photosensitivity, arthralgia, proteinuria and chilblain lupus and was diagnosed as having systemic LE (SLE). The activity of SLE was well controlled after systemic corticosteroid therapy was started and no systemic manifestations except arthralgia were observed. At the age of 34, 6 years after the onset of SLE, itchy hyperkeratotic plaques gradually appeared on her extremities. These lesions never disappeared despite dapsone, antihistamine, topical and occlusive corticosteroids and topical tacrolimus treatments, but were moderately controlled with 12.5–20 mg/day of prednisolone which was prescribed for almost 24 years. Several trials of tapering prednisolone below 10 mg/day always led to marked worsening of the skin lesions and especially the pruritus, which caused sleeping problems.

At the age of 58, she was admitted to hospital for a re-evaluation of her condition and for a new treatment trial.

Physical examination revealed red or depigmented hyperkeratotic nodules and plaques up to 8 cm in diameter on the extensor surface of the extremities, especially on the back of hands, elbows and knees (Fig. 1). The lesions were extremely itchy. Classical DLE lesions without any marked hyperkeratosis were also present on her back. A routine laboratory examination revealed that blood counts and liver function were within normal limits. The anti-nuclear antibody titre was positive at 1:160 and showed a homogeneous pattern. Anti-Ro/SSA antibodies and lupus anticoagulant were also positive. Anti-double strand DNA antibody, anti-RNP antibody, anti-La/SSB antibody, Sm antibody and anti-cardiolipin antibody titres were negative. Complement was within normal levels.

Histologically, the specimen taken from a hyperkeratotic nodule on the knee showed marked hyperkeratosis, irregular acanthosis and elongation of the rete ridge with a band-like mononuclear cell infiltrate in the upper dermis. Basement membrane thickening and hydropic degeneration of the basal keratinocyte layer was also observed. Direct immunofluorescence demonstrated a granular deposition of complement at the dermal-epidermal junction. These findings were consistent with hypertrophic LE. The specimen taken from the back with classic DLE characteristics showed the typical pathological features expected for DLE, including thinning of the epidermis, orthohyperkeratosis, follicular plugging, vacuolar degeneration and mucin deposition.

Due to the severe itching, etretinate 30 mg/day was added to the prednisolone dose (12.5 mg/day). Surprisingly, the intense pruritus showed a dramatic improvement over the next 4 days, and the hyperkeratosis associated with the hypertrophic LE also began to decrease. After 10 days, the hypertrophic LE lesions went into remission leaving depigmented maculas only. No major side effects were observed except for cheilitis, which cleared after the dose of etretinate was decreased to 10 mg/day. The DLE on the patient's back disappeared more gradually over a period of 6 months.

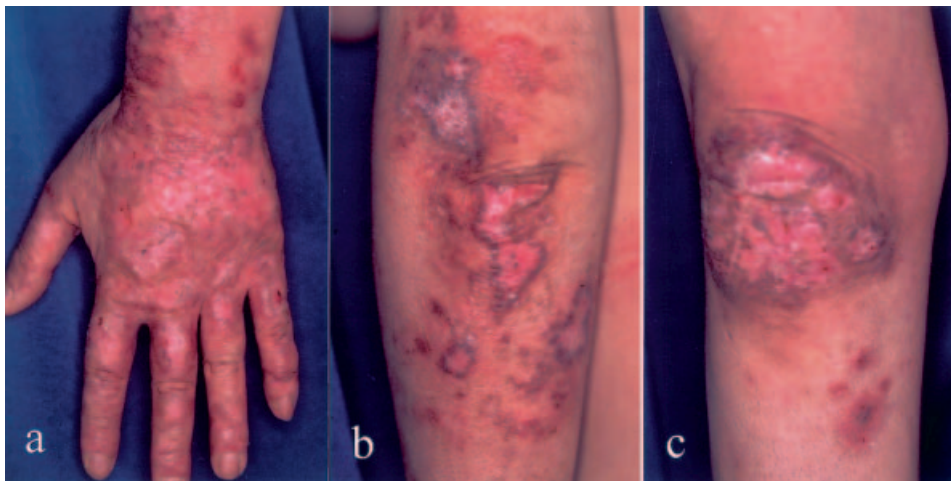


Fig. 1. The clinical appearance of hypertrophic lupus erythematosus on the hand (a), the elbow (b) and the knee (c) before etretinate therapy.

DISCUSSION

Hypertrophic LE histologically shows marked acanthosis, hyperkeratosis and hypergranulosis with a mononuclear cell infiltrate. The histological picture is variable and sometimes described as keratoacanthoma-like or hypertrophic lichen planus-like with a band-like mononuclear infiltrate (3). As in previous case reports (2, 3), our patient clinically showed typical DLE on her back in association with hypertrophic LE on the extremities. These lesions were refractory to various treatments including systemic prednisolone for more than 20 years; however, they showed a dramatic and complete response to etretinate.

According to a Medline search, only 50 cases of hypertrophic LE have been reported from 1963 to 2003. Of these, we reviewed 25 case reports where the treatment was described (2, 4, 6–13). Seventeen of the patients were women and the mean age at onset was 40.4 years. Hypertrophic LE usually occurred after a long previous history of cutaneous LE, although a few abrupt onsets were also reported. Only 5 of 25 patients with hypertrophic LE were diagnosed as suffering from SLE, i.e. fulfilling at least 4 of the American College of Rheumatology criteria (11, 12).

Various treatments have been tried for hypertrophic LE, such as antimalarial drugs, prednisolone, dapsone and intra-lesional corticosteroids. However, in the reviewed 25 cases the treatment did not always lead to any good results and was restricted by side effects and contraindications. Antimalarials and thalidomide are considered to be among the best systemic therapies for classic DLE but are not always effective for the hypertrophic LE forms (2, 7). Besides, antimalarials and thalidomide are not available in some countries, including Japan.

In the present case, the aromatic retinoid etretinate, which is still the only oral retinoid available in Japan, proved highly effective; the hyperkeratotic nodules and severe intolerable pruritus disappeared promptly with a low dosage. The efficacy of etretinate and its major metabolite, acitretin, has been studied in patients with cutaneous LE (14) but their efficacy in hypertrophic LE was only reported once before (15). Only rarely have topical tretinoin (6) and systemic isotretinoin (4, 12) been used in hypertrophic LE.

The exact mechanism of action of etretinate in hypertrophic LE is still unknown. The inhibition of epidermal proliferation by retinoids as well as the immunomodulatory effects (16) may be important in treating hypertrophic LE. Although the use of etretinate and acitretin is restricted for young women due to teratogenic effects, hypertrophic LE usually appears at

a higher age, following long-term classic DLE, thus obviating such contraindications.

REFERENCES

1. Bechet P. Hypertrophic lupus erythematosus. *Arch Dermatol Syph* 1940; 42: 211.
2. Uitto J, Santa-Cruz DJ, Eisen AZ, Leone P. Verrucous lesion in patients with discoid lupus erythematosus. Clinical, histopathological and immunofluorescence studies. *Br J Dermatol* 1978; 98: 507–520.
3. Santa Cruz DJ, Uitto J, Eisen AZ, Prioleau PG. Verrucous lupus erythematosus: ultrastructural studies on a distinct variant of chronic discoid lupus erythematosus. *J Am Acad Dermatol* 1983; 9: 82–90.
4. Rubenstein DJ, Huntley AC. Keratotic lupus erythematosus: treatment with isotretinoin. *J Am Acad Dermatol* 1986; 14: 910–914.
5. Sontheimer RD. The lexicon of cutaneous lupus erythematosus – a review and personal perspective on the nomenclature and classification of the cutaneous manifestations of lupus erythematosus. *Lupus* 1997; 6: 84–95.
6. Seiger E, Roland S, Goldman S. Cutaneous lupus treated with topical tretinoin: a case report. *Cutis* 1991; 47: 351–355.
7. Georgala S, Katoulis AC, Hasapi V, Koumantaki-Mathioudaki E. Thalidomide treatment for hypertrophic lupus erythematosus. *Clin Exp Dermatol* 1998; 23: 141.
8. Molin L, Tarstedt M. Discoid lupus erythematosus treated with cryotherapy. *J Dermatol Treat* 2003; 14: 182–183.
9. Howitz J, Ullman S. Lupus erythematosus hypertrophicus: a case report. *Acta Derm Venereol* 1978; 58: 90–91.
10. John MD, Gruber GG, Turner JE, Callen JP. Lupus erythematosus hypertrophicus. Two case reports and a review of the literature. *Cutis* 1981; 28: 290–292, 300.
11. Spann CR, Callen JP, Klein JB, Kulick KB. Clinical, serologic and immunogenetic studies in patients with chronic cutaneous (discoid) lupus erythematosus who have verrucous and/or hypertrophic skin lesions. *J Rheumatol* 1988; 15: 256–261.
12. Green SG, Piette WW. Successful treatment of hypertrophic lupus erythematosus with isotretinoin. *J Am Acad Dermatol* 1987; 17: 364–368.
13. Perniciaro C, Randle HW, Perry HO. Hypertrophic discoid lupus erythematosus resembling squamous cell carcinoma. *Dermatol Surg* 1995; 21: 255–257.
14. Ruzicka T, Sommerburg C, Goerz G, Kind P, Mensing H. Treatment of cutaneous lupus erythematosus with acitretin and hydroxychloroquine. *Br J Dermatol* 1992; 127: 513–518.
15. Grupper C, Berretti B. Lupus erythematosus and etretinate. In: Cunliffe WJ, Miller A, eds. *Retinoid therapy: a review of clinical and laboratory research*. New York: Springer-Verlag, 1984: 73–81.
16. Peck G, DiGiovanna JJ. The retinoids. In: Freedberg I, Eisen A, Wolff K, Austin K, Goldsmith L, Katz S, et al., eds. *Fitzpatrick's dermatology in general medicine*, 5th edn. New York: McGraw-Hill, 1999: 2810–2820.

Two Cases of Alopecia Areata associated with Takayasu Arteritis

Motonobu Nakamura and Yoshiaki Miyachi

Department of Dermatology, Graduate School of Medicine, Kyoto University, Shogo-in Kawahara-cho 54, Sakyo-ku, Kyoto, 606-8507, Japan. E-mail: motonaka@kuhp.kyoto-u.ac.jp

Accepted May 24, 2004.

Sir,

Takayasu arteritis is a rare form of vasculitis that involves the aorta and its proximal branches (1). It shows characteristic histological changes of a granulomatous panarteritis with a patchy inflammatory infiltrate of lymphocytes, plasma cells, macrophages and giant cells, resulting in ischaemia of the internal organs triggered by a narrowing of the arteries. Eichhorn et al. (2) detected anti-endothelial cell antibodies (AECA) in the sera of 18 of 19 patients with Takayasu arteritis and proposed that autoimmunity is involved in the pathogenesis. Recently, Tripathy et al. (3) reported that 43% of Takayasu arteritis patients were positive for antimonocyte antibodies. We present two cases of alopecia areata associated with Takayasu arteritis.

CASE REPORTS

Case 1

A 29-year-old woman presented with multiple alopecic lesions on the scalp. She had first noticed alopecia areata 20 years ago. Alopecia areata developed into alopecia totalis, which is resistant to any topical therapy. At the age of 16, she suffered from high fever and symmetrical pain in her knees, elbows and neck. Aortogram examination demonstrated stenosis of the right axillary artery, which was followed by a diagnosis of Takayasu arteritis. With oral prednisolone 30 mg/day, both fever and pain resolved within days. In addition, her alopecia totalis was completely cured in a few months. Due to a recurrence of Takayasu arteritis, she took at least prednisolone 15 mg/day for more than 10 years. Recently, when prednisolone was reduced to 9 mg/day, multiple alopecic areas emerged suddenly. Increase of prednisolone to 15 mg/day resulted in a resolution of alopecia areata.

Case 2

A 38-year-old woman was referred to our clinic because of alopecia areata noticed just a few days earlier. Examination confirmed a single patch of non-scarring alopecia areata of 3 cm in diameter on her occipital scalp. She had no history of trauma in that region. She had felt bilateral back pain and clubbing of the fingers in both hands for the past 20 years. Close examination had revealed pulselessness in both arms and aortography had demonstrated the occlusion and narrowing of the main branches arising from the

aortic arch. A diagnosis of Takayasu arteritis had been made and oral prednisolone had resolved its symptoms. When prednisolone was reduced from 50 mg to 25 mg, she developed alopecia areata, which was resistant to topical therapy.

DISCUSSION

The cause of alopecia areata remains obscure, but immunological mechanisms are likely to play important roles (4). Immunohistochemical studies have shown that both CD4-positive and CD8-positive T cells infiltrate in and around hair follicles. Aberrant expression of HLA and ICAM-1 in the hair follicles was found in patients with alopecia areata, which may induce the T-cell infiltration. The serum levels of interferon-gamma and interleukin-2 are significantly elevated in patients with the extensive form of alopecia areata (5). Contact allergen immunotherapy reduces the number of these peribulbar T cells resulting in hair growth. Tobin et al. (6) found antibodies in sera from alopecia areata patients which bind to extracts of human anagen follicles. In addition, alopecia areata has been reported in association with atopic dermatitis and numerous autoimmune diseases.

Our two cases of alopecia areata were both resistant to topical corticosteroid therapy, were associated with Takayasu disease, and occurred when the amount of oral prednisolone was reduced. Speculatively, autoantibodies to both hair follicles and endothelial cells may induce the expression of adhesion molecules like ICAM-1, which facilitates the accumulation of T cells around hair follicles and arteries.

Takayasu arteritis can involve cutaneous vessels and can simulate erythema nodosum, erythema induratum and pyoderma gangrenosum (7). Such cutaneous manifestations are called 'specific' and are characterized histologically by several kinds of vasculitis (7). The association of Takayasu arteritis with alopecia areata in our study may be categorized as 'non-specific'.

REFERENCES

1. Ishikawa K, Maetani S. Long-term outcome for 120 Japanese patients with Takayasu's disease. *Circulation* 1994; 90: 1855–1860.
2. Eichhorn J, Sima D, Thiele B, Lindschau C, Turowski A, Schmidt H, et al. Anti-endothelial cell antibodies in Takayasu arteritis. *Circulation* 1996; 94: 2396–2401.
3. Tripathy NK, Sinha N, Nityanand S. Antimonocyte antibodies in Takayasu's arteritis: prevalence of and relation to disease activity. *J Rheumatol* 2003; 30: 2023–2026.

4. Messenger AG, Simpson NB. Alopecia areata. In: Dawber R, ed. *Diseases of the hair and scalp*. Oxford: Blackwell Scientific Publications, 1997: 338–369.
5. Teraki Y, Imanishi K, Shiohara T. Cytokines in alopecia areata: contrasting cytokine profiles in localized form and extensive form (alopecia universalis). *Acta Derm Venereol* 1996; 76: 421–423.
6. Tobin DJ, Orentreich N, Fenton DA, Bystryn JC. Antibodies to hair follicles in alopecia areata. *J Invest Dermatol* 1994; 102: 721–724.
7. Pascual-López M, Hernández-Núñez A, Aragüés-Montañés M, Daudén E, Fraga J, García-Díez A. Takayasu's disease with cutaneous involvement. *Dermatology* 2004; 208: 10–15.

Photolocalized Varicella

Tatiana C. Nogueira Varella and Maria C. Rivitti Machado

Division of Dermatology, Hospital das Clínicas, University of São Paulo, Avenida Dr Enéas de Carvalho Aguiar, 250, 3° andar, Jardim Paulista, Cep. 05403-000, São Paulo, SP, Brazil. E-mail: tativarella@hotmail.com

Accepted May 28, 2004.

Sir,

Varicella usually presents as a typical vesicular exanthem but unusual forms may occur and have been associated with immunosuppression, pre-existing dermatosis, sun exposure and skin injuries. We report an atypical case of varicella with lesions localized in sun-exposed areas.

CASE REPORT

A 5-year-old girl presented with a vesicular eruption accompanied by fever. Her history revealed contact with other children with varicella. According to her mother, the lesions spread within 48 h and the patient had received extensive sun exposure 6 days before the exanthem. On physical examination the eruption consisted of many vesicles which had started on the trunk, markedly accentuated in sun-exposed areas, spreading then to the face, arms, legs and mucosal surfaces (Fig. 1). The lesions appeared to be at the same stage of evolution and many were umbilicated. Laboratory evaluation consisting of urinalysis, blood cell count and chemistry panel yielded normal results. Chest X-ray was normal. Tzanck preparation from a vesicular lesion demonstrated multinucleated giant cells. The patient was treated with oral acyclovir. On day 4 of hospitalization, her lesions began to crust and fever resolved. At that time, serological test was positive for IgM and IgG varicella zoster antibody. The patient's skin healed without scarring and recovery was complete.

DISCUSSION

In 1973, Castrow & Wolf (1) reported the first case of varicella limited to an area of mild sunburn and suggested the term photolocalization. Since the initial description, we have been able to find 14 subsequently reported cases (2–11). Patients who are sun-exposed while incubating varicella-zoster can present with a markedly photodistributed exanthem. Unlike more

typical varicella, photo-induced chickenpox may display lesions in a simultaneous stage. Lesions may be larger, the disease more fulminant and the typical centripetal spread less prominent. Because photolocalized varicella may be more severe than routine chickenpox, acyclovir may be a potential treatment.

Several hypotheses have been formulated to explain varicella's predilection for sun-exposed skin. The inflammatory changes of ultraviolet light can increase capillary permeability and, when viraemia occurs, varicella-zoster virus may be selectively distributed in these areas of increased permeability. A second hypothesis suggests that ultraviolet radiation damages

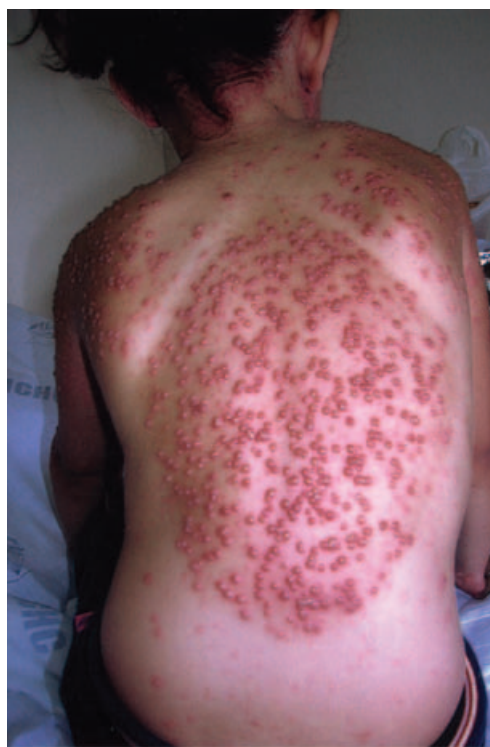

Fig. 1. Large lesions localized in sun-exposed areas, in a simultaneous stage.

host cell membranes and increases local temperature, therefore decreasing local immune response, allowing rapid proliferation of varicella-zoster virus. Another hypothesis suggests that exposure to ultraviolet radiation can cause local and systemic cell-mediated immunosuppression (2).

One situation where sunlight plays a role is in acting as a trigger for the reactivation from the latency of herpes simplex virus, possibly a temporary depression in local cutaneous immunity.

In conclusion, we suggest that sun exposure may modify the clinical presentation of varicella, and photolocalization of chickenpox is an unusual and probably underdiagnosed presentation of this common viral disease.

REFERENCES

1. Castrow FF, Wolf JE. Photolocalized varicella. *Arch Dermatol* 1973; 107: 628.

2. Gilcrest B, Baden HP. Photodistribution of viral exanthems. *Pediatrics* 1974; 54: 136–138.
3. Muckle TJ. Suntan localization of varicella exanthem. *Cutis* 1978; 21: 347–349.
4. Newell GB. Photolocalized varicella. *J Ky Med Assoc* 1978; 76: 443–444.
5. Findlay GH, Forman L, Hull PR. Actinic chickenpox. Light-distributed varicella eruption. *S Afr Med J* 1979; 55: 989–991.
6. Serrano G, Aliaga A, Bonillo J, Pelufo C, Otero D. Photodistribution of varicella exanthem: report of two cases. *Pediatr Dermatol* 1986; 3: 215–218.
7. Feder HM Jr, Luchetti ME. Varicella mimicking a vesiculobullous sun eruption. *J Infect Dis* 1988; 158: 243.
8. Boyd AS, Neldner KH. Photolocalized varicella in an adult. *JAMA* 1991; 266: 2204.
9. Boyd AS, Neldner KH, Zemtsov A, Shihada B. Photolocalized varicella. *J Am Acad Dermatol* 1992; 26: 772–774.
10. Ridgway D, Avera SP, Jaffe A. Actinic varicella. *Pediatr Infect Dis J* 1996; 15: 921–922.
11. White SM, Gupta SM, Tager P, Don PC, Weinberg JM. Photolocalized varicella in a middle-aged adult. *Cutis* 2000; 62: 199–200.

Multiple Halo Naevi associated with Carcinoid in a Young Man

Olivier Dereure¹, Françoise Guillon², Bernard Guillot¹ and Jean-Jacques Guilhou¹

Departments of ¹Dermatology and ²Digestive Surgery, University Hospital of Montpellier, Hôpital Saint-Eloi, 80 avenue A. Fliche, FR-34295 Montpellier Cedex 5, France. E-mail: o-dereure@chu-montpellier.fr
Accepted May 28, 2004.

Sir,

Halo naevus (HN), also named Sutton's naevus, is characterized by the occurrence of a depigmented, vitiligo-like halo around a melanocytic naevus. They are relatively common in children, teenagers and young adults, most often solitary or in limited number. They are not associated with other disorders according to the literature, except for very rare cases of malignant melanoma either in the HN itself or located elsewhere (1–7). We here report on an unusual association of multiple HN with a benign carcinoid tumour of the ileum, which raises the possibility of a cell-mediated reaction directed against two lesions sharing a common embryonic origin.

CASE REPORT

A 27-year-old man without any remarkable medical history including pigmentation disorders was referred for multiple HN (Fig. 1), which had occurred simultaneously within the previous 18 months. Physical examination disclosed more than 50 HN mainly located on the trunk and without associated vitiligo. He was otherwise healthy with no lesions suspicious of melanoma on skin, or oral or conjunctival mucous membranes. Routine biochemical tests were unremarkable. A biopsy from an achromic halo displayed the

disappearance of pigmented cells and a slight inflammatory infiltrate of mononucleated cells in the upper dermis. Specialized ocular, nasal and pharyngeal

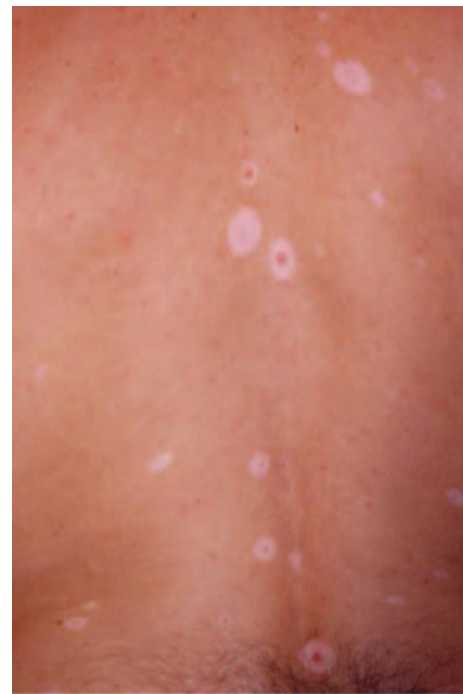

Fig. 1. Multiple halo naevi of the trunk.

investigations and upper aero-digestive tract endoscopy were normal. Abdominal ultrasound and CT scan showed a well-defined nodule in the terminal ileum, 2 cm in diameter, with slightly enlarged regional nodes. A colonoscopy uncovered a non-ulcerated nodule diagnosed as a well-differentiated carcinoid tumour through multiple biopsies. Subsequent bronchoscopy was normal and the reappraisal of clinical and biochemical data did not disclose any carcinoid syndrome or elevated levels of serotonin and its main metabolite, 5-hydroxy-indol acetic acid, in blood and urine. The ileal nodule was subsequently removed through video-assisted endoscopic surgery and the diagnosis of well-encapsulated, non-infiltrating benign carcinoid tumour was fully confirmed without any cytological atypia. Some of the enlarged regional lymph nodes were removed during the same procedure, but proved normal. There was no repigmentation of the achromic areas. New HN lesions did not occur up to 14 months after removal of the tumour.

DISCUSSION

Mechanisms leading to HN occurrence are still a matter of debate, but the main hypothesis involves a cellular immune response targeting the pigmented cells, perhaps elicited in some cases by the presence of abnormal, probably premalignant melanocytes either inside the HN itself or at some distance (8). However, the association with malignant melanoma seems quite rare since less than 10 cases have been reported including 5 cases of HN occurring around melanoma arising from a previous naevus (with one congenital naevus) (1–3, 6–7), two cases occurring after surgical removal of a cutaneous melanoma (5), and one case accompanying an ocular melanoma (4). On the other hand, it has been suggested that the presence of an associated melanoma should be more strongly suspected if vitiligo-like lesions were also present elsewhere. However, this opinion is not really supported by clinical data since such an association has only been reported in a single case (3). Accordingly, it is usually not advised to carry out thorough investigations in the common, solitary HN occurring in teenagers or young adults apart from a close examination of pigmented cutaneous lesions including the naevus targeted by the achromic reaction, nor is it recommended to systematically remove the HN.

The occurrence of multiple HN is very seldom reported in the literature (9, 10) and they do not seem to be at particularly high risk of association with malignant melanoma. However, the strikingly quick and simultaneous occurrence of multiple HN in our

patient prompted us to search for a remote lesion triggering a systemic immune response targeting pigmented cells, mainly a malignant melanoma. As no cutaneous lesions seemed particularly atypical, a visceral lesion was searched for by appropriate means leading to the diagnosis of an asymptomatic benign ileal carcinoid tumour. A random association cannot be ruled out, but a mere coincidence between these two rare conditions seems unlikely. However, the precise relationship between the two diseases remains elusive, although it might be hypothesized that a cellular immune response elicited by the presence of the carcinoid tumour could be responsible for the rapid occurrence of multiple HN through a cross-reaction between tumoral cells and melanocytes. This hypothesis is supported by the fact that these two cell types share a common embryonic origin, the neural crest, and might share some surface antigens – although these common antigens are currently unknown. Furthermore, the lack of occurrence of new HN after removal of the ileal tumour is an additional clue favouring the hypothesis of a relationship between these two conditions.

REFERENCES

1. Happel R, Schotola I, Macher E. Spontaneous regression and leukoderma in malignant melanoma. *Hautarzt* 1975; 26: 120–123.
2. Fishman HC. Malignant melanoma arising with two halo nevi. *Arch Dermatol* 1976; 112: 407–408.
3. Nudenberg B. Halo nevi and vitiligo-like phenomena in a case of melanoma. *Med Cutan Ibero Lat Am* 1979; 7: 45–49.
4. Albert DM, Todes-Taylor N, Wagoner M, Nordlund JJ, Lerner AB. Vitiligo or halo nevi occurring in two patients with choroidal melanoma. *Arch Dermatol* 1982; 118: 34–36.
5. Barriere H, Litoux P, Le Lay M, Bureau B, Stalder JF, Dreno B. Cutaneous achromia and malignant melanoma. *Ann Dermatol Venereol* 1984; 111: 991–996.
6. Bouffard D, Barnhill RL, Mihm MC, Sober AJ. Very late metastasis (27 years) of cutaneous malignant melanoma arising in a halo giant congenital nevus. *Dermatology* 1994; 189: 162–166.
7. Mandalia MR, Skillman JM, Cook MG, Powell BW. Halo naevus or malignant melanoma. A case report. *Br J Plast Surg* 2002; 55: 512–513.
8. Zeff RA, Freitag A, Grin CM, Grant-Kels JM. The immune response in halo nevi. *J Am Acad Dermatol* 1997; 37: 620–624.
9. Itin PH, Lautenschlager S. Acquired leukoderma in congenital pigmented nevus associated with vitiligo-like depigmentation. *Pediatr Dermatol* 2000; 19: 73–75.
10. Gordeladze AS, Pavlova TA. Multiple halo nevi: their differential diagnosis from malignant melanoma. *Arkh Patol* 1990; 52: 66–69.

Anaphylaxis after Dental Treatment with a Formaldehyde-containing Tooth-filling Material

Yukiko Nabeshima, Toshihiko Tanaka and Michihiro Hide

Department of Dermatology, Programs for Biomedical Research, Division of Molecular Medical Science, Graduate School of Biomedical Sciences, Hiroshima University, 1-2-3, Kasumi, Minami-ku, Hiroshima, 734-8551, Japan.

E-mail: yukikano@hiroshima-u.ac.jp

Accepted May, 3 2004.

Sir,

Formaldehyde is widely used in cosmetics, building materials and furniture, and is a well-known cause of contact dermatitis, occupational asthma, and sick-building syndrome (1, 2). Recently, a few cases of anaphylactic reactions to formaldehyde in patients with dental treatment have been reported (3–5). However, the mechanism of such reactions has not been precisely elucidated. We report here a patient who showed anaphylactic reactions after dental treatment with a formaldehyde-containing tooth-filling material, and demonstrate the release of histamine from basophils of this patient with formaldehyde-human serum albumin conjugates (formaldehyde-HSA).

CASE REPORT

A 31-year-old man who was engaged in the production of automobiles, who did not have a personal or family history of allergies, was treated with a formaldehyde-containing tooth filling (Formalin guaiacol FG neoTM), consisting of three liquids – formalin (40%), guaiacol (40%) and ethanol (20%). After 1 week, he was treated again in this way. Approximately 30 min later, he developed a generalized urticaria and experienced respiratory difficulty. He received oxygen and intravenous transfusion, and recovered after 3 h. The skin eruption gradually diminished and finally disappeared 2 days later. The intracutaneous test with 0.5×10^5 and 1×10^6 dilutions of 40% formaldehyde solution in saline was positive (wheal diameter 10 mm and 6 mm, respectively), whereas that with 1×10^7 , 1×10^8 and saline was negative (wheal diameter <2 mm). None of five healthy volunteers showed any reaction in these tests. The specific IgE value against formaldehyde was 17.0 UA/ml, class 3 (CAP-RAST Pharmacia and Upjohn), whereas total IgE was 239.0 IU/ml (normal range <321.4 IU/ml).

For laboratory analysis, a conjugate of formaldehyde with HSA was prepared as described by Karol et al. (6). Briefly, 4 ml of formaldehyde (12 mg/ml) was mixed with 1 ml of 0.01 M phosphate buffer (0.01 M $\text{NaH}_2\text{PO}_4 \times 2\text{H}_2\text{O}$, 0.01 M $\text{Na}_2\text{HPO}_4 \times 12\text{H}_2\text{O}$, pH 7.4) with 5% HSA and incubated for 30 min at 37°C. The solution was dialysed against 0.01 M phosphate buffer for 3 days at 4°C and used as such. Basophil-enriched leukocyte suspensions were prepared from 40 ml of venous blood from the patient as described by Hide et al. (7). They were aliquoted (11) in tubes containing the challenge stimuli: formaldehyde-HSA (≤ 6.95 mg/ml),

5% human serum albumin (6.95 mg/ml), goat anti-human IgE as positive control (0.67 $\mu\text{g/ml}$) (Seikagaku Co., Tokyo, Japan), or buffer alone. After incubation at 37°C for 40 min, the amount of histamine released into supernatants was measured by an automated fluorometric assay, as described previously (7).

Only the basophils of the patient released a large amount of histamine (44.0%) in response to formaldehyde-HSA (3.48 mg/ml). HSA induced no apparent release of histamine from either the patient's or healthy control's basophils (Fig. 1). Serial dilutions of formaldehyde-HSA formed a bell-shaped dose-response curve in the histamine release experiment with basophils of the patients (Fig. 2).

DISCUSSION

In the present case, we have demonstrated the presence of specific serum IgE and positive skin reaction to formaldehyde, suggesting that formaldehyde contained in tooth-filling material induced anaphylactic reaction after the dental treatment. The *in vitro* experiment revealed that formaldehyde-HSA induces the release of histamine specifically from the patient's basophils, in accordance with clinical observation.

Formaldehyde is commonly used for the treatment of dental caries. It is slowly released from root canal sealers, and permeates through cementum and blood after such treatments. Consequently, anaphylactic reaction to formaldehyde may not develop immediately

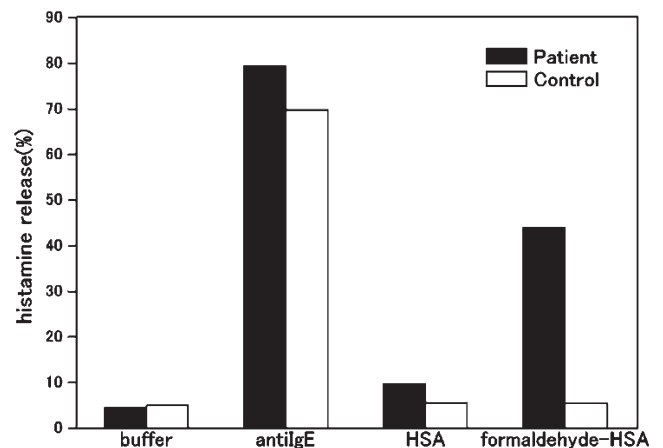


Fig. 1. Histamine release from basophils of the patient and a healthy volunteer (Control) in response to anti-IgE (0.34 $\mu\text{g/ml}$), human serum albumin (HSA, 3.48 mg/ml) and formaldehyde-HSA (3.48 mg/ml).

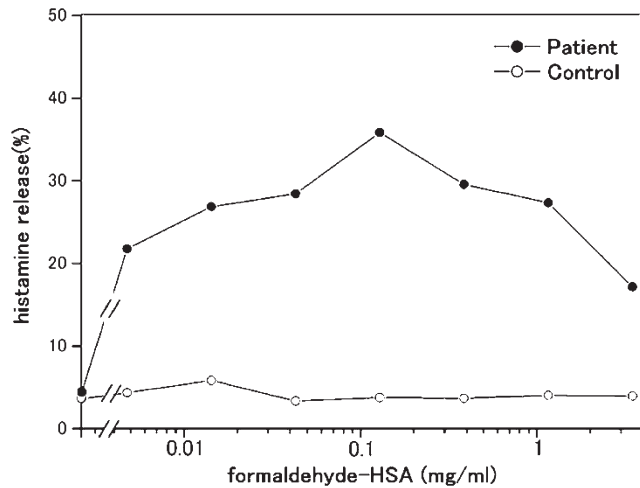


Fig. 2. Histamine release from basophils of the patient and a healthy volunteer (Control) with serial dilutions of formaldehyde-human serum albumin.

after the application of the material, rather later (3–5). As formaldehyde is included in many materials, such as building materials, furniture and paints, sensitization to formaldehyde can also take place during occupational exposure, and even during daily life by exposure to very low amounts of indoor formaldehyde. In the case reported here, sensitization may have occurred during dental treatment 1 week before, or through the patient's occupation – painting cars.

Recently, systemic reactions after dental treatment with formaldehyde-containing materials have been increasingly reported (3–5). The presence of specific serum IgE against formaldehyde has been taken as evidence for an anaphylactoid pathogenesis. However, such IgE was also detected in some patients with occupational asthma or sick-building syndrome who

have not developed anaphylactic reactions (1, 2). This suggests that the presence of specific serum IgE does not necessarily lead to anaphylactic reactions to formaldehyde. On the other hand, skin tests to formaldehyde are not standardized and positive skin reactions were observed only in few patients (3–5). In addition, skin tests with higher concentration of formaldehyde solution may provoke severe systemic reactions. We demonstrate here that a histamine release test with formaldehyde-HSA *in vitro* is a reliable and safe method for the diagnosis of anaphylaxis induced by formaldehyde.

REFERENCES

1. Wantke F, Demmer CM, Tappler P, Gotz M, Jarisch R. Exposure to gaseous formaldehyde induces IgE-mediated sensitization to formaldehyde in school-children. *Clin Exp Allergy* 1996; 26: 276–280.
2. Cheol-Woo K, Jae-Seok S, Yeon-Soon A, Seung-Hyun P, Jung-Won P, Jae-Hoon N, et al. Occupational asthma due to formaldehyde. *Yonsei Med J* 2001; 42: 440–445.
3. Braun JJ, Zana H, Purohit A, Valfrey J, Scherer P, Haikel Y, et al. Anaphylactic reactions to formaldehyde in root canal sealant after endodontic treatment: four cases of anaphylactic shock and three of generalized urticaria. *Allergy* 2003; 58: 1210–1215.
4. Modre B, Kranke B. Anaphylactic reaction to formaldehyde. *Allergy* 2001; 56: 263–264.
5. Wantke F, Hemmer W, Haglmuller T, Gotz M, Jarisch R. Anaphylaxis after dental treatment with a formaldehyde-containing tooth-filling material. *Allergy* 1995; 50: 274–276.
6. Karol MH, Kramarik JA, Ferguson J. Methods to assess RAST results in patients exposed to chemical allergens. *Allergy* 1995; 50: 48–54.
7. Hide M, Francis DM, Grattan CEH, Hakimi J, Kochan JP, Greaves MW. Autoantibodies against the high-affinity IgE receptor as a cause of histamine release in chronic urticaria. *N Engl J Med* 1993; 328: 1599–1604.

Body Dysmorphic Disorder of Twins with Facial Illness after Successful Isotretinoin Therapy

Ritva Erkolahti¹, Tuula Ilonen², Marita Eerola², Simo Saarijärvi² and Heli Majamaa³

¹Child Psychiatry Clinic, Satakunta Hospital District, Sairaalan tie 3, FIN-28500 Pori, ²University of Turku, Adolescent Psychiatric Clinic, Turku ³Department of Dermatology, Satakunta Central Hospital, Pori, Finland. E-mail: ritva.erkolahti@tyks.fi
Accepted May 27, 2004.

Sir,

Long-standing dermatological conditions are commonly associated with psychiatric problems. The onset and the course of a dermatological disorder may be significantly influenced by stress, emotional disturbances or psychiatric disorders. According to Folks & Warnock (1), in some cases, skin conditions are self-induced or reflect signs or symptoms of an underlying psychiatric disorder, including psychosis or obsessive-compulsive disorder.

Isotretinoin is indicated for the treatment of severe acne. It has been shown (2–4) that successful acne therapy reduces anxiety and depression significantly in patients with acne. In recent years, isotretinoin therapy and adverse psychiatric effects have received considerable attention. Despite the fact that there are reports of cases where isotretinoin has led to depression, recent findings (5, 6) indicate that there is no evidence that the use of isotretinoin is associated with an increased risk for depression, suicide or other psychiatric disorders.

In this case, we assessed male twins with similar kind of persistent facial dermatological problems. They had been treated with isotretinoin for acne successfully, but their skin-related problems persisted.

CASE REPORTS

Two dizygotic male twins aged 21 were referred to the Adolescent Psychiatric Clinic at the university hospital by their dermatologist for evaluation and advice on psychiatric management. The isotretinoin treatment for acne had ended 2 years prior to the consultation. For Case 1, the medication began at the age of 17 years. The dosage was 20 mg daily for the first 3 months, then the medication was discontinued for 3 months, and after that it was resumed using 40 mg daily for 8 months. Case 2 received isotretinoin medication at the age of 18 for 5 months at a dosage of 60 mg/day. In both patients, acne was cured, leaving some telangiectasia and mild erythema of the malar facial skin, with a mild tint of pigmentation. Objectively perceived, the skin condition was well within the range of normal looks, but both patients expressed severe concerns, and demanded additional treatment options. Both patients received pulsed light treatment (PhotoDerm) of the telangiectasias, with some objectively perceived effect, nevertheless satisfying neither of the patients. On their own, the patients sought and received many kinds of homeopathic treatments.

The twins were concerned about their looks and the

responses of other people. They believed that people considered their facial skin deviant. Cleaning and peeling the facial skin changed to obsessive and compulsive kind of behaviour. Gradually they isolated themselves from most of their social relations outside home.

The twins' parents belong to the upper middle class. Both parents are Caucasian. The twins were the only children in the family. The twin brothers were born in the 36th week of pregnancy by a Caesarean section because the heartbeat of case no. 1 was irregular, suggesting fetal distress due to their mother's toxemia. Their growth and development was normal. During compulsory school they were outstanding athletes and their school reports were excellent. Both young men lived with their parents at the time of the referral. The mother was somewhat depressed, and the father refused to come to the consultation.

Case 1 weighed 1980 g at birth. The twins had separate placentas and there was an infarction in the placenta of this twin. He entered puberty at the age of 10, almost a year earlier than his twin brother. In his teens, he was concerned about his acne and the shape of his nose. He was unable to finish high school.

Psychiatric interview: He mentioned feelings of anxiety and depression whenever he started to think about his skin problems, which he blamed for his withdrawal from society. He did not expect any psychiatric treatment to alleviate his suffering. He was in good physical health. The diagnostic interview gave the DSM-IV diagnosis of body dysmorphic disorder (DSM-IV 300.7) with an additional diagnosis of delusional disorder, somatic type (DSM-IV 297.1) and depressive disorder NOS (DSM-IV 311).

Psychological assessment: The WAIS-R performance yielded a full-scale IQ of 115 for this boy. Psychological functions were assessed via the Rorschach Comprehensive System by Exner (7). The Depression Index (DEPI) had a value of 7/7. This provided a strong basis from which to hypothesize that a major depression was present. The relatively high number of perceptually inaccurate responses ($X\% = 0.25$) signified that many of his translations involved considerable distortion of the input. This suggests the likelihood of some significant reality testing problems.

Treatment: The patient was offered antipsychotic and/or antidepressive medication, which he refused. He was also recommended intensive psychotherapy. He

decided to start seeing his psychotherapist twice a week. After 1 year of psycho-dynamically oriented psychotherapy, he has moved from home to live on his own and restarted sport activities, which has helped him to reintegrate socially. He had some complaints about his facial skin still but they did not disturb his daily life.

Case 2 weighed 2350 g at birth. He had been very happy with his own appearance until the age of 18, when he suddenly started claiming that the colour of his face was unpleasantly dark red. He started to skip classes, but was able to graduate from high school 2 years later than his age group.

Psychiatric interview: The only reason for attending psychiatric consultation for this patient was to persuade his dermatologist to treat him again. There were no signs of depression. His physical health was good. The diagnostic interview gave the DSM-IV diagnosis of body dysmorphic disorder (DSM-IV 300.7) with an additional diagnosis of delusional disorder, somatic type (DSM-IV 297.1).

Psychological assessment: The WAIS-R performance yielded a full-scale IQ of 110 for this twin. The DEPI value (2/7) was not significant. Instead, his elevated reflection responses ($Fr+rF>0$) indicated marked tendencies to overvalue personal worth. He characteristically externalized responsibility for his failures and blamed any difficulties he encountered on events beyond his control. The relatively high number of perceptually inaccurate responses ($X-\% = 0.29$) signified that many of his translations involved considerable distortion of the input. This suggests the likelihood of some significant reality testing problems.

Psychiatric treatment was recommended but he refused and was lost for follow-up. The only knowledge we have about him is that he had started his service in the Defense Forces.

DISCUSSION

Long-standing dermatological conditions are commonly associated with psychiatric problems, and the patients may thus need psychiatric consultation. Understanding the psychosocial context of skin diseases is critical to the optimal management of psychodermatologic disorders, as stated by Koo & Lebwohl (8). Like some other recent studies (5, 6), isotretinoin was shown not to be the cause of the depression or other psychiatric symptoms in our study.

The main diagnosis for both twins was a body dysmorphic disorder with delusional intensity. Case 1 was also diagnosed as having atypical depression.

Case 1 developed his delusional symptoms a year before Case 2. He had also had more perinatal problems, which may increase the risk for psychotic disorder as described by Rosa et al. (9).

Case 1 refused all psychopharmacological treatment but accepted psychotherapy after persuasion. Case 2 did not accept any kind of psychiatric treatment. However, the psychiatric consultation and evaluation proved to be a therapeutic intervention, giving the patients alternative approaches to deal with their problems and contributing to their separation-individuation process.

The management of psychodermatologic disorders requires a dual approach, addressing both dermatologic and psychiatric aspects. Patients with psychodermatologic disorders frequently resist referral to mental health professionals but acceptance of psychiatric treatment may be enhanced through support from the dermatologist (8). Our findings highlight the importance of recognizing psychiatric comorbidity among dermatology patients.

ACKNOWLEDGEMENT

The authors wish to thank Christer Jansen, Professor of Dermatology, University of Turku, Finland, for his guidance during this work.

REFERENCES

1. Folks DG, Warnock JK. Psychocutaneous disorders. *Curr Psychiatry Rep* 2001; 3: 219–225.
2. Rubinow DR, Peck GL, Squillace KM, Gantt GG. Reduced anxiety and depression in cystic acne patients after successful treatment with oral isotretinoin. *J Am Acad Dermatol* 1987; 17: 25–32.
3. Gupta MA, Gupta AK, Schork NJ, Ellis CN, Voorhees JJ. Psychiatric aspects of the treatment of mild to moderate facial acne. *Int J Dermatol* 1990; 29: 719–721.
4. Newton JN, Mallon E, Klassen A, Ryan TJ, Finlay AY. The effectiveness of acne treatment: an assessment by patients of the outcome of therapy. *Br J Dermatol* 1997; 137: 563–567.
5. Jick SS, Kremers HM, Vasilakis-Scaramozza C. Isotretinoin use and risk of depression, psychotic symptoms, suicide and attempted suicide. *Arch Dermatol* 2000; 136: 1231–1236.
6. Jacobs DG, Deutsch NL, Brewer M. Suicide, depression, and isotretinoin: is there a causal link? *J Am Acad Dermatol* 2001; 45: 168–175.
7. Exner JE Jr. *The Rorschach: a comprehensive system*, Vol 1, 3rd edn. New York: John Wiley, 1993.
8. Koo J, Lebwohl A. Psychodermatology: the mind and skin connection. *Am Fam Physician* 2001; 64: 1873–1878.
9. Rosa A, Fananas L, Bracha HS, Torrey EF, van Oss J. Congenital dermatoglyphic malformations and psychosis: a twin study. *Am J Psychiatry* 2000; 157: 1511–1513.