

A Unique Case of Localized Pemphigus Vulgaris

Sir,

We describe a case of localized pemphigus vulgaris (PV) that is unique in clinical and histological appearance and clinical course.

CASE REPORT

A 47-year-old Japanese male noticed an erosive lesion on his left lower lip margin in February 1995. Treatment with a corticosteroid ointment gave no improvement. In March 1995, he also noticed a keratotic lesion on his left shoulder; the keratotic mass sometimes fell off, resulting in an erosive lesion, which then became keratotic again. Prior to the lesions, no bulla had been formed. When examined in our outpatient clinic after 5 months, the lesion on his shoulder had a keratotic mass measuring 6×4 mm in diameter with surrounding erythema (Fig. 1). In the last few years, he had not taken any medicine. During disinfection, the keratotic mass fell off, leaving an erosion. Histology of the skin lesion showed an acanthotic and hyperkeratotic epidermis in the peripheral part of the lesion. Clefts and acantholysis were seen in the suprabasal and lower spinous cell layers (Fig. 2). No dyskeratotic cells were observed. In the upper dermis of the central part of the lesion, a massive cell infiltrate composed mostly of plasma cells with some lymphocytes was seen.

Immunohistochemically, the skin specimen revealed IgG deposits in the intercellular space (ICS) of the entire epidermis and, similarly, C₃ in the lower epidermis. Indirect immunofluorescence studies gave an evidence of circulating anti-ICS antibodies of IgG class (×16). Immunoblot analysis (1) indicated that the serum reacted with the 130 kDa protein, PV antigen (Fig. 3).

The skin lesion healed after surgical removal and no recurrence was observed for 24 months. The erosive lesion of the lip margin lasted for 6 months, despite application of corticosteroid ointment. After 10 days' application of gentamycin ointment, it was epithelized. The erosion reappeared after 5 months. The lip lesion was excised 3 months later and histologically and immunohistochemically revealed almost the same findings, except hyperkeratosis, as in the skin. Since then, it has not recurred at least for 18 months.

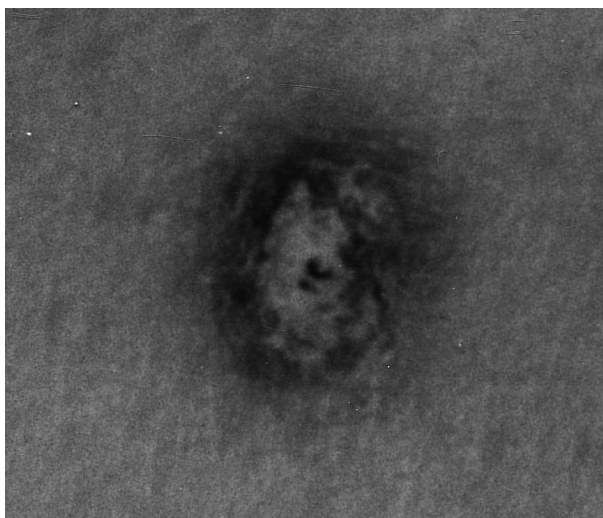


Fig. 1. Clinical appearance of the shoulder skin lesion (4×6 mm) with a keratotic mass and surrounding erythema.

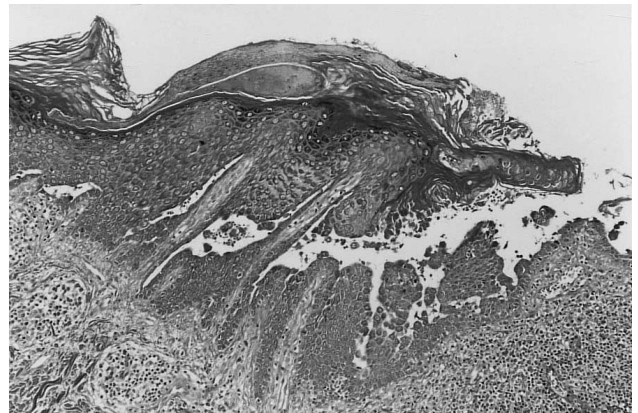

Fig. 2. Histological findings of the skin lesion (H & E). The epidermis shows acanthosis with clefts, acantholysis and hyperkeratosis (×70).

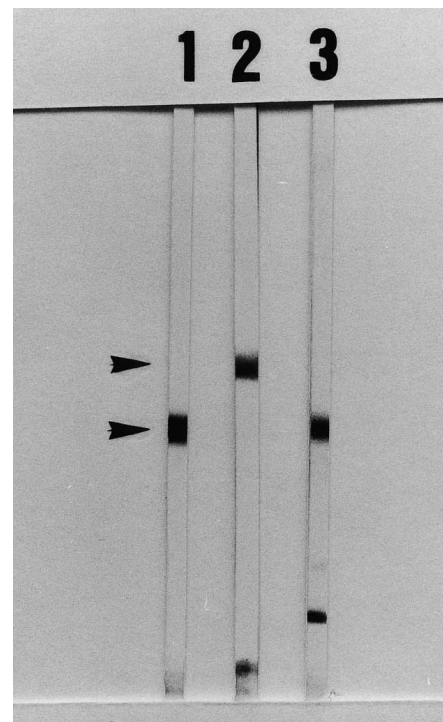


Fig. 3. Immunoblotting of epidermal extract. Pemphigus vulgaris (PV) serum (lane 1, control) reacts with the 130 kDa PV antigen. Pemphigus foliaceus (PF) serum (lane 2, control) reacts with the 160 kDa PF antigen. Serum of the present case (lane 3) reacts with the 130 kDa PV antigen.

DISCUSSION

Clinically, superficial pemphigus may resemble other dermatoses, such as lupus erythematosus or seborrheic dermatitis. Recently, a few cases of generalized phase of pemphigus mimicking seborrheic keratoses (SK) in clinical appearance have been reported. The SK-like lesions either developed during immunosuppressive therapy (2–4), or appeared with-

out preceding bullous lesion and healed after oral corticosteroids (5, 6).

In our patient the titre of circulating anti-ICS antibodies was low, which might indicate a prolonged initial phase of PV before generalized development of bullae. The massive plasma cell infiltrate seen in the lesional upper dermis may be a factor for the localization of the lesions. Another possibility is that an unknown mechanism prevents the generalization of PV, resulting in the unique features described above. Since acanthosis was seen histologically, the diagnosis of pemphigus vegetans is also possible.

REFERENCES

1. Hashimoto T, Ogawa MM, Konohana A, Nishikawa T. Detection of pemphigus vulgaris and pemphigus foliaceus antigens by immunoblot analysis using different antigen sources. *J Invest Dermatol* 1990; 94: 327–331.
2. Jacyk WK, Simson IW. Pemphigus erythematosus resembling multiple seborrheic keratoses. *Arch Dermatol* 1990; 126: 543–544.
3. Faber WR, Neumann HAM, Flinterman J. Persistent vegetating and keratotic lesions in patients with pemphigus vulgaris during immunosuppressive therapy. *Br J Dermatol* 1983; 109: 459–463.
4. Yesudian PD, Krishnan SGS, Jayaraman M, Janaki VR, Yesudian P. Postpemphigus acanthomata: a sign of clinical activity? *Int J Dermatol* 1997; 36: 194–196.
5. Bruckner N, Kats RA, Hood AF. Pemphigus foliaceus resembling eruptive seborrheic keratoses. *Arch Dermatol* 1980; 116: 815–816.
6. Kahana M, Trau H, Schewach-Millet M, Sofer E. Pemphigus foliaceus presenting as multiple giant seborrheic keratoses. *J Am Acad Dermatol* 1984; 11: 299–300.

Accepted June 2, 1999.

Chozaburo Okuda¹, Hiroshi Fujiwara², Masaaki Ito² and Takashi Hashimoto³

¹Section of Dermatology, Saiseikai Sanjo Hospital, Sanjo 955-8511, Japan, ²Niigata University School of Medicine, Niigata and ³Kurume University School of Medicine, Fukuoka, Japan.

Interferon Alpha-2a Monotherapy for Necrobiotic Xanthogranuloma

Sir,

Necrobiotic xanthogranuloma (NX) is a rare histiocytic disorder, which was first described as a distinct entity by Kossard & Winkelmann in 1980 (1). NX is characterized clinically by indurated xanthomatous or violaceous nodules and plaques that occur mostly on the trunk and the periorbital area (2). Since, in some cases, involvement of internal organs has been clearly documented (3), NX should be regarded as a systemic disease. Under light microscopy the cutaneous lesions reveal palisading granulomas in the dermis and subcutis, with numerous giant cells, of foreign body and Touton types, associated with areas of necrobiosis or hyalinized connective tissue (4). NX is commonly associated with myeloproliferative disorders, particularly multiple myeloma and lymphoma, paraproteinaemia, increased sedimentation rate and serum immunoglobulin levels, anaemia and leukopenia (5). Various therapeutic approaches, including cytotoxic agents, radiotherapy, surgical excision and plasmapheresis, have been employed in the management of NX with varying success (4).

In view of the recently reported favourable therapeutic results of the combined application of prednisone and interferon alpha in NX (6), we investigated the efficacy and safety of subcutaneous recombinant interferon α -2a monotherapy in a case of NX.

CASE REPORT

An 82-year-old Caucasian man was referred to the Department of Dermatology, University of Patras, Greece, for evaluation and treatment of cutaneous lesions that had developed over a 3-year period. On examination, multiple firm, painless, yellowish-red nodules and plaques, with an atrophic and teleangiectatic centre, were seen on his upper chest and back (Fig. 1A). There was no evidence of lymphadenopathy or hepatosplenomegaly and the remainder of the

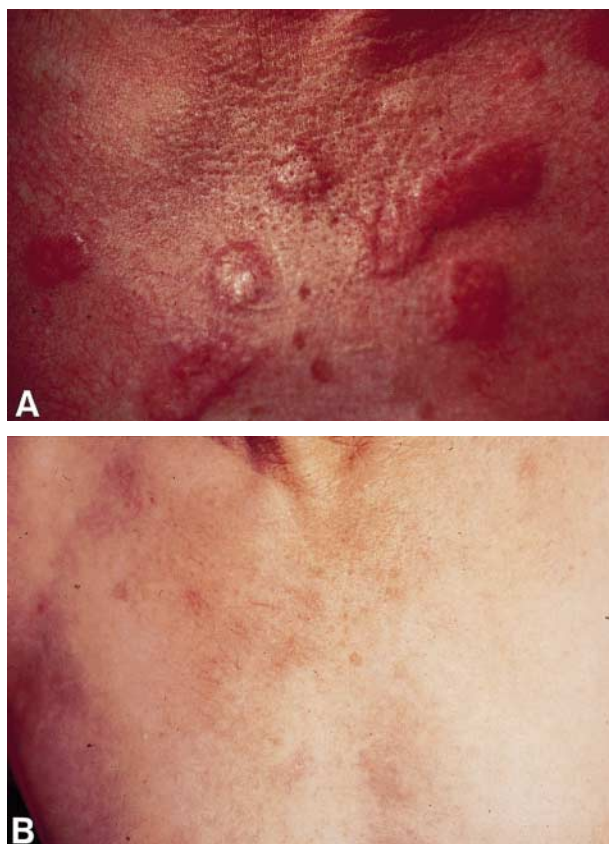


Fig. 1. Clinical presentation of yellowish-red nodules and plaques affecting the chest (A) before and (B) 4 months after start of subcutaneous recombinant interferon alpha-2a monotherapy.