

Ichthyosis Vulgaris and X-linked Ichthyosis: Simultaneous Segregation in the Same Family

Sir,

Autosomal dominant ichthyosis vulgaris (IV) and X-linked ichthyosis (XLI) share many clinical features. XLI has a reported frequency of 1:2000–6000 males, while IV has a frequency of 1:250 persons (1, 2). Several reports have stated clinical differences between the 2 types of ichthyosis in order to establish a differential diagnosis (3).

The 2 types of ichthyosis are due to different genetic defects. The most frequent molecular defect in XLI is a complete deletion of the steroid sulphatase (STS) gene (4–7), which is located on Xp22.3 (8). The STS gene codes for the STS enzyme (EC 3.1.6.2), which hydrolyses 3-beta-hydroxy-steroid sulphates (9). Determination of STS enzymatic activity confirms XLI diagnosis and can be used to classify both types of ichthyosis (10). Autosomal dominant IV is the consequence of a keratohyaline alteration affecting the matrix protein of the stratum corneum (11). However, the gene defect in IV has not been identified.

We describe here a Mexican family segregating both types of ichthyosis.

PATIENTS AND METHODS

The proband was a 9-year-old boy who showed a moderate degree of skin affection. The sample included a family in which 10 male members were affected by ichthyosis. Seven possible XLI carriers were also included. They were all informed about the details of the study and they agreed to participate. An STS assay was carried out in all subjects as described previously (12, 13). DNA extraction of peripheral blood and PCR amplification of the 5' and 3' ends of the STS gene were performed by conventional methods in all patients (14–15). Normal controls were included in each assay.

RESULTS AND DISCUSSION

Fig. 1 shows the family pedigree. The proband was classified as an XLI patient through STS assay (0.00 pmol/mg protein/h) and DNA analysis (no amplification of both extremes of STS gene). It was stated that his grandfather presented a form of ichthyosis and we concluded by pedigree analysis that it probably corresponded to XLI. Thus, the maternal aunts of the proband were considered as obligate XLI carriers, in fact the proband's mother (II-5), 2 aunts (II-4, II-8) and 1 sister (III-4) had an STS activity compatible

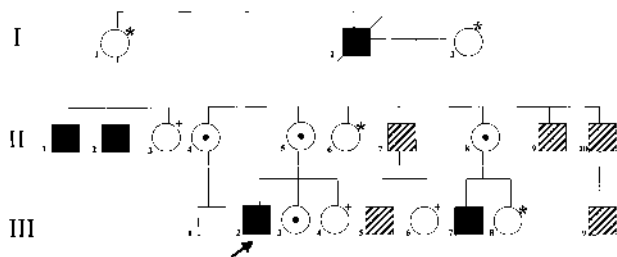


Fig. 1. Genealogy of the family simultaneously segregating X-linked ichthyosis (XLI) and ichthyosis vulgaris (IV). ■ XLI (no STS activity); hatched shading: IV (normal STS activity); circle with central black spot: XLI-carrier through STS activity; *STS activity not determined; +normal STS activity. Patient II-1 had unilateral cryptorchidism and II-2 had bilateral cryptorchidism.

with an XLI-carrier state (0.24–0.30 pmol/mg protein/h). Patients II-1 and II-2 had ichthyosis and STS activity compatible with XLI diagnosis (0.00 pmol/mg protein/h). In these cases, DNA analysis of the 5' and 3' ends of STS gene corroborated the diagnosis of XLI. These patients also had cryptorchidism, an associated finding of XLI, which was corrected surgically. Patients II-7, II-9, II-10, III-5 and III-9 had ichthyosis and normal STS activity (0.87 ± 0.15 pmol/mg protein/h) with normal amplification of 5' and 3' ends of STS gene. They were classified as IV patients. Individuals III-4 and III-6 were analysed and they presented a normal STS activity.

Only 1 family has previously been described with both of these varieties of ichthyosis (16). The cases were analysed clinically, histologically and by electron microscopy, but the STS assay was not available and XLI diagnosis was not confirmed.

Although IV and XLI are being transmitted in the family described here, it is not possible to establish whether the segregation occurs through the same progenitor. Unfortunately, the IV gene defect has not yet been identified and we cannot discard this possibility. A more detailed study is necessary to test this hypothesis.

REFERENCES

1. Wells RS, Kerr CB. Clinical features of autosomal dominant and sex-linked ichthyosis in an English population. *BMJ* 1966; 1: 947–950.
2. Lykkesfeldt G, Nielsen MD, Lykkesfeldt A. Placental steroid sulfatase deficiency: biochemical diagnosis and clinical review. *Obstet Gynecol* 1984; 64: 49–54.
3. Shayder T, Ott F. All about ichthyosis. *Pediatr Clin North Am* 1991; 38: 835–857.
4. Bonifas JM, Morley BJ, Oakey RE, Waikon Y, Epstein EH. Cloning of cDNA for steroid sulfatase: frequent occurrence of gene deletions in patients with recessive X-chromosome-linked ichthyosis. *Proc Natl Acad Sci (USA)* 1987; 84: 9248–9251.
5. Shapiro LJ, Yen P, Pomerantz D, Martin E, Rolewic L, Mohandas T. Molecular studies of deletions at the human steroid sulfatase locus. *Proc Natl Acad Sci USA* 1989; 86: 8477–8481.
6. Sugawara T, Honkey K, Fujimoto S, Makita A. Steroid sulfatase deficiency in Japanese patients: characterization of X-linked ichthyosis by using polymerase chain reaction. *Jpn J Hum Genet* 1993; 38: 421–428.
7. Cuevas-Covarrubias SA, Diaz-Zagoya JC, Maya-Nuñez G, Orozco E, Kofman Alfaro S. X-linked ichthyosis in Mexico: a very high frequency of deletions in the steroid sulfatase encoding gene. *Am J Med Gen* 1997; 72: 415–416.
8. Muller C, Walhstrom J, Rogers H. Further evidence for the assignment of steroid sulfatase X-linked ichthyosis locus to the telomere of Xp. *Hum Genet* 1981; 58: 446.
9. Dibbelt L, Kuss E. Human placental steryl-sulfatase: Interaction of the isolated enzyme with substrates, products, transition-state analogues, amino-acid modifiers and anion transport inhibitors. *Biol Chem Hoppe-Seyler* 1991; 372: 73.
10. Shapiro LJ, Weiss R. X-linked ichthyosis due to steroid sulphatase deficiency. *Lancet* 1978; 14: 70–72.
11. Sybert VP, Dale BA, Holbrook KA. Ichthyosis vulgaris: identification of a defect in synthesis of filaggrin correlated with an absence of keratohyaline granules. *J Invest Dermatol* 1984; 84: 191–194.

12. Cuevas S, Juarez M, Miranda R, Díaz J. Comparative analysis of human steroid sulfatase activity in pre and postpubertal males and females. *Biochem Mol Biol Inter* 1993; 30: 691–695.
13. Epstein EH, Leventhal ME. Steroid sulfatase of human leucocytes and epidermis and the diagnosis of recessive X-linked ichthyosis. *J Clin Invest* 1981; 67: 1257–1262.
14. Lench N, Stainer P, Williamson R. Simple non-invasive method to obtain DNA for gene analysis. *Lancet* 1988; 18: 1356–1358.
15. Ballabio A, Ranier JE, Chamberlain JS, Zollo M, Caskey CT. Screening for steroid sulfatase (STS) gene deletions by multiplex DNA amplification. *Hum Genet* 1990; 84: 571–572.
16. Mevorah B, Frenk E, Pescia G. Ichthyosis vulgaris showing

features of the autosomal dominant and the X-linked recessive variants in the same family. *Clin Genet* 1978; 13: 462–470.

Accepted May 14, 1999.

S. A. Cuevas-Covarrubias¹, M. Valdes-Flores² and M. R. Rivera-Vega¹ J. C. Diaz-Zagoya³ and S. H. Kofman-Alfaro¹
¹Servicio de Genética, Hospital General de México and ³Departamento de Bioquímica, Facultad de Medicina, UNAM, Dr Balmis 148 Col. Doctores, CP 06726, México DF. E-mail: sergio@servidor.unam.mx and ²Servicio de Genética, Instituto Nacional de Ortopedia, México DF, México.

Post-herpes Zoster Scar Sarcoidosis

Sir,

I read with interest the report by Corazza et al. describing a case of post-herpes zoster scar sarcoidosis (1).

Although histological findings followed patterns of cutaneous sarcoidosis, 2 questions remain concerning the diagnosis of scar sarcoidosis.

First, the patient had negative investigations for systemic sarcoidosis, whereas the previous report of sarcoidal granuloma in herpes zoster scars included bilateral hilar lymphadenopathy as a prominent radiological feature of sarcoidosis (2).

Secondly, sarcoidosis may account for granuloma formation, but "sarcoidal" granuloma formation in herpes zoster scars has also been reported in patients with chronic lymphocytic leukaemia (3).

Granulomatous tissue reactions encountered in the healing phase of lesions caused by herpes zoster virus depend on the patient's immune status. Such a hypersensitivity reaction may arise by the same mechanism in other diseases with immunological abnormalities.

I believe histopathological changes in scars, as mentioned

by Corazza et al., should be reported as sarcoid-like granuloma and use of the term (scar) sarcoidosis should be restricted to cases fulfilling several diagnostic patterns of sarcoidosis.

REFERENCES

1. Corazza M, Bacilieri S, Strumia R. Post-herpes zoster scar sarcoidosis. *Acta Derm Venereol* 1999; 79: 95.
2. Bisaccia E, Carborough DA, Carr RD. Cutaneous sarcoid granuloma formation in herpes zoster scars. *Arch Dermatol* 1983; 119: 788–789.
3. Wright AL, Cotton DW, Winfield DA, Messenger AG. Granuloma formation in herpes zoster scars. *Dermatologica* 1989; 179: 45–46.

Accepted June 9, 1999.

Vincent Barraza, MD
 14 rue du Dobropol, F-75017 Paris, France.
 E-mail: vincentbarraza@yahoo.fr

Response to the Letter by Barraza

Sir,

We are grateful to Barraza for having emphasized various aspects connected with the diagnosis of post-herpes zoster scar sarcoidosis. Scar sarcoidosis is often associated with systemic involvement, but it may occur in the absence of systemic symptoms or even precede them.

Even though previously reported cases of sarcoidal granulomas in herpes zoster scars have been observed in patients affected by chronic lymphocytic leukaemia (1, ref. 2 above), immunological abnormalities or lymphoproliferative disorders were not found in our patient. In this particular case, therefore, it is difficult for us to consider the granulomatous tissue reaction on the herpes zoster scar as

depending on immunological abnormalities. Further reports will probably resolve this question.

REFERENCE

1. Fischer G, Jaworski R. Granuloma formation in herpes zoster scars. *J Am Acad Dermatol* 1987; 16: 1261–1263.

Monica Corazza, Sandra Bacilieri and Renata Strumia
 Department of Dermatology, University degli Studi di Ferrara, Via Savonarola 9, I-44100 Ferrara, Italy.