

Excision Repair Defect in Rothmund Thomson Syndrome

F. VASSEUR¹, E. DELAPORTE², M. T. ZABOT³, M. N. STURQUE⁵, D. BARRUT⁴, J. B. SAVARY⁵, L. THOMAS⁶ and P. THOMAS²

¹Department of Genetics of Multifactorial Diseases, CHRU, Lille, ²Department of Dermatology, Claude Huriez Hospital, Lille, ³Department of Biochemistry, Debrousse Hospital, Lyon, ⁴Department of Dermatology, Antiquaille Hospital, Lyon, ⁵Department of Medical Genetics, Jeanne de Flandre Hospital, Lille and ⁶Department of Dermatology, Hôtel Dieu Hospital, Lyon, France

Rothmund Thomson syndrome is a rare autosomal recessive skin disorder. The main clinical feature is poikiloderma appearing in early childhood associated with skeletal abnormalities. Early occurrence of malignancies is another relevant feature. Here we describe the clinical features of 2 patients with Rothmund Thomson syndrome who were investigated for the *in vitro* DNA repair capacities of blood cells following UVC radiation exposure. DNA excision repair, assessed with unscheduled DNA synthesis following UVC exposure, was decreased in both patients. Such a defect might explain the patients' sensitivity to sunlight and the relatively high risk of cancer associated with this syndrome. Key words: Rothmund Thomson Syndrome; DNA excision repair.

(Accepted October 5, 1998.)

Acta Derm Venereol (Stockh) 1999; 79: 150–152.

F. Vasseur, Laboratoire de Génétique des Maladies Multifactorielles CNRS EP10, CHRU Lille et Institut Pasteur, 1 rue du Professeur Calmette BP 245, FR-59019 Lille cedex, France.

Rothmund Thomson syndrome (RTS) is a rare autosomal, recessive dermatosis characterized by poikiloderma (telangiectasia, pigmentary changes and cutaneous atrophy) associated with multisystem disorders, the most afflicting being skeletal and ocular abnormalities (1). Manifestations of photosensitivity, including erythema and bullous eruption after exposure to sunlight, are seen in about 30% of patients (2). However, phototesting is rarely reported and the available data are inconsistent (3). Early occurrence of skin malignancies is another relevant feature of the syndrome (3). Photosensitivity and the high risk of cancer might be related to reduced DNA-repair capacity, which has been demonstrated in a few patients (4, 5). We describe here 2 patients with RTS displaying a significant DNA excision repair defect, one of whom has been partially described previously (6).

PATIENTS AND METHODS

Clinical findings for both patients are summarized in Table I. For case 1, the results of phototesting procedures were normal. Phototests were performed with a xenon solar simulator emitting wavelengths from 290 to 670 nm (Dermolum[®] Müller Elektronik, Germany) and a UVA lamp emitting wavelengths from 330 to 440 nm (UVA SUN 3000[®], Mutzhas Comp., Germany). The emission (mW/cm²) was measured by a calibrated thermopile. MED (707 mJ/cm²) determined 24 h after exposure with increasing doses of solar simulator light (increment 1,414, from 250 to 4,000 mJ) was within the normal range for our laboratory. Repeated exposures using UVB selected from the solar simulator with a WG 345 nm cut-off filter, every 48 h up to 10 MED, induced a mild erythema at 96 h corresponding to a normal reaction for the dose received. The delayed reaction was normal,

showing only a slight pigmentation. Repeated exposures to UVA (20 J/cm²) every 48h up to 60 J/cm² did not induce erythema. For case 2, the results of phototesting showed a normal ranged MED according to the values of our laboratory for skin type V. Repeated exposures using a xenon solar simulator for 3 consecutive days induced only a slight erythema on involved forearm skin as well as non-involved skin on the back. No delayed reaction was noticed up to 2 weeks later. Immunological data revealed a mild deficiency of cell-mediated immunity, with a negative PPD skin test, a CD4 count of 330/mm³ and a low CD4/CD8 ratio of 0.66. The karyotype obtained for stimulated peripheral blood lymphocytes was also normal.

Quantification of DNA excision repair was carried out with an unscheduled DNA synthesis assay (UDS) following 254 nm UV irradiation, and quantitative autoradiography as previously described (7, 9). Cells were irradiated with a 254 nm UV lamp (Bioblock, Strasbourg, France). UV emission was measured with a VLX254 radiometer (Bioblock, Strasbourg, France). The cells from a previously described PIBIDS patient (8) belonging to the XP-D complementation group were included in the experiments and processed in parallel. Autoradiographies were performed with the Kodak NTB2 liquid nuclear emulsion (Eastman Kodak, Rochester, USA). Background values (11) for both patient and control were accounted for the number of autoradiographic grains averaged from 50 random unirradiated cells both from the patient and the normal control. The label values (12),

Table I. Clinical features of patients with Rothmund Thomson syndrome

| Case 1 (French Caucasian) | Case 2 (Tunisian) |
|-------------------------------------------------------|------------------------------------------------|
| 17 years old | 16 years old |
| Male | Female |
| Parents are first cousins | Parents are first cousins |
| Poikilodermy of the face | Poikilodermy of the face |
| Keratosis on the hands | Hyperkeratotic lesions of the knees and elbows |
| Atrophy of the epidermis with dermal melanin deposits | |
| Sun sensitivity (easy burning) | |
| “café au lait” spots on the trunk arms and legs | |
| Short stature | Short stature |
| Delayed sexual development | Absence of pubic and axillary hair |
| Micrognathism | Bird-like appearance of the face |
| Spindle-shaped nose | Absence of thumb and radius |
| | Opposite clinodactyly of the fore finger |
| | Curved ulnar bone |
| | Bilateral hypoplasia of the patella |
| | Genu valgum |
| Bilateral cataract | |
| Pathological fractures of ribs and shinbone | Spontaneous fracture of the tibia |
| | Bone fragility |

were obtained from an average count of 50 random UV irradiated cells from both patient and control. Specific excision repair labels are equal to I2 minus I1. These values obtained from the patients were compared with the values from the normal control, the latter being taken as the 100% reference level. Statistical differences between patient and control was evaluated with the unpaired Student's *t*-test.

RESULTS

Excision repair for patient 1 was investigated in lymphocytes following a 10 J/m² 254 nm UV irradiation. Average silver grain count, specific for excision repair (I2-I1) was 31.3 for normal cells, 3.7 for the repair deficient (XP-D) cells and 17.9 for patient 1, respectively (Fig. 1). A significant difference ($p < 0.0001$) was noticed between patient 1 and control, residual excision repair level of patient 1 was 57.1% of the normal control levels. DNA excision repair of patient 2 was first analysed in lymphocytes. Following a 10 J/m² 254 nm UV irradiation, average silver grains count, specific for excision repair was 18.4 for patient 2 and 30.2 for control cells, ($p = 0.0081$). The repair level was 60.9%. Similar results have been obtained following a 30 J/m² UV irradiation with an average count of 27.3 grains of specific excision repair label per cell for patient 2 and 49.1 for control cells, ($p < 0.0001$)

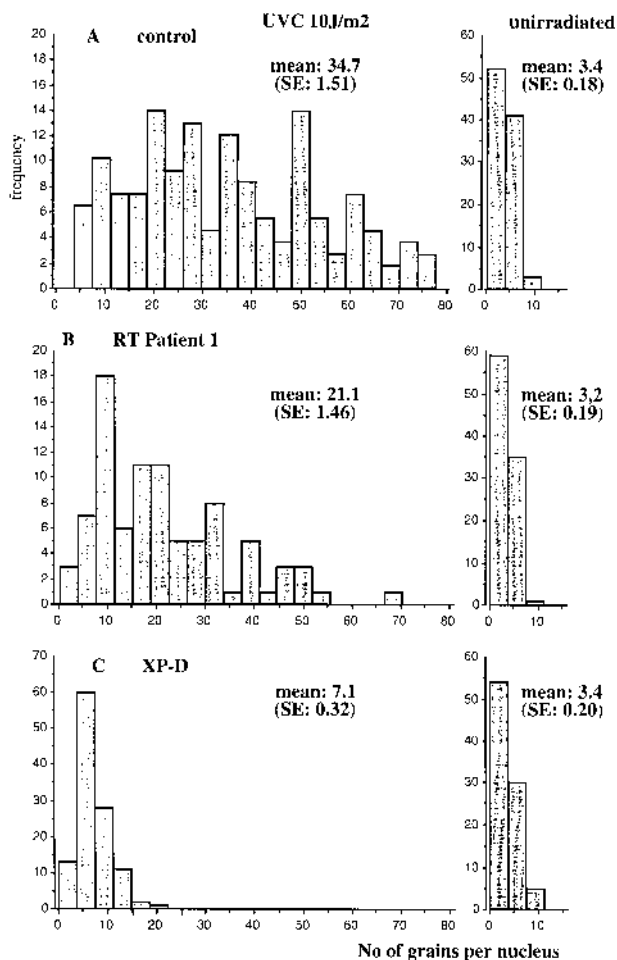


Fig. 1. Distribution of the blood cell label following 10 J/m² UV irradiation of (A) a normal control, (B) a patient with Rothmund Thomson syndrome (case 1) and (C) an XP-D patient. non-irradiated cells are on the right. Standard errors are given in brackets.

(Fig. 2). Repair level was 55.6%. For patient 2, additional excision repair analyses were performed on skin fibroblasts. The results were completely in agreement with those obtained on blood cells, with 64% and 72% residual repair activities of skin fibroblasts following a 30 J/m² 254 nm UV irradiation, after 2 and 7 subcultures.

DISCUSSION

Patients with RTS present variable clinical features and the syndrome appears quite heterogeneous (3) with a high incidence of cutaneous and non-cutaneous malignancies (3, 10). Besides diseases clearly associated with a DNA repair deficiency and/or abnormal sunlight sensitivity (11), the existence of any impairment in DNA repair mechanisms in RTS remains controversial (5, 12, 13, 14, 15). We describe here 2 unrelated RTS patients with DNA excision repair defects. To our knowledge, only 2 other RTS patients with DNA repair defects have been previously reported (4, 16). Our data provide new evidence that a DNA excision repair defect may exist in some cases of RTS. Chromosomal instability (12, 13), increased sister chromatid exchange and chromosomal breakage (14, 15) reported in RTS patients are in favour of an impairment in DNA metabolism. It is tempting to associate it with the high incidence of non-cutaneous malignancies, such as osteosarcoma (17) and particularly with the early onset of skin malignancies reported in RTS (3, 18). Moreover, DNA repair investigations gave controversial results in RTS patients with osteosarcoma (19, 20). In the patients described here, no malignancy has occurred to this date; however, they are still young. However, the older brother of patient 2, was also affected with RTS, and died due to osteosarcoma of the shinbone at 11 years of age. We did not have the opportunity to test this patient. In diseases where a repair defect has been clearly demonstrated, a genetic and a clinical heterogeneity has been reported and the molecular defects lies in genes

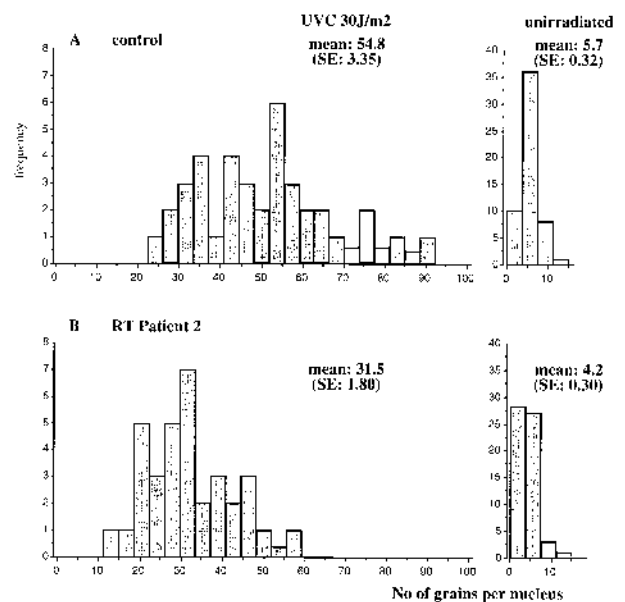


Fig. 2. Distribution of the blood cell label following 30 J/m² UV irradiation of (A) a normal control and (B) a patient with Rothmund Thomson syndrome (case 2). Non-irradiated cells are on the right. Standard errors are given in brackets.

coding for proteins that interact with DNA (21) and those involved in DNA metabolism (22, 23). These pathways could be impaired in RTS and may involve nucleotide excision repair in some cases of RTS. As previously reported for TTD, Cockayne syndrome (CS), XP-F and some XP-B and G patients, an excision repair defect does not always imply skin photosensitivity and/or high risk of cancer (24–26). UDS and quantitative autoradiography remain time-consuming repair analyses. The alkaline comet assay has been proved to be an easier repair test for the diagnosis of repair defects (27) and would facilitate the investigation of most RTS patients. Further investigations for other defects in the DNA metabolism, such as transcription (28) or interactions between other cellular repair mechanisms (29) remain promising. Genetic complementation experiments may shed light on the possibility of a relationship between RT and the previously identified genetic defects of XP, CS and TTD.

ACKNOWLEDGEMENTS

We thank the patients and their parents for their co-operation, Jean Pierre Tietard for technical assistance, and Suren Budhan and Gokhan Osizik for correcting the manuscript.

REFERENCES

- Taylor WB. Rothmund's syndrome, Thomson's syndrome. *Arch Dermatol* 1957; 75: 236–244.
- Berg E, Chuang TY, Cripps D. Rothmund Thomson syndrome. A case report, phototesting and literature review. *J Am Acad Dermatol* 1987; 17: 332–338.
- Vennos EM, Collins M, James WD. Rothmund-Thomson syndrome: review of the world literature. *J Am Acad Dermatol* 1992; 27: 750–762.
- Shinya A, Nishigori C, Moriwaki S, Takebe H, Kubota M, Ogino A, Imamura S. A case of Rothmund Thomson syndrome with reduced DNA repair capacity. *Arch Dermatol* 1993; 129: 332–336.
- Smith PJ, Paterson MC. Enhanced radiosensitivity and defective DNA repair in cultured fibroblasts derived from Rothmund Thomson syndrome patients. *Mutat Res* 1982; 94: 213–228.
- Barrut D, Goujon-Henry C, Thomas L, Vasseur F, Moulin L. Poikilodermie congénitale type Thomson avec anomalie de l'excision-réparation de l'ADN. *Ann Dermatol Venereol* 1993; 120: 755–758.
- Vasseur F, Marlier-Facon C, Delaporte E, Thomas P, Bergoend H, Savary JB. Excision repair analysis and skin response to UV-B in young patients with basal cell carcinoma. *Nouv Dermatol* 1994; 13: 321–328.
- Van Neste D, Caulier B, Thomas P, Vasseur F. PIBIDS: Tay's syndrome and xeroderma pigmentosum. *J Am Acad Dermatol* 1985; 12: 372–373.
- Vasseur F, Thomas P, Caulier B, Savary JB, Deminatti M. Apport de l'étude de l'excision réparation de l'ADN au diagnostic des géophotodermatoses. *Nouv Dermatol* 1990; 9: 424–430.
- Van Hees CLM, Van Duinen CM, Bruijin JA, Vermeer BJ. Malignant eccrine poroma in a patient with Rothmund Thomson syndrome. *Br J Dermatol* 1996; 134: 813–815.
- Cleaver JE, Thomas GH. Clinical syndromes associated with DNA repair deficiency and enhanced sun sensitivity. *Arch Dermatol* 1993; 129: 348–350.
- Orstravik KH, Mc Fadden N, Hagelsteen J, Ormerod E, van der Hagen CB. Instability of lymphocytes chromosomes in a girl with Rothmund Thomson syndrome. *J Med Genet* 1994; 31: 570–572.
- Der Kaloustian VM, Mc Gill JJ, Vekemans M, Kopelman HR. Clonal lines of aneuploid cells in Rothmund Thomson syndrome. *Am J Med Genet* 1990; 37: 336–339.
- Melaragno MI, Smith M. Sister chromatid exchange and proliferation pattern in lymphocytes from newborn, elderly subjects and in premature ageing syndromes. *Mech Ageing Dev* 1990; 54: 43–53.
- Moss C, Bacon CJ, Mueller CJ. Isolated radial ray defect may be due to Rothmund Thomson syndrome. *Clin Genet* 1990; 38: 318–319.
- Prache de Carrère B, Teillac-Hamel D, Capesius C, Castelneau JP, Robert C, Fraitag S, de Prost Y. Syndrome de Rothmund Thomson avec anomalie de l'excision réparation de l'ADN. *Ann Dermatol Venereol* 1996; 123: 395–397.
- Drouin CA, Mongrain E, Sasseville D, Bouchard HL, Drouin H. Rothmund Thomson syndrome with osteosarcoma. *J Am Acad Dermatol* 1993; 28: 301–305.
- Davies MG. Rothmund Thomson syndrome and malignant disease. *Clin Exp Derm* 1982; 7: 455–457.
- Starr DG, Mc Clure JP, Connor JM. Non dermatological complications and genetic aspects of the Rothmund-Thomson syndrome. *Clin Genet* 1985; 27: 102–104.
- Judge MR, Kilby A, Harper JJ. Rothmund Thomson syndrome and osteosarcoma. *Br J Dermatol* 1993; 129: 134–137.
- Bootsma D, Weeda G, Vermeulen W, van Vuuren H, Troelstra C, van der Speck P, Hoeijmakers J. Nucleotide excision repair syndromes: molecular basis and clinical symptoms. *Philos Trans R Soc Lond B Biol Sci* 1995; 347: 75–81.
- He Z, Henricksen LA, Wold MS, Ingles CJ. RPA involvement in the damage-recognition and incision steps of nucleotide excision repair. *Nature* 1995; 374: 566–569.
- Drapdkin R, Reardon JT, Ansari A, Huang JC, Zavel L, Ahn K, Sancar A, Reinberg D. Dual role of TFIIH in DNA excision repair and in transcription by RNA polymerase II. *Nature* 1994; 368: 769–772.
- Moriwaki SI, Stefanini M, Lehman AR, Hoeijmakers JHJ, Robbins JH, Rapin I, et al. DNA repair and ultraviolet mutagenesis in cells from a new patient with xeroderma pigmentosum group G and Cockayne syndrome resemble xeroderma pigmentosum cells. *J Invest Dermatol* 1996; 107: 647–653.
- Stefanini M, Lagomarsini P, Giliani S, Nardo T, Botta E, Peserico A, Kleijer WJ, Lehmann AR, Sarasin A. Genetic heterogeneity of the excision repair defect associated with trichothiodystrophy. *Carcinogenesis* 1993; 14: 1101–1105.
- Vermeulen W, Scott RJ, Rodgers S, Muller HJ, Cole J, Arlett CF, et al. Clinical heterogeneity within xeroderma pigmentosum associated with mutations in the DNA repair and transcription gene ERCC3. *Am J Hum Genet* 1994; 54: 191–200.
- Alapetite C, Benoit A, Moustacchi E, Sarasin A. The comet assay as a repair test for prenatal diagnosis of Xeroderma pigmentosum and trichothiodystrophy. *J Invest Dermatol* 1997; 108: 154–159.
- Gudzer SN, Sung P, Prakash S, Prakash L. Lethality in yeast of trichothiodystrophy (TTD) mutations in the human xeroderma pigmentosum group D gene. Implications for transcriptional defect in TTD. *J Biol Chem* 1995; 270: 17660–17663.
- Venema J, Mullenders LH, Natarajan AT, van Zeeland AA, Mayne LV. The genetic defect in Cockayne syndrome is associated with a defect in repair of UV-induced DNA damage in transcriptionally active DNA. *Proc Natl Acad Sci USA* 1990; 87: 4707–4711.