

## Persistent Herpes Gestationis Treated with High-dose Intravenous Immunoglobulin

Carla dos Santos Rodrigues, Paulo Filipe, Maria del Mar Solana, Luis Soares de Almeida, José Cirne de Castro and Manuel Marques Gomes

*Clínica Universitária Dermatológica do Hospital de Santa Maria, Av. Prof. Egas Moniz, PT-1649-028 Lisbon, Portugal. E-mail: carla.sereno@gmail.com*  
Accepted October 12, 2006.

Sir,

Pemphigoid gestationis (PG) is a rare autoimmune blistering disease specific to pregnancy that usually presents in the second or third trimester or during the immediate postpartum period (1, 2). PG may develop in association with other autoimmune diseases, as well as with trophoblastic tumours, hydatiform mole and choriocarcinoma (3).

The pathogenesis of PG is not fully established. However, most patients develop antibodies against 2 hemidesmosomal proteins, BP180 (BPAG2, collagen XVII) and, less frequently, BP230. Historically known as the herpes gestationis factors, these circulating antibodies belong to the heat-stable immunoglobulin G1 subclass. Sera from PG can recognize 5 distinct epitopes within BP180 NC16A, 4 of which have been reported as major antigenic sites targeted by bullous pemphigoid antibodies (4).

The PG has a strong association with human leukocyte antigens HLA-DR3 and HLA-DR4 or both, and virtually all patients with a history of PG have demonstrable anti-HLA antibodies (5).

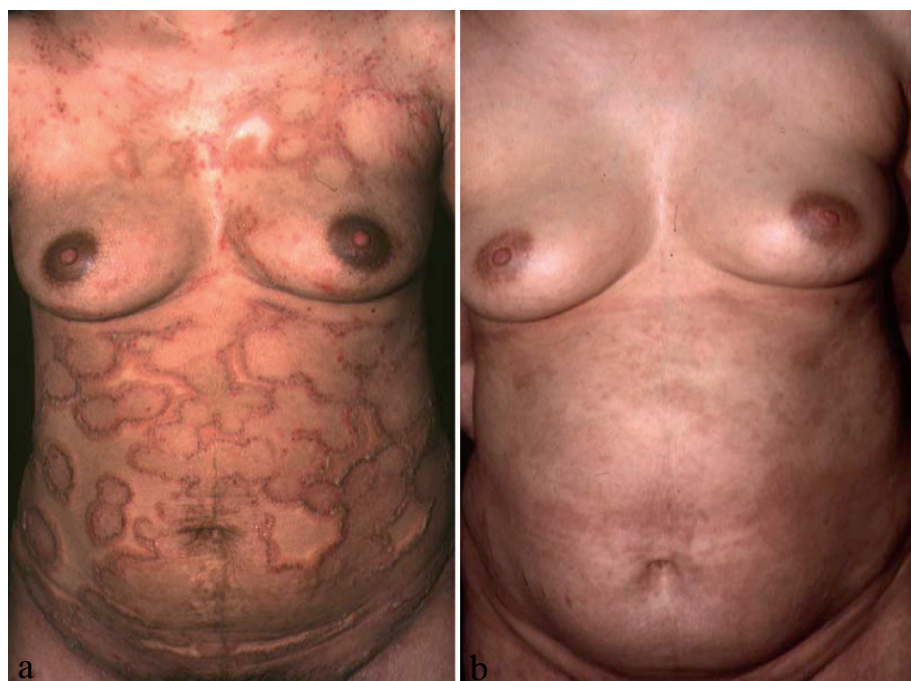During pregnancy PG is often treated with topical corticosteroids and systemic antihistamines. However, in some patients with severe disease, systemic steroid therapy is needed. If the disease continues, treatment options are limited. Although plasmapheresis, cyclo-

phosphamide, azathioprine, cyclosporine and dapsone, as monotherapy or in combined regimens all have been reported to be beneficial, they have potential side-effects that can be harmful to both the mother and the foetus (6, 7).

There are only 2 case reports in the literature describing the use of intravenous immunoglobulin (IVIg) therapy in PG (6, 8). We report here a persistent case of PG, refractory to the conventional treatment with steroid plus azathioprine or dapsone, which responded positively to IVIg.

### CASE REPORT

A 31-year-old woman developed pruritic erythematous-oedematous figured papular lesions on the second day after delivery, in her first pregnancy. Over the next 3 weeks, the eruption became widespread with the typical erythematous grouped papular eruption associated with vesicles, blisters and scaling crusts over the thighs, trunk and arms (Fig. 1A). A clinical diagnosis of PG was made. This was supported by the histopathology of a skin lesion, which showed a subepidermal vesicle, and a superficial lymphohistiocytic infiltrate with many eosinophils (Fig. 2A). Direct immunofluorescence (IF) demonstrated a bright linear deposition of C3 without IgG and IgM, along the basement membrane (Fig. 2B), and indirect IF revealed circulating anti-C3 to a titre of 1:20. Routine haematology, biochemistry and an autoantibody screen were normal.



*Fig. 1. (A) Numerous erythematous-oedematous figured lesions, with grouped vesicles and bullae just after post-partum. (B) Complete resolution of lesions after 4 cycles of IVIg.*

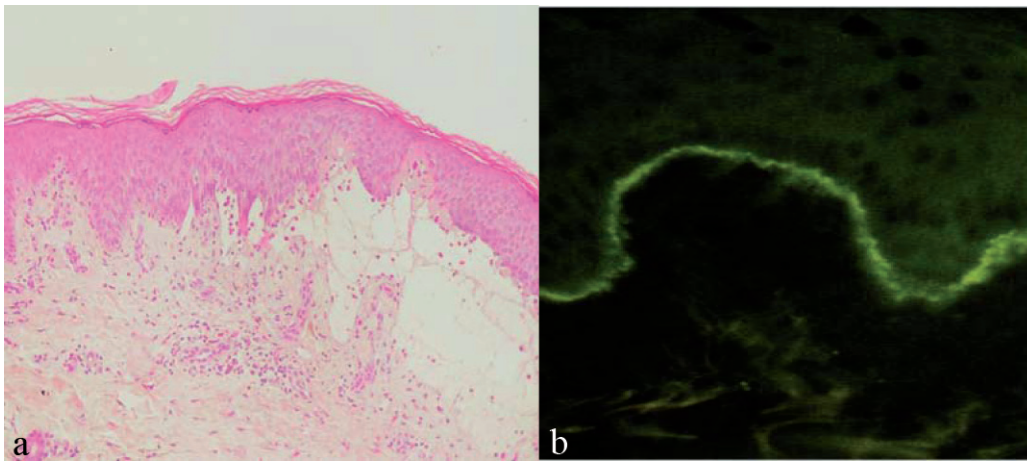


Fig. 2. (A) Subepidermal vesicle, and a superficial lymphohistiocytic infiltrate with many eosinophils. (B) Direct immunofluorescence demonstrated a linear epidermal deposit of C3 consistent with the hallmark of pemphigoid gestationis (PG).

HLA typing of the patient and her husband revealed the HLA-DR3 phenotype in both.

She was admitted to our department and commenced on 70 mg/day oral prednisone.

The dose was gradually reduced for the next 6 weeks to 40 mg/day oral prednisone, with partial clinical remission. At 16 weeks post-partum she experienced an exacerbation and azathioprine was introduced initially at a dose of 100 mg/day, and then increased to 150 mg/day until week 20 post-partum, without improvement. At this point azathioprine was changed to dapsone 100 mg/day together with 40 mg of oral prednisone.

As she became markedly Cushingoid, an attempt was made to lower the prednisone dose over the next 4 weeks. Unfortunately, at the prednisone dose of 10 mg/day in combination with dapsone, the disease reactivated. She was then given a high-dose IVIg 0.4 g/kg/day on 5 consecutive days every 4 weeks for the next 6 months. An improvement in the pruritus was observed after the first course of IVIg. After the fourth cycle of IVIg we observed a complete remission of the disease (Fig. 1B) and her C3 titres were negative.

## DISCUSSION

Clinical, histopathological and immunopathological features of PG are similar to pemphigoid. It is currently believed that these diseases may be related, and there are some case reports of the evolution of PG to classical pemphigoid (9). PG has been associated with the presence of HLA DR3 and DR4 (5, 10). The former was observed with our patient and in her husband. Like many previous cases, the disease presented clinically as erythematous, annular urticarial plaques on which blisters develop with frequent involvement of the periumbilical area (11).

The patient presented here demonstrated severe disease refractory to conventional treatment with high-dose corticosteroids and adjuvant immunosuppressive therapy. IVIg has long been used in the treatment of many antibody-mediated diseases, such as bullous pemphigoid, pemphigus vulgaris and pemphigus foliaceus, with successful suppression of blisters, allowing at the same time a reduction in the dose of corticosteroids (12, 13). The mechanism of action of IVIg is not well

understood, but it is thought to interact with several immune-mediated pathways, such as functional blockade of Fc receptors on splenic macrophages, inhibition of complement-mediated damage, modulation of the production of cytokines and cytokine antagonists, neutralization of circulating autoantibodies by anti-idiotypic antibodies in IVIg, neutralization of pathogens involved in the aetiology of the autoimmune disease, and blockade of Fas receptors by anti-Fas antibodies present in IVIg (6).

## ACKNOWLEDGEMENT

We are grateful to Professor M. Black for his expertise in this case.

## REFERENCES

1. Scott JE, Ahmed AR. The blistering diseases. *Med Clin North Am* 1998; 82: 1239–1283.
2. Jordan RE, editor. Atlas of bullous disease. Philadelphia: Churchill Livingstone, 2000.
3. Shornick J, Black M. Secondary autoimmune diseases in herpes gestationis (Pemphigoid gestationis). *J Am Acad Dermatol* 1992; 26: 563–566.
4. Chimanovitch I, Schmidt E, Messer G, Dopp R, Partscht K, Brocker EB, et al. IgG1 and IgG3 are the major immunoglobulin subclasses targeting epitopes within the NC16A domain of BP180 in pemphigoid gestationis. *J Invest Dermatol* 1999; 113: 140–142.
5. Shornick JK, Jenkins RE, Artlett CM, Briggs DC, Welsh KI, Kelly SE, et al. Class II MHC typing in pemphigoid gestationis. *Clin Exp Dermatol* 1995; 20: 123–126.
6. Hern S, Harman K, Bhogal BS, Black MM. A severe persistent case of pemphigoid gestationis treated with intravenous immunoglobulins and cyclosporine. *Clin Exp Dermatol* 1998; 23: 185–188.
7. Van de Wiel A, Hart HC, Flinterman J, Kerckhaert JA, Du Boeuff JA, Imhof JW. Plasma exchange in herpes gestationis. *BMJ* 1980; 281: 1041–1042.
8. Kreuter A, Harati A, Breuckmann F, Appelhans C, Altmeyer P. Intravenous immune globulin in the treatment of persistent pemphigoid gestationis. *J Am Acad Dermatol* 2004; 51: 1027–1028.
9. Jenkins RE, Vaughan Jones SA, Black MM. Conversion of pemphigoid gestationis to bullous pemphigoid – two

- refractory cases highlighting this association. *Br J Dermatol* 1996; 135: 595–598.
10. Shornick JK, Stastny P, Gilliam JN. High frequency of histocompatibility antigens HLA D3 and DR4 in herpes gestationis. *J Clin Invest* 1981; 68: 553–555.
  11. Boulinguez S, Bedane C, Prost C, Bernard P, Labbe L, Bonnetblanc JM. Chronic pemphigoid gestationis: comparative clinical and immunopathological study of 10 patients. *Dermatology* 2003; 206: 113–119.
  12. Jolles S. A review of high-dose intravenous immunoglobulin (hdIVIg) in the treatment of the autoimmune blistering disorders. *Clin Exp Dermatol* 2000; 26: 127–131.
  13. Harman KE, Black MM. High-dose intravenous immunoglobulin for the treatment of autoimmune blistering diseases: an evaluation of its use in 14 cases. *Br J Dermatol* 1999; 140: 865–874.