

Lichen Spinulosus in an Alcoholic Patient

Rieko Kabashima, Kazunari Sugita, Kenji Kabashima, Motonobu Nakamura and Yoshiki Tokura

Department of Dermatology, University of Occupational and Environmental Health, 1-1 Iseigaoka, Yahatanishi-ku, Kitakyushu, Fukuoka 807-8555, Japan. E-mail: r-kabaji@med.uoeh-u.ac.jp

Accepted October 6, 2008.

Sir,

Lichen spinulosus (LS) is a rare and benign disorder, characterized by the development of patches of small follicular papules with a central horny spine (1). Diseases such as keratosis pilaris and pityriasis rubra pilaris occasionally present with lesions that resemble LS (1–3). Idiopathic LS lesions usually occur on the trunk or extremities, mainly in children and adolescents (3). Although the hands, feet and face are usually spared in classically described LS (4), the generalized form of this condition has been reported in patients infected with human immunodeficiency virus (HIV) (2, 5). We report here a case of LS occurring on the face and the nuchal region in association with alcoholism.

CASE REPORT

A 59-year-old Japanese man was brought to our hospital by ambulance in a delirious status. He had a history of excessive alcohol consumption and liver dysfunction due to alcoholism. He also had atrophy of the brain, as assessed by computed tomography. He had developed a facial eruption 2 months previously when the alcoholic hepatic injury deteriorated. Physiological examination showed that he had patches of keratotic follicular papules on his forehead (Fig. 1A), cheeks, nasolabial fold and the posterior aspect of his neck. The individual lesions were asymptomatic, skin-coloured

papules, 1 mm in diameter, and consisted of a hairlike horny spine (Fig. 1B). A skin biopsy specimen of one papule on the forehead revealed irregularly acanthotic, hyperkeratotic epidermis with orthokeratotic infundibular plugs that projected above the skin surface (Fig. 1C). Perifollicular and perivascular inflammatory cells were seen in the dermis. These clinical and histological findings were consistent with a diagnosis of lichen spinulosus. The eruption improved within one week of abstention from alcohol and nutritional management with vitamin preparations.

DISCUSSION

The clinical and histological features in this case are consistent with a diagnosis of LS. However, the sites of eruption are different from the usual predilection sites of idiopathic LS; papules were prominent on the face, especially on the forehead, which is not commonly affected in idiopathic LS. Our patient is also unusual, because there have been few reports of LS in elderly patients. Although the underlying causes of LS remain unclear, atopic or other genetic backgrounds and infectious agents have been proposed (4). Some cases of LS are secondary to HIV infection (2, 5) or Crohn's disease (6). It might reflect an exaggerated cutaneous immunological response to hair-follicular organisms such as *Pityrosporum*. In these patients with secondary

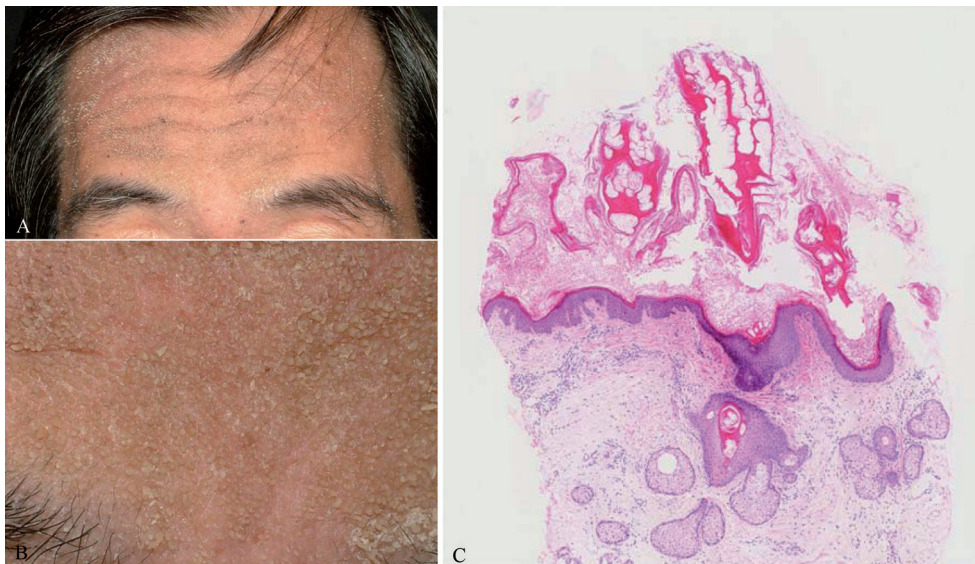


Fig. 1. Clinical appearance and histology. (A) Lichen spinulosus on the forehead. (B) Flat-to-conical papules bearing horny spines. (C) A biopsy specimen shows compact, keratinous plugs in a dilated hair follicle. A perivascular and perifollicular inflammatory cell infiltrate is observed (haematoxylin-eosin, original magnification $\times 100$).

LS, the eruptions tend to be generalized, and the age of onset is higher than that of idiopathic LS. Notably, there has been another report of a patient with secondary LS to chronic alcoholism (7). That patient had LS lesions for 2 months along with subnormal appetite and weakness, and responded successfully to ascorbic acid. The patients' nutritional status may play an important role for the pathogenesis of LS. Our patient was in a state of malnutrition due to alcoholism, and his eruption was alleviated by improving nutrition management.

Empirically, idiopathic LS has been treated with keratolytics and emollients (8). Tar preparations and topical corticosteroids may be useful occasionally, while resistant cases may respond to topical application of ammonium lactate lotions and vitamin A (8). In secondary LS treatment of systemic disorders may improve the eruptions, as seen in our patient, who responded well to abstinence.

REFERENCES

1. Friedman SJ. Lichen spinulosus. Clinicopathologic review of thirty-five cases. *J Am Acad Dermatol* 1990; 22: 261–264.
2. Cohen SJ, Dicken CH. Generalized lichen spinulosus in an HIV-positive man. *J Am Acad Dermatol* 1991; 25: 116–118.
3. Strickling WA, Norton SA. Spiny eruption on the neck. Diagnosis: lichen spinulosus (LS). *Arch Dermatol* 2000; 136: 1165–1170.
4. Boyd AS. Lichen spinulosus: case report and overview. *Cutis* 1989; 43: 557–560.
5. Resnick SD, Murrell DF, Woosley J. Acne conglobata and a generalized lichen spinulosus-like eruption in a man seropositive for human immunodeficiency virus. *J Am Acad Dermatol* 1992; 26: 1013–1014.
6. Kano Y, Orihara M, Yagita A, Shiohara T. Lichen spinulosus in a patient with Crohn's disease. *Int J Dermatol* 1995; 34: 670–671.
7. Irgang S. Lichen spinulosus responsive to ascorbic acid (vitamin C). Case in an alcoholic adult. *Skin* 1964; 117: 145–146.
8. Tilly JJ, Drolet BA, Esterly NB. Lichenoid eruptions in children. *J Am Acad Dermatol* 2004; 51: 606–624.