

CLINICAL REPORT

Drug-induced Papuloerythroderma: Analysis of T-cell Populations and a Literature Review

Kazunari SUGITA¹, Kenji KABASHIMA^{1,2}, Motonobu NAKAMURA¹ and Yoshiki TOKURA¹Department of Dermatology, ¹University of Occupational and Environmental Health, and ²Kyoto University Graduate School of Medicine, Kyoto, Japan

Papuloerythroderma of Ofuji is characterized by coalescent solid papules that spare the skin folds. Although cutaneous lymphomas and internal malignancies are known associated conditions, the causative agents are unclear in most cases. A number of recent reports have documented that drugs can induce papuloerythroderma. We reviewed the reported cases and our own cases of drug-induced papuloerythroderma, together with our data from lymphocyte transformation tests and T-cell subsets of peripheral blood. All of the 9 patients were male, and the causative drugs were various. Provocation tests were positive in all 6 patients examined. Whereas drug patch tests were negative in all 5 cases tested, the patients' peripheral blood lymphocytes responded well to the culprit drug in 4 of 5 patients tested. The patients had higher percentages of circulating CCR4⁺CD4⁺ T helper (Th) 2 cells than CXCR3⁺CD4⁺ Th1 cells. Drug-induced papuloerythroderma seems to be mediated by Th2 cells reacting with the causative drug. Key words: drug eruption; allergy; T cells.

(Accepted May 27, 2009.)

Acta Derm Venereol 2009; 89: 618–622.

Kazunari Sugita, Department of Dermatology, University of Occupational and Environmental Health, Japan, 1-1 Iseigaoka, Yahatanishi-ku, Kitakyushu 807-8555, Japan. E-mail: k-sugita@med.uoeh-u.ac.jp

Papuloerythroderma was first described in 1984 by Ofuji (1). This distinct disorder is characterized by coalescence

of solid papules, which typically spare the skin folds, presenting the so-called “deck-chair” sign. Although its association with cutaneous T-cell lymphoma as well as visceral carcinomas has been documented in a considerable number of cases, the aetiology of the condition is unclear in the vast majority of patients (2). However, recent reports have indicated that drugs are causative agents for papuloerythroderma (3, 4) and have suggested that drug-reactive T-helper (Th) 2 cells play an important role in the pathogenesis (5).

The populations of circulating T cells can be skewed upon occurrence of T-cell-mediated drug eruptions (6, 7). In the usual development of drug eruption, peripheral T cells react with a causative drug, migrate to the skin, and trigger dermatitis as a consequence of immunological or inflammatory responses (8). In this article, we review the clinical, laboratory, and histological features and the clinical outcome of drug-induced papuloerythroderma in the literature, including our own 4 published cases. We also characterize circulating T-cell populations in patients with drug-induced papuloerythroderma, focusing on the *in vitro* T-cell response to the causative drug and the Th1/T cytotoxic (Tc)1 or Th2/Tc2 polarization.

MATERIALS AND METHODS

Blood samples were taken from our patients with drug-induced papuloerythroderma (cases 5, 6, 8 and 9 in Table I), with informed consent before treatment. Peripheral blood mononuclear cells (PBMCs) were isolated from heparinized venous blood of

Table I. Reported cases of drug-induced papuloerythroderma

Case (Ref)	Age (years)	Sex	Country	Past or associated diseases	Causative drugs	Other drugs	Latency period
1 (15)	60	M	Spain	Allergic rhinitis, conjunctivitis	Nicardipine hydrochloride, nifedipine	Trichlormethiazide	2 weeks
2 (3)	31	M	Japan	AIDS	Dideoxyinosine	ND	1 month
3 (16)	66	M	Japan	None	Cellulose	ND	Obscure
4 (17)	75	M	Japan	Right eye injury	Isoniazid	Rifampicin, streptomycin, ethambutol	1 week
5 (5)	70	M	Japan	Cerebral infarction	Aspirin	Carvedilol	10 years ^a
6 (9)	79	M	Japan	Chronic eczema, heart failure	Furosemide	ND	4 months
7 (13)	80	M	Japan	Pneumonia, diabetes mellitus	Ranitidine hydrochloride	Codeine phosphate, trapidil	2 weeks
8 (18)	78	M	Japan	Hypertension, angina pectoris	Eperisone hydrochloride	ND	2 years and 5 months ^a
9 (14)	82	M	Japan	Hypertension, prostate cancer	Leuporelin acetate	Diltiazem hydrochloride	5 years ^a

^aIntermittently administered for the period.

ND: not described.

patients by means of Ficoll-Hypaque (Sigma Chemical Co., St Louis, MO, USA) density gradient centrifugation. An *in vitro* proliferation assay was performed as previously described, with some modification (9). Briefly, as culture medium, RPMI-1640 (Sigma-Aldrich, St Louis, MO, USA) was supplemented with 10% heat-inactivated foetal calf serum (FCS), 5×10^{-5} M 2-mercaptoethanol, 2 mM L-glutamine, 25 mM HEPES, 1 mM non-essential amino acids, and 1 mM sodium pyruvate. The culprit drugs used for the assay were unmodified parent drug compounds dissolved in culture medium, which were sonicated to suspend them in the medium. The concentration of the drugs was determined by referring Cmax, and serial 10-times dilution was performed around Cmax. Cultures were performed in triplicate at 37°C and 5% CO₂ for 3 days. Eighteen hours before harvesting, 1 µCi ³H-thymidine (Amersham, Arlington Heights, IL, USA) was added. After harvesting, radioactivity was measured in a liquid scintillation counter.

Flow cytometry was performed as described previously (7). Cells were double-stained with fluorescein isothiocyanate (FITC)-conjugated anti-CD4, anti-CD8 or anti-HLA-DR monoclonal antibody (mAb) and phycoerythrin (PE)-conjugated anti-CXCR3, anti-CCR4 mAb (all from PharMingen, San Diego, CA, USA) at 2 µg/10⁶ cells. Hanks' balanced salt solution containing 0.1% NaN₃ and 1% foetal calf serum was used as the staining buffer. After incubation for 30 min at 4°C with mAbs or control isotype-matched controls, cells were washed and collected on a FACSCanto (BD Biosciences, San Diego, CA, USA) and analysed with FlowJo software (TreeStar, San Carlos, CA, USA).

Data were analysed using an unpaired two-tailed *t*-test. $p < 0.05$ was considered to be significant.

RESULTS

Literature review

Tables I and II summarize the reported cases of drug-induced papuloerythroderma. The mean age of the 9 patients at diagnosis was 69 years, ranging from 31 to 82 years. All patients were male. In a retrospective study of papuloerythroderma irrespective of causes, there were 14 male and 3 female patients (male/female ratio 4.7:1) (10). In these patients, the age at diagnosis varied from 61 to 100 years, with a median age of 72 years.

The latency period of the skin rash varied from 1 week to 10 years, although some patients with long latency periods were given the causative drug intermittently. One-third of the patients had a history of heart disease. The causative drug was confirmed based on the timing regarding the administration of the drug and the onset of the eruptions (case 2), positive results of provocation test (cases 1, 3, 4, 5, 6 and 9) and positive reactions of lymphocyte transformation test (cases 5, 6, 7 and 8). The oral challenge test was performed with the culprit drug at one-fifth of the daily dose (5). We used the same procedure in our cases (cases 5 and 6). The detail of procedure in case 4 was not described. A variety of drugs were causative, and there was no preponderant drug. Most patients achieved partial remission with the initial treatment, such as systemic prednisolone and/or narrowband ultraviolet (UV)-B irradiation.

Table II. Laboratory data and clinical course in the reported cases

Case (Ref)	Eosinophils	Histology	Provocation test		Patch test		Lymphocyte transformation test			Clinical course		
			Causative drugs	Other drugs	Causative drugs	Other drugs	Causative drugs	Other drugs	Treatment			
1 (15)	2500/µl	Perivascular infiltrate of lymphocytes and eosinophils	Positive	ND	ND	ND	ND	ND	ND	ND	Remission	
2 (3)	ND	CD8+ T cells, eosinophils, and giant cells in the dermis	ND	ND	ND	ND	ND	ND	PUVA	PUVA	Remission	
3 (16)	ND	ND	Positive	ND	ND	ND	ND	ND	Oral steroid	Oral steroid	ND	
4 (17)	5000/µl	Perivascular infiltrate of lymphocytes and eosinophils	Positive	Negative (Rifampicin)	Negative	Negative (rifampicin, ethambutol)	Negative	ND	ND	Oral steroid	Oral steroid	Remission
5 (5)	816/µl	Exocytosis of CD4+ T cells and perivascular infiltrate of lymphocytes and eosinophils	Positive	NT	Negative	Negative (carvedilol)	Positive	Negative (carvedilol)	ND	Narrowband UVB	Narrowband UVB	Remission
6 (9)	678/µl	Perivascular infiltrate of lymphocytes and eosinophils	Positive	ND	Negative	ND	Positive	ND	ND	Topical steroid	Topical steroid	Improvement
7 (13)	2737/µl	Perivascular infiltrate of lymphocytes and eosinophils	ND	ND	Negative	Negative (codeine phosphate, trapidil)	Positive	Negative (codeine phosphate, trapidil)	ND	Oral steroid	Oral steroid	Remission
8 (18)	ND	Perivascular infiltrate of lymphocytes and eosinophils	ND	ND	Negative	ND	Positive	ND	ND	Oral steroid	Oral steroid	Remission
9 (14)	1128/µl	Perivascular infiltrate of lymphocytes and eosinophils	Positive	NT	ND	ND	ND	ND	ND	Oral steroid	Oral steroid	Improvement

ND: not described, NT: not tested, LTT: lymphocyte transformation test; UVB: ultraviolet B; PUVA: psoralen UVA.

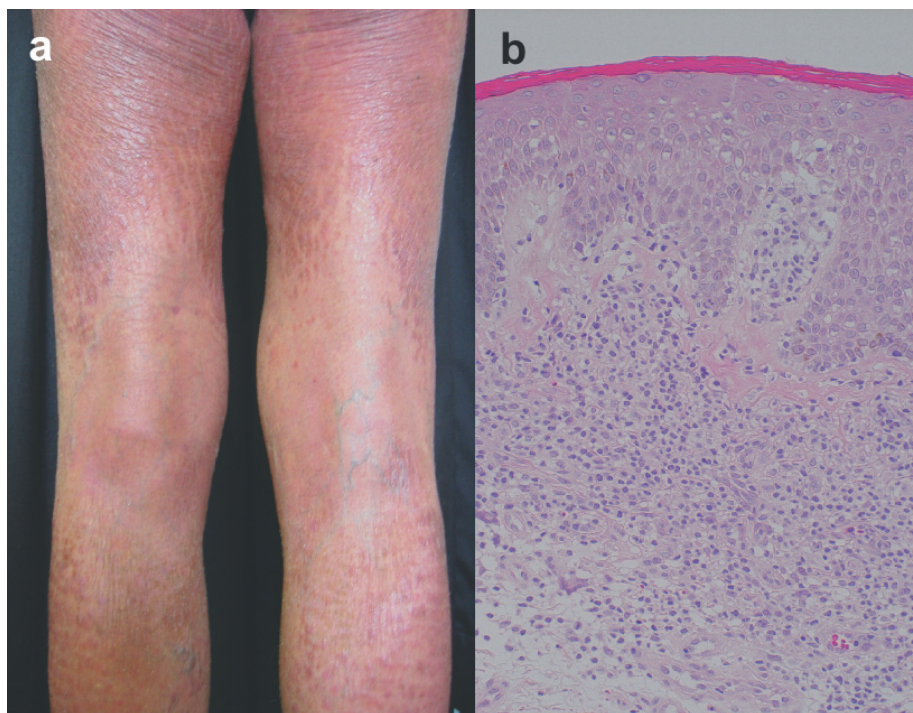


Fig. 1. Clinical appearance and histology of typical papuloerythroderma (case 5). (a) Diffuse coalesced papules on the lower legs. (b) Histological picture showing lymphocytic infiltrate intermingled with eosinophils in the upper dermis and exocytosis of lymphocytes. (haematoxylin-eosin, original magnification $\times 100$).

The eruptions were different from the usual acute type of drug exanthema, as they were chronically seen, presumably in association with pre-existing eczematous dermatitis (Fig. 1a). Six of 9 patients showed mild blood eosinophilia, and the maximum eosinophil count was $5000/\mu\text{l}$. There was no concomitant allergic or parasitic diseases except for one case (case 1) of allergic rhinitis and conjunctivitis (Table II). The blood eosinophil count changed in parallel with the disease activity, and returned to within the normal range after remission (5). A perivascular inflammatory infiltrate confined to the upper dermis was present in all the skin specimens (Fig. 1b, Table II). The infiltrate typically consisted of lymphocytes and eosinophils.

Provocation tests by administration of the drugs were positive in all 6 patients tested. In all 5 patients

examined, skin patch tests of the culprit drugs did not yield any positive findings (Table II).

In our cases 5 and 9, the patients took several drugs. Considering the time-points of the initial intake of the medicines and the exaggeration of the eruptions, we selected aspirin and leuprorelin acetate as culprit medicines, respectively, and performed the provocation tests with them.

Lymphocyte transformation test

In our cases 5, 6 and 8, lymphocyte transformation tests were performed to detect antigen-specific sensitized lymphocytes by co-culture of the freshly isolated patients' lymphocytes with the culprit medicines. Fig. 2 shows the data with the representative concentration

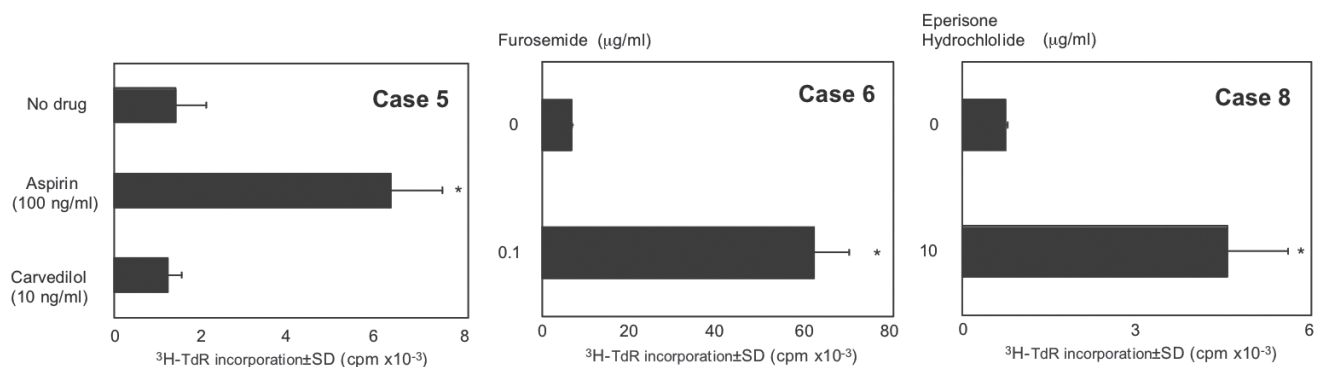


Fig. 2. Lymphocyte transformation test. Patients' peripheral blood mononuclear cells (PBMCs) were cultured for 72 h with a respective culprit drug, aspirin, furosemide or eperisone hydrochloride at the indicated final concentration. Carvedilol was the drug that the individual patient took concomitantly with the causative drugs. As a positive control, PBMCs were cultured with concanavalin A ($3 \mu\text{g/ml}$) (case 5, $56,293 \pm 4,043$; case 6, $72,697 \pm 1,949$; and case 8, $22,824 \pm 3,494$). Data are expressed as the mean \pm SD of triplicate cultures. * $p < 0.01$ compared with control.

of drugs determined on the basis of Cmax. The addition of the respective drug to the culture induced the proliferation of PBMCs in all 3 patients. The negative control drug that the individual patient took concomitantly did not stimulate the PBMCs. The lymphocyte stimulation tests of cases 4 and 7 were reported to be negative and positive, respectively (Table II). Collectively, 4 of 5 patients were positive for the lymphocyte stimulation test.

Flow cytometric analysis

PBMCs obtained at the active stage of our patients (cases 5, 6, 8 and 9) were examined in the percentages of CD4⁺ and CD8⁺ cells bearing T-cell activation marker HLA-DR. The mean percentages of CD4⁺ (34.8%, 33.3–37%) and CD8⁺ (19.4%, 14.2–27%) cells were within normal ranges (CD4, 33.0–46.1%; CD8, 19.0–32.4%) (Fig. 3a). CD4⁺ cells bearing HLA-DR were high in percentage compared with normal healthy subjects (Fig. 3b), suggesting the activated state of CD4⁺ cells in drug-induced papuloerythroderma. We also analysed a difference between normal healthy controls and drug-induced papuloerythroderma in CXCR3⁺CD4⁺ (Th1), CCR4⁺CD4⁺ (Th2), CXCR3⁺CD8⁺ (Tc1) and CCR4⁺CD8⁺ (Tc2) subsets. The percentages of Th2 and Tc2 cells outnumbered Th1 and Tc1 cells, respectively (Fig. 3c, d).

DISCUSSION

We reviewed the reported cases of papuloerythroderma caused by drugs and clinically characterized this unique chronic type of drug eruption. Drug-induced papuloerythroderma is different from generalized maculopapular drug eruption, in that it exhibits coalesced solid papules and “deckchair sign”, sparing the abdominal folds. The axillae, inguinal regions and cubital fossae are also fairly clearly spared. In addition, papuloerythroderma differs from ordinary erythroderma, in that population is prominent (11) and it usually shows persisting pruritus.

Our review of the literature revealed that all of the 9 patients were male. The causative drugs were various, and the duration of their administration varied from 2 weeks to 10 years, with a mean of 2 years and 3 months. A pre-existing eczematous dermatitis before the real drug eruption might overestimate the latency period of drug intake. Despite the chronic type of dermatitis, provocation tests were positive in all 6 patients examined. Whereas drug patch tests were negative in all 5 cases tested, the patients' peripheral blood lymphocytes responded well to the culprit drugs in 4 of 5 patients. In the patch tests, it is possible that the drugs do not sufficiently penetrate through the cornified layer of the epidermis, resulting in the discrepancy of the results between the patch tests and LTT. Alternatively, the strong Th2-skewing response to the drugs might induce the lack of contact sensitivity.

This study also provided several important findings on the numerical changes in peripheral T-cell populations upon occurrence of drug-induced papuloerythroderma. There have been various findings in the T-cell populations responsible for the development of drug eruptions in general. Drug-reactive T-cell clones established from patients' blood varies from Th1 and Tc1 to Th2 cells (12). Th2 cells infiltrate in the skin lesions of maculopapular eruption, and β -lactam-specific T cells are Th2 cells (6, 7). The predominant circulating T-cell populations are Th1 cells in Stevens-Johnson syndrome and erythema multiforme, and Th2 cells in maculopapular eruption (7). Our study demonstrated that Th2 cells are the propagating population in papuloerythroderma. This is consistent with the skin infiltration of eosinophils as well as eosinophilia in many of the cases of drug-induced papuloerythroderma (see Table II). However, it should be kept in mind that the increased T-cell populations observed here were not necessarily T cells reactive with a culprit drug. Rather, they might include T cells expanding as a result of cytokine burst induced by genuine drug-reactive T cells. In addition, our patients had high percentages of Tc2 cells. The role of Tc2 cells in the pathogenesis of drug-induced papuloerythroderma remains speculative. It is possible

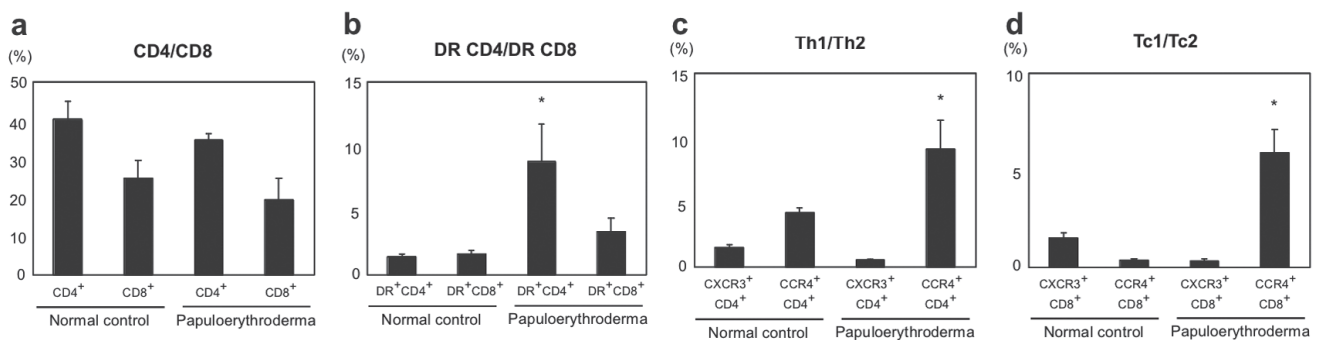


Fig. 3. Percentages of T-cell subsets in patients with drug-induced papuloerythroderma ($n=4$). * $p < 0.05$ compared with normal healthy control ($n=7$).

that they propagated in response to a culprit drug or, alternatively, Tc2 cells might merely proliferate as a result of the Th2 cytokine-dominant environment.

There appear to be some similarities with drug-induced hypersensitivity syndrome (DIHS), also known as drug reaction with eosinophilia and systemic symptoms (DRESS), in the presence of maculopapular rash and leukocytosis with eosinophilia (19, 20). However, drug-induced papuloerythroderma has a different clinical course, i.e. gradual occurrence and chronic course of the eruptions, whereas DIHS/DRESS shows an acute type of eruptions.

In summary, drug-induced papuloerythroderma is a distinct type of drug hypersensitivity mediated by Th2 cells showing peripheral blood and tissue eosinophilia. This type of drug eruption might be overlooked because of its chronic course, and it should be remembered that not only cutaneous T-cell lymphoma and internal malignancies, but also drugs, are causative for papuloerythroderma. Lymphocyte transformation test is a more useful tool than patch test to determine the culprit drug in drug-induced papuloerythroderma. Papuloerythroderma is also known as manifestation of cutaneous T-cell lymphoma (21), which is a Th2 cell malignancy. It appears, therefore, that Th2 cell infiltration is closely associated with the development of papuloerythroderma. Further studies are required to clarify the pathogenic relationship of Th2 cells with the formation of solid papules and sparing of creases.

The authors declare no conflict of interest.

REFERENCES

1. Ofuji S, Furukawa F, Miyachi Y, Ohno S. Papuloerythroderma. *Dermatologica* 1984; 169: 125–130.
2. Wakeel RA, Keefe M, Chapman RS. Papuloerythroderma. Another case of a new disease. *Arch Dermatol* 1991; 127: 96–98.
3. Just M, Carrascosa JM, Ribera M, Bielsa I, Ferrándiz C. Dideoxyinosine-associated Ofuji papuloerythroderma in an HIV-infected patient. *Dermatology* 1997; 195: 410–411.
4. Sugita K, Tokura Y. Drug-induced papuloerythroderma of Ofuji: comment. *J Dermatol* 2008; 35: 377.
5. Sugita K, Koga C, Yoshiki R, Izu K, Tokura Y. Papuloerythroderma caused by aspirin. *Arch Dermatol* 2006; 142: 792–793.
6. Brugnolo F, Annunziato F, Sampognaro S, Campi P, Manfredi M, Matucci A, et al. Highly Th2-skewed cytokine profile of beta-lactam-specific T cells from nonatopic subjects with adverse drug reactions. *J Immunol* 1999; 163: 1053–1059.
7. Nishio D, Izu K, Kabashima K, Tokura Y. T cell populations propagating in the peripheral blood of patients with drug eruptions. *J Dermatol Sci* 2007; 48: 25–33.
8. Pichler WJ. Delayed drug hypersensitivity reactions. *Ann Intern Med* 2003; 139: 683–693.
9. Sugita K, Kabashima K, Nakashima D, Tokura Y. Papuloerythroderma of Ofuji induced by furosemide. *J Am Acad Dermatol* 2008; 58: S54–55.
10. Bech-Thomsen N, Thomsen K. Ofuji's papuloerythroderma: a study of 17 cases. *Clin Exp Dermatol* 1998; 23: 79–83.
11. Holden CA, Berth-Jones J. Eczema, lichenification, prurigo and erythroderma. In: Burns T, Breathnach S, Cox N, Griffiths C, editors. *Rook's text book of dermatology*, 7th edn. Oxford: Blackwell Science Ltd; 2004, 17.1–17.55.
12. Hashizume H, Takigawa M, Tokura Y. Characterization of drug-specific T cells in phenobarbital-induced eruption. *J Immunol* 2002; 168: 5359–5368.
13. Okamoto O, Fujiwara S. Drug eruption caused by ranitidine hydrochloride (Zantac) which showed a strong reaction in a drug-induced lymphocyte stimulation test. *J Dermatol* 2007; 34: 74–79.
14. Sugita K, Kabashima K, Tokura Y. Disseminated maculopapular eruption caused by leuprorelin acetate. *Eur J Dermatol* 2008; 18: 603–604.
15. Imaizumi K, Ogoshi M, Shimizu R. Drug eruption resembling papulo-erythroderma syndrome. *Rinsho Derma* 1995; 37: 251–254.
16. Koga C, Sugita K, Izu K, Tokura Y. Two cases of papuloerythroderma developing as drug eruption. *J Environ Dermatol* 2004; 11 Suppl 1: 72.
17. Kokaji T, Sugiura H, Teraki Y. Isoniazid induced papuloerythroderma-like drug eruption. *Pract Dermatol* 2005; 27: 1189–1192.
18. Sugita K, Kabashima K, Yoshiki R, Koga C, Tokura Y. Papuloerythroderma presenting as drug eruption. *Jpn J Dermatol* 2008; 118: 814.
19. Tohyama M, Yahata Y, Yasukawa M, Inagi R, Urano Y, Yamanishi K, et al. Severe hypersensitivity syndrome due to sulfasalazine associated with reactivation of human herpesvirus 6. *Arch Dermatol* 1998; 134: 1113–1117.
20. Suzuki Y, Inagi R, Aono T, Yamanishi K, Shiohara T. Human herpesvirus 6 infection as a risk factor for the development of severe drug-induced hypersensitivity syndrome. *Arch Dermatol* 1998; 134: 1108–1112.
21. Shah M, Reid WA, Layton AM. Cutaneous T-cell lymphoma presenting as papuloerythroderma – a case and review of the literature. *Clin Exp Dermatol* 1995; 20: 161–163.