

QUIZ SECTION

A Bluish Pigmented Cystic Lesion of the Nose: A Quiz

Nicolas Kluger¹, Jean-Yves Monthieu², Deborah Gil-Bistes¹ and Bernard Guillot¹

¹Service de Dermatologie, Hôpital Saint-Eloi, Université Montpellier I, ²Service d'Anatomie et Cytologie pathologiques, Hôpital Gui-de-Chauliac, CHU de Montpellier, 80, Avenue Augustin Fliche, FR-34295 Montpellier, France. E-mail: nicolaskluger@yahoo.fr

A 63-year-old Caucasian woman presented with a pigmented lesion of the left ala of the nose, which had been present for 6 years. Her medical history included diabetes, hypertension, hypercholesterolaemia, Laugier-Hunziker disease and rosacea. The lesion had not evolved in size, but had tended to darken progressively. There was no familial history of any specific cutaneous disorder. She had not noticed any triggering factors. Examination showed a translucent intense dark-blue pigmented lesion, 2 × 2 mm in diameter (Fig. 1a). The patient had no similar lesions elsewhere. 3 months later the lesion had not changed in size or colour. Dermatoscopy

revealed a bluish nodule surrounded by several telangiectasias. Because the patient showed fear of skin cancer, a 4-mm punch skin biopsy was performed. The biopsy specimen disclosed a normal epidermis. The deep dermis contained a solitary cyst lined with a single or double layer of cuboidal epithelial cells with an eosinophilic cytoplasm. Extravasation of red blood cells was noted within the cystic cavity. No apocrine decapitation secretion or myoepithelial lining outside the cyst was observed (Fig. 1b).

What is your diagnosis? See next page for answer.

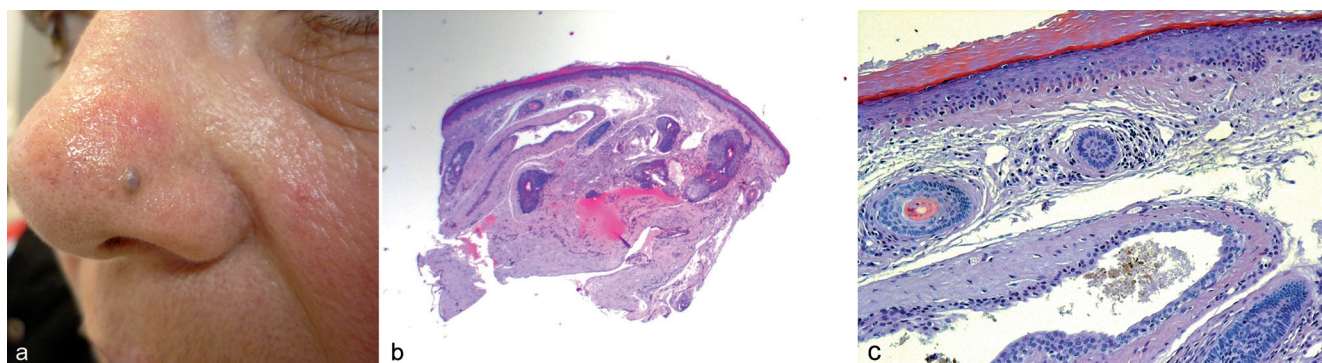


Fig. 1. (a) Clinical presentation. (b) Unilocular cyst of the mid-dermis with no communication with the epidermis (haematoxylin and eosin (H&E) × 2). (c) Close-up view: single cystic cavity composed of 1 or 2 layers of cuboidal cells in the mid-dermis. (H&E × 10). (Charlotte Pernet provided the pictures)

doi: 10.2340/00015555-0843

ANSWERS TO QUIZ

A Bluish Pigmented Cystic Lesion of the Nose: Comment

Acta Derm Venereol 2010; 90: 555–558 (contd).

Diagnosis: Solitary (“Smith and Chernovsky” type) eccrine hidrocystoma

Eccrine hidrocystoma (EH) is a benign cystic tumour of the eccrine duct. It may present in two distinct ways. The “classic” Robinson type, described in the end of the 19th century (1), is characterized by multiple cystic lesions of the face of middle-aged women who work in hot environments. Lesions tend to enlarge and become more symptomatic in the summer or in case of exposure to hot/moist air. However, this type seems to be less frequent nowadays due to the development of cooler working conditions (2, 3). The “Smith and Chernovsky” type, described 80 years later, refers to solitary (usually less than four) facial lesions, affecting both women and men. Lesions do not display any seasonal variation. EH are mostly located on the periorbital areas, but lesions may be found on other areas of the face, head, trunk and popliteal fossa (2). Localization on the nose is rather unusual (3, 4). Individual EH present as asymptomatic, smooth, shiny, flesh-coloured to various shades of blue, dome-shaped papules ranging from 1 to 16 mm in diameter. Rupture of the cyst, resulting in collapse of the lesion with the loss of a watery fluid, helps to confirm the diagnosis (2). Differential diagnoses include apocrine hidrocystoma

(AH) and basal cell carcinoma (2). Distinction from AH is difficult: AH is reported to be larger, darker blue and less likely to be periorbital compared with EH, as in our case (2). The final diagnosis is made by the pathologist: lining epithelium consisting of secretory and myoepithelial cells, S-100 protein negative staining, decapitation of secretory cells, and Periodic acid-Schiff (PAS)-positive granules support a diagnosis of EH (3). Cancerophobia, as in our case, or cosmetic consequences may result in a biopsy or excision of the lesion being carried out (2). Dermatoscopy may be useful in distinguishing EH from basal cell carcinoma (5).

REFERENCES

1. Robinson AR. Hidrocystomas. *J Cut Gen Urin Dis* 1893; 11: 292–303.
2. Smith JD, Chernovsky ME. Hidrocystomas. *Arch Dermatol* 1973; 108: 676–679.
3. Alfadley A, Al Aboud K, Tulba A, Mazen Mourad M. Multiple eccrine hidrocystomas of the face. *Int J Dermatol* 2001; 40: 125–130.
4. Bourke JF, Colloby P, Graham-Brown RAC. Multiple pigmented eccrine hidrocystomas. *J Am Acad Dermatol* 1996; 35: 480–482.
5. Correia O, Duarte AF, Barros AM, Rocha N. Multiple eccrine hidrocystomas – from diagnosis to treatment: the role of dermatoscopy and botulinum toxin. *Dermatology* 2009; 219: 77–79.