

Treatment of Neuropathic Itch Possibly Due to Trigeminal Trophic Syndrome with 0.1% Topical Tacrolimus and Gabapentin

Satoshi Nakamizo, Yoshiki Miyachi and Kenji Kabashima*

Department of Dermatology, Kyoto University Graduate School of Medicine, 54 Shogoin-Kawara, Sakyo, Kyoto, 606-8507, Japan. E-mail: kaba@kuhp.kyoto-u.ac.jp

Accepted May 25, 2010.

Pruritus originating at any point along the afferent pathway is called neuropathic itch (1), which is intractable and, in most instances, accompanied by sensory damage experienced as paraesthesia, hyperaesthesia, or hypoaesthesia. One of the causes of neuropathic itch is trigeminal trophic syndrome (TTS), which results from injury of the trigeminal nerve pathway. TTS results in the classic clinical triad of unilateral trigeminal anaesthesia, facial paraesthesia and lateral nasal ala ulceration (2). Patients with TTS often note a burning, itching, crawling, or tingling sensation and may admit to picking or rubbing the area. We report here a case of TTS-associated neuropathic itch that responded to treatment with gabapentin and topical tacrolimus in combination.

CASE REPORT

A 51-year-old woman had undergone an extended subtotal maxillectomy with reconstruction and a neoadjuvant chemoradiation for maxillary squamous cell carcinoma of the left cheek approximately 7 years previously. Several weeks after the operation, the patient had noticed an irritable pruritic sensation on her left cheek. This symptom became noticeable when the area was touched or when her temperature was elevated. The uncomfortable sensation persisted even when she scratched her left cheek. Treatment with antihistaminergic medications and a topical steroid was initiated, but was unsuccessful; therefore she was referred to our department.

Examination of the patient's left cheek revealed healed scars with erythema and vasodilation (Fig. 1). The affected area was analgesic, so that the patient felt only dull pain when her left cheek was pinched. We diagnosed neuropathic itch possibly associated with TTS due to surgery. After obtaining informed consent, we initiated treatment with 0.1% topical tacrolimus twice a day. Fourteen days after her initial visit, the patient reported that her symptoms had improved significantly, but that she still felt a mild pruritic sensation. In response, we initiated treatment with 200 mg twice a day. Three weeks later, the symptoms were almost completely resolved. However, when we discontinued the tacrolimus treatment, her symptoms relapsed, and therefore the patient has been prescribed the same regimen to date.

DISCUSSION

Treatment for neuropathic itch is similar to that for neuropathic pain. Both conditions, however, are intractable. Previous reports have indicated success with regimens including carbamazepine, gabapentin, or pregabalin (3). Gabapentin and pregabalin elicit pharmacological effects by inhibiting the $\alpha 2\delta$ -subunit of voltage-dependent calcium (Ca^{2+}) channels that suppress Ca^{2+} -dependent plateau potentials and contribute to antineuropathic pain

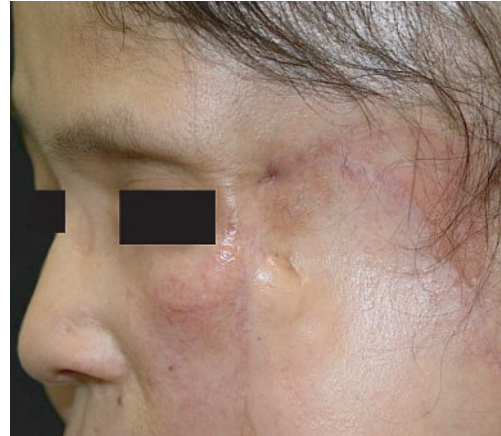


Fig. 1. Clinical picture of the patient showing several ulcers on her cheek.

(4). Neuropathic itch may also be treated by means of topical therapy: capsaicin, for example. Capsaicin or heat greater than 43°C degenerates or desensitizes sensory neurones expressing transient receptor potential vanilloid 1 (TRPV1) and relieves neuropathic pain as well as itch (5, 6). Clinically, tacrolimus and capsaicin have similar effects, with an initial irritation effect followed by a soothing effect. Tacrolimus increases intracellular Ca^{2+} concentrations of TRPV1-sensitive sensory neurones and enhances discharges of heat-sensitive cutaneous C-fibres *in vitro* (7). Tacrolimus does not act as a ligand of TRPV1 like capsaicin, but directly phosphorylates TRPV1 (8). Therefore, counterstimulus action and/or desensitization of itch-signalling fibres may be involved in the acute anti-pruritic action of tacrolimus.

In the case described here, treatment with gabapentin and topical tacrolimus in combination successfully relieved neuropathic itch possibly from TTS. It is known that tacrolimus has a capsaicin-like effect, and that treatment regimens for neuropathic itch have included anticonvulsants, antidepressants, and capsaicin. Although our evidence is limited to a single case, the combination of gabapentin and topical tacrolimus induced a sufficiently successful outcome in controlling neuropathic itch.

REFERENCES

- Bernhard JD. Itch, mechanisms and management of pruritus. New York: McGraw-Hill; 1994: p. 185–202.
- Rashid RM, Khachemoune A. Trigeminal trophic syndrome. *J Eur Acad Dermatol Venereol* 2007; 21: 725–731.
- Summey BT Jr., Yosipovitch G. Pharmacologic advances in the systemic treatment of itch. *Dermatol Ther* 2005; 18:

- 328–332.
4. Rogawski MA, Loscher W. The neurobiology of antiepileptic drugs for the treatment of nonepileptic conditions. *Nat Med* 2004; 10: 685–692.
 5. Caterina MJ, Leffler A, Malmberg AB, Martin WJ, Trafton J, Petersen-Zeitz KR, et al. Impaired nociception and pain sensation in mice lacking the capsaicin receptor. *Science* 2000; 288: 306–313.
 6. Holzer P. Capsaicin: cellular targets, mechanisms of action, and selectivity for thin sensory neurons. *Pharmacol Rev* 1991; 43: 143–201.
 7. Senba E, Katanosaka K, Yajima H, Mizumura K. The immunosuppressant FK506 activates capsaicin- and bradykinin-sensitive DRG neurons and cutaneous C-fibers. *Neurosci Res* 2004; 50: 257–262.
 8. Pereira U, Boulais N, Lebonvallet N, Pennec JP, Dorange G, Misery L. Mechanisms of sensory effects of tacrolimus on the skin. *Br J Dermatol* 2010; 163: 70–77.