

SHORT COMMUNICATION

In transit Recurrence of Merkel Cell Carcinoma Associated with Polyarthritis Effectively Treated with ImmunocryosurgeryParaskevi V. Voulgari^{1#}, Georgios Gaitanis^{2#}, Theodora E. Markatseli¹, Werner Kempf³ and Ioannis D. Bassukas²¹Rheumatology Clinic, Department of Internal Medicine, ²Department of Skin and Venereal Diseases, Medical School, University of Ioannina, Ioannina, Greece, and ³Kempf and Pfaltz, Histological Diagnostics, Zürich, Switzerland. E-mail: ibassuka@cc.uoi.gr

Accepted Jan 21, 2014; Epub ahead of print Apr 22, 2014

[#]These authors contributed equally to this paper and should be considered as first authors.

Merkel cell carcinoma (MCC) is a rare malignant neuro-endocrine tumour of the skin (incidence: 0.2–0.45/10⁵) that is more common in elderly, immunocompromised and HIV-infected individuals (1), with an overall 5-year survival rate: 30–60% (2). History of autoimmune conditions such as rheumatoid or psoriatic arthritis has been connected to a slightly increased MCC risk (3). A recent breakthrough was the identification of a novel polyomavirus (MCPyV) in association with MCC pathogenesis (4). Various combination schemes of conventional anti-neoplastic therapeutic modalities (surgery, radiotherapy and chemotherapy) are currently under evaluation for the treatment of metastatic MCC (2). Immunocryosurgery, i.e. liquid N₂ cryosurgery sessions during continuing daily topical imiquimod application, has been introduced in our hospital for the treatment of basal cell carcinoma (5), lentigo maligna (6) and Bowen's disease (7).

Herein, we report on the successful treatment with immunocryosurgery of a patient with a loco-regional *in transit* MCC recurrence that was heralded by the development of a paraneoplastic polyarthritis syndrome.

CASE REPORT

An 84-year-old woman presented with a 2-week history of multiple ($n=11$) cutaneous-subcutaneous nodules on her left tibia (Fig. 1a) and pain associated with local swelling of the right hip, right knee and both heels that precluded any movement (Karnofsky score: 30). The patient was treated during the preceding week with 16 mg methylprednisolone/day. Six months prior, a MCC, 2.5 cm in diameter, was removed from the left calf (T2cN0M0; Stage IIB) and 2 months prior she was hospitalised with a 3-day history of generalised symmetrical polyarthritis. No recurrence of MCC was evident at that time; the symptoms were attributed to the exacerbation of a known psoriatic arthritis. The patient was treated with tapered 16 mg methylprednisolone/day with prompt improvement.

During present hospitalisation laboratory evaluation was within normal limits except for increased erythrocyte sedimentation rate (94 mm/h), C-reactive protein (289 mg/l), a very low titre of rheumatoid factor (1/20, latex fixation test) and a low titre of antinuclear antibodies (1/160, indirect immunofluorescence); antibodies to extractable nuclear antigens and to double-stranded DNA, C3 and C4 complement levels and anti-cyclic citrullinated antibodies were within normal limits. Synovial fluid aspirate from the right knee supported the diagnosis inflammatory arthritis (30,000 leucocytes/mm³ with 90% neutrophils; no malignant cells; no crystals; negative cultures).

Biopsy of a nodule confirmed the recurrence of MCC. By immunohistochemistry (8) almost all tumour cells were positive

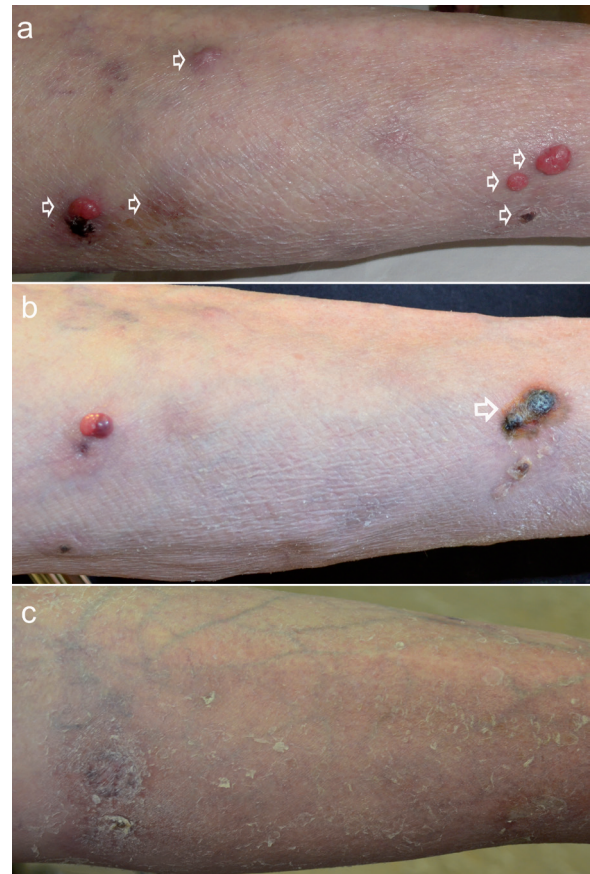


Fig. 1. Treatment of *in transit* recurrence of Merkel cell carcinoma with immunocryosurgery. A: Detail of recurrence basin (left tibia) at baseline, showing 6 clinically evident metastases (arrows). B: At the end of the immunocryosurgery treatment cycle (1 week after stopping imiquimod application; 4 weeks after a single session of cryosurgery) of the 2 lesions to the right (arrow). C: Outcome 6 months after the end of the last treatment cycle. Complete regression of tumours is evident.

for the large T-antigen of the MCPyV (antibody CM2B4, Santa Cruz Biotechnology Inc., sc-136172; Fig. S1e¹). Chest X-ray, abdomen ultrasound and CT scans of chest and abdomen did not show any lymph node or organ metastases. The constellation of physical, laboratory and radiologic findings set the diagnosis of *in transit* recurrence of MCC (T2N2M0; stage IIIB (2)) heralded by arthritis of putatively paraneoplastic origin.

Because of the markedly reduced general state of the patient all conventional treatment options (surgery, radiotherapy, chemotherapy) were postponed. Faced with a rapidly progressing tumour

¹<http://www.medicaljournals.se/acta/content/?doi=10.2340/00015555-1812>

we decided for palliative immunocryosurgery. As methylprednisolone was tapered within 2 weeks to 4 mg/day, standard immunocryosurgery (5–7) was initiated with imiquimod once daily and two-weekly cryosurgery sessions (2×15 s active freezing/tumour) in 3–5 lesions each time. Already 4 weeks after the first cryosurgery session substantial remission of treated metastases was evident (Fig. 1b). Imiquimod was continued on each cryosurgery treated site for an additional 3 weeks and therapy was initiated on newly emerging metastases. A total of 16 lesions were treated in a period of 3 months. Except for local redness, irritation and oozing (5–7) no other local or systemic adverse effects were observed during treatment. Healing was excellent and no new lesions emerged during 9 months post-treatment (Fig 1c). Only the anticipated protracted healing of cryosurgery sites in the lower third of the tibia was evident. In parallel joint complaints subsided completely and the patient regained adequate mobility without analgesics or corticosteroids (Karnofsky score: 50).

DISCUSSION

We describe the effective immunocryosurgery treatment of an *in transit* MCC recurrence associated with polyarthritis. Arthritis is common in patients with malignancies and may have diverse aetiologies (septic, crystal-induced, drug-induced, metastatic or paraneoplastic) (9). Paraneoplastic polyarthritis associated with solid tumours and haematological malignancies usually (88.5%) appears prior (mean latency: 3.6 months) to the diagnosis of the tumour (10). Possible mechanisms of paraneoplastic polyarthritis include an immune complex-mediated synovitis, cross-reactivity of antigenic determinants on the synovium and neoplastic tissue and abnormalities of cell-mediated immunity (11). The polyarthritis of this patient, which emerged 2 months before tumour relapse and subsided in parallel to tumour control, may represent the first description of paraneoplastic arthritis in association with MCC recurrence.

Regarding the assessment of the therapeutic efficacy of immunocryosurgery in MCC, topical imiquimod has been evaluated in a single case of MCC in combination with radiotherapy (12) and complete remission for 7 years of a primary T2 MCC was described with cryosurgery (13). Before the observed therapeutic outcome can be ascribed to immunocryosurgery one should consider the possibility of spontaneous regression. MCC is characterised by a marked potential for spontaneous regression, sometimes seemingly induced by 'traumatic' tumour manipulations (14). However spontaneous regression is rather unlikely in our case, as only treated lesions regressed each time and new ones appeared in the interim. Immunocryosurgery was designed to induce antitumour immunity (5, 6) and tumour infiltration by CD8⁺ cells is observed during clearance of basal cell carcinoma treated with this modality (unpublished data). Likewise, MCC is a strongly immunogenic tumour *per se* with cases of spontaneous regression being associated with intratumoural efflux of CD8⁺ effector cells (15).

Our current observation of immunocryosurgery induced remission in this patient with stage IIIB MCC is

an encouraging outcome to be explored in future cases. The cessation of arthritis following tumour remission not only supports its paraneoplastic nature in this case, but might also be a sign of adequate tumour control.

ACKNOWLEDGEMENT

The authors are indebted to Professors M. Hundeiker and M. Tronnier for valuable suggestions during the preparation of this paper.

REFERENCES

1. The Rockville Merkel Cell Carcinoma Group. Merkel cell carcinoma: recent progress and current priorities on etiology, pathogenesis, and clinical management. *J Clin Oncol* 2009; 27: 4021–4026.
2. Clinical Practice in Oncology (NCCN Guidelines™). Merkel Cell Carcinoma, Version 1.2012. Available from: http://www.nccn.org/professionals/physician_gls/pdf/mcc.pdf.
3. Lanoy E, Engels EA. Skin cancers associated with autoimmune conditions among elderly adults. *Br J Cancer* 2010; 29: 112–114.
4. Rodig SJ, Cheng J, Wardzala J, DoRosario A, Scanlon JJ, Laga AC, Martinez-Fernandez A, et al. Improved detection suggests all Merkel cell carcinomas harbor Merkel polyomavirus. *Clin Invest* 2012; 122: 4645–4653.
5. Gaitanis G, Bassukas ID. Immunocryosurgery for non-superficial basal cell carcinoma: A prospective, open-label phase III study for tumours ≤2 cm in diameter. *Acta Derm Venereol* 2014; 94: 38–44.
6. Bassukas ID, Gamvroulia C, Zioga A, Nomikos K, Fotika C. Cryosurgery during topical imiquimod: A successful combination modality for lentigo maligna. *Int J Dermatol* 2008; 47: 519–521.
7. Gaitanis G, Mitsou G, Tsiouri G, Alexis I, Bassukas ID. Cryosurgery during imiquimod cream treatment ("immunocryosurgery") for Bowen's disease of the skin: a case series. *Acta Derm Venereol* 2010; 90: 533–534.
8. Mertz KD, Pfaltz M, Junt T, Schmid M, Fernandez Figueras MT, Pfaltz K, et al. Merkel cell polyomavirus is present in common warts and carcinoma in situ of the skin. *Hum Pathol* 2010; 41: 1369–1379.
9. Marengo MF, Suarez-Almazor ME, Lu H. Neoplastic and paraneoplastic synovitis. *Rheum Dis Clin North Am* 2011; 37: 551–572.
10. Morel J, Deschamps V, Toussiroit E, Pertuiset E, Sordet C, Kieffer P. Characteristics and survival of 26 patients with paraneoplastic arthritis. *Ann Rheum Dis* 2008; 67: 244–247.
11. Azar L, Khasnis A. Paraneoplastic rheumatologic syndromes. *Curr Opin Rheumatol* 2013; 25: 44–49.
12. Balducci M, De Bari B, Manfrida S, D'Agostino GR, Valentini V. Treatment of Merkel cell carcinoma with radiotherapy and imiquimod (Aldara): a case report. *Tumori* 2010; 96: 508–511.
13. Nagy J, Fehér L, Sonkodi I, Lesznyák J, Iványi B, Puskás LG. A second field metachronous Merkel cell carcinoma of the lip and the palatine tonsil confined by microarray-based comparative genomic hybridization. *Virchows Arch* 2005; 446: 278–286.
14. Richetta AG, Mancini M, Torroni A, Lorè B, Iannetti G, Sardella B, Calvieri S. Total spontaneous regression of advanced Merkel cell carcinoma after biopsy review and a new case. *Dermatol Surg* 2008; 34: 815–822.
15. Sihto H, Joensuu H. Tumor-infiltrating lymphocytes and outcome in Merkel cell carcinoma, a virus-associated cancer. *Oncoimmunology* 2012; 1: 1420–1421.