

SHORT COMMUNICATION

Characterization of Two Cases of Bullous Pemphigoid Reactive Only with BP230 on Japanese Enzyme-linked Immunosorbent Assays

Shu Sasai¹, Ryuhei Nishikawa², Ayaka Ohzono², Taihei Hayakawa², Daisuke Tsuruta^{2,3}, Kazuhiro Kudoh⁴, Tsuyoshi Kikuchi⁵, Masahiro Hashiguchi⁶, Chika Ohata², Minao Furumura², Hiroshi Koga², Norito Ishii and Takashi Hashimoto^{2*}

¹Division of Dermatology, South Miyagi Medical Center, Miyagi, ²Department of Dermatology, Kurume University School of Medicine, and Kurume University Institute of Cutaneous Cell Biology, 67 Asahimachi, Kurume, Fukuoka 830-0011, ³Present address: Department of Dermatology, Osaka City University Graduate School of Medicine, Osaka, ⁴Division of Dermatology, Kesenuma City Hospital, Miyagi, ⁵Cosmic Corporation Co. Ltd, Business Development and Marketing Department, and ⁶Medical & Biological Laboratories Co. Ltd, Marketing & Technical Support Department, Tokyo, Japan. E-mail: hashimoto@med.kurume-u.ac.jp

Accepted Mar 12, 2014; Epub ahead of print Mar 25, 2014

Bullous pemphigoid (BP) is characterized clinically by oedematous erythemas and tense, histopathologically subepidermal blisters with eosinophilic infiltration, and immunologically by immunoglobulin G (IgG) autoantibodies to BP230 and BP180 (1, 2). BP230 mediates the interaction between intermediate filaments and BP180 (3). Since BP230 has a cytoplasmic localization, and IgG antibodies cannot access this in intact cells, the production of IgG autoantibodies to BP230 is thought to be a secondary event. In contrast, as BP180 is a transmembrane protein, IgG autoantibodies to BP180 are considered pathogenic (1).

The aim of this study was to characterize 2 BP patients, whose sera originally reacted only with BP230.

CASE REPORTS

Patient 1. An 82-year-old Japanese woman developed diffuse erythemas and multiple tense blisters over her whole body (Fig. 1a). Indirect immunofluorescence (IF) showed circulating IgG autoantibodies reactive with the epidermal side of 1M NaCl-split skin (Fig. 1b). Skin biopsy was not performed. A clinical diagnosis of generalized BP was made. A combination of topical corticosteroid and oral doxycycline and epinastine hydrochloride resulted in complete remission.

Patient 2. An 84-year-old Japanese woman presented with oedematous erythemas and tense blisters exclusively on the dorsal side of her feet, which had been present for 1 month (Fig. S1c¹). IgG antibodies reacted with the epidermal side of 1M NaCl-split skin (Fig. S1d¹). A clinical diagnosis of localized BP was made. However, patient 2 was lost to follow-up. Skin biopsy was not performed.

Both patients were negative for BP180, but positive for BP230 on IgG ELISA kits for BP230 and BP180 produced in Japan (Mesacup, Medical & Biological Laboratories (MBL), Nagoya, Japan) (4, 5), (Table S1¹). To verify this result, the sera was also examined with different IgG ELISA kits produced in Germany (Euroimmun Co. Ltd, Luebeck, Germany) (6, 7). Using these ELISA kits, patient 1 was positive for both BP180 and BP230, whereas patient 2 was negative for both antigens (Table S1¹).

The BP230 ELISA kit produced by MBL uses full-length bacterial recombinant proteins (RPs) of both N- and C-terminal domains of BP230, while the ELISA kit produced by Euroimmun uses bacterial RP of partial C-terminal domain of BP230. Therefore, to study the reactivity with BP230 in more detail, we performed novel BP230-domain-specific ELISAs (Hayakawa et al., manuscript in preparation) (Table S1¹). Bacterial RPs of N- and C-terminal domains of BP230 were prepared, as described previously (8). In these ELISAs, patient 1 was negative for the N-terminal domain, but strongly positive for the C-terminal domain, of BP230 (Table S1¹). Patient 2 was strongly positive for the N-terminal domain and intermediately positive for the C-terminal domain.

The presence of IgE antibodies was further examined by novel techniques (Ohzono et al., manuscript in preparation) (Table S1¹), utilizing commercially available BP180 and BP230 ELISA kits for IgE antibodies (MBL). Two additional BP patients (patients 3 and 4) and 2 healthy individuals were used as controls. This study showed that, while IgE anti-BP180 antibodies were negative in both patients 1 and 2, IgE anti-BP230 antibodies were slightly positive in patient 1 and strongly positive in patient 2.

Immunoblotting of normal human epidermal extract showed positive IgG reactivity with the 230 kDa BP230 in patient 2, but not in patient 1 (Fig. S1e¹). In immunoblotting analyses of RPs of monomeric NC16a domain and C-terminal domain of BP180, both patients did not react with either RP (Fig. S1f and g¹). IgG antibodies in both patients did not show any positive results in immunoblotting analyses using normal human dermal extract, or concentrated HaCaT cell culture supernatant and purified human laminin-332.

¹<http://www.medicaljournals.se/acta/content/?doi=10.2340/00015555-1848>

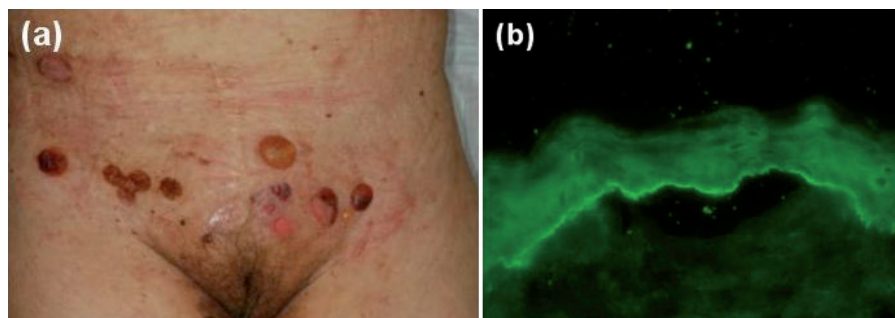


Fig. 1. (a) Clinical features on the abdomen of patient 1. (b) Indirect immunofluorescence (IF) using 1M NaCl-split skin in patient 1 ($\times 100$) (For complete figure see Fig. S1¹).

DISCUSSION

The 2 patients with BP showed distinct results between 2 different commercially available ELISA kits for both BP230 and BP180.

Taking into account the difference in RPs used in the N- and C-terminal BP230 ELISA and C-terminal BP230 ELISA, one can explain the discrepant results that patient 2 was negative in the C-terminal BP230 ELISA, but positive in the N- and C-terminal BP230 ELISA, while patient 1 was positive on both ELISAs. Namely, patient 1 may have high antibodies to the partial C-terminal domain RP of BP230 used in the C-terminal BP230 ELISA, resulting in high relative units in the C-terminal BP230 ELISA. In contrast, patient 2 may have high antibodies to the N-terminal domain of BP230, but low antibodies to the C-terminal domain RP used in the C-terminal BP230 ELISA, resulting in a high index in the N- and C-terminal BP230 ELISA and negative relative units in the C-terminal BP230 ELISA.

Concerning BP180 ELISA kits, MBL ELISA uses monomeric NC16a RP of only one NC16a domain, while Euroimmun ELISA uses tetrameric NC16a RP of 4 tandem repeats of NC16a domain, indicating higher sensitivity in tetrameric NC16a ELISA. This explains well the discrepant result that patient 1 was negative in monomeric NC16a ELISA, but weakly positive in tetrameric NC16a ELISA.

As a mechanism of subepidermal blister formation in BP, binding of anti-BP180 antibodies to BP180 is considered to cause inflammation, internalization of BP180 and signalling events, resulting in dermo-epidermal separation (1, 9, 10). In contrast, circulating IgG anti-BP230 antibodies are thought to be secondary antibodies.

In the present study, patient 2 showed autoantibodies to BP230, but not to BP180, in 2 different ELISAs. Negative reactivity with BP180 was also supported by the results in immunoblotting using epidermal extract, concentrated culture supernatant of HaCaT cells and 2 BP180 RPs. These results tempted us to speculate that anti-BP230 antibodies, at least in patient 2, were pathogenic. Thus far, 3 BP cases with generalized skin lesions, similar to case 1 in this study, were reported to show only anti-BP230 antibodies (11). In addition, several cases of localized BP or pemphigoid nodularis, similar to case 2 in this study, were reported to react only with BP230 (12, 13).

A pathogenic role of anti-BP230 autoantibodies was also suspected in patient 1 when reactivity was first found only with BP230 in the study using the C-terminal BP230 ELISA and monomeric NC16a ELISA. However, the tetrameric NC16a ELISA, with higher sensitivity to BP180, detected relatively low reactivity with BP180 in patient 1. Thus, IgG anti-BP180 autoantibodies may cause the extensive skin lesions in patient 1.

The results of this study indicate that simultaneous use of 2 different ELISA kits may be helpful in making diagnoses and understanding the pathophysiology in

individual patients with BP. Further extensive comparative studies between the 2 commercially available ELISA kits for both BP180 and BP230 are in progress.

Pathogenic IgE antibodies to BP antigens were reported to be present in BP sera (14, 15). Therefore, we also performed a preliminary study for IgE antibodies to BP180 and BP230 using a novel technique that detected weak and strong IgE reactivity with BP230 in patients 1 and 2, respectively, while both patients showed negative IgE reactivity with BP180. Interestingly, this reactivity profile for IgE antibodies was similar to that for IgG antibodies. The high IgE antibodies to BP230 may play a role in blister formation in patient 2. However, while patient 1 showed extensive skin lesions, patient 2 showed minimum skin lesions restricted to the dorsal side of the feet, indicating a relatively low pathogenic activity of IgE anti-BP230 autoantibodies. A more extensive study of IgE antibodies to BP180 and BP230 in patients with BP, which may elucidate the pathogenic role of IgE antibodies in BP, is in progress in our institute.

REFERENCES

1. Ujiie H, Shibaki A, Nishie W, Shimizu H. What's new in bullous pemphigoid. *J Dermatol* 2010; 37: 194–204.
2. Tsuruta D, Hashimoto T, Hamill KJ, Jones JC. Hemidesmosomes and focal contact proteins: functions and cross-talk in keratinocytes, bullous diseases and wound healing. *J Dermatol Sci* 2011; 62: 1–7.
3. Fontao L, Favre B, Riou S, Geerts D, Jaunin F, Saurat JH, et al. Interaction of the bullous pemphigoid antigen 1 (BP230) and desmoplakin with intermediate filaments is mediated by distinct sequences within their COOH terminus. *Mol Biol Cell* 2003; 14: 1978–1992.
4. Kobayashi M, Amagai M, Kuroda-Kinoshita K, Hashimoto T, Shirakata Y, Hashimoto K, Nishikawa T. BP180 ELISA using bacterial recombinant NC16a protein as a diagnostic and monitoring tool for bullous pemphigoid. *J Dermatol Sci* 2002; 30: 224–232.
5. Yoshida M, Hamada T, Amagai M, Hashimoto K, Uehara R, Yamaguchi K, et al. Enzyme-linked immunosorbent assay using bacterial recombinant proteins of human BP230 as a diagnostic tool for bullous pemphigoid. *J Dermatol Sci* 2006; 41: 21–30.
6. Blöcker IM, Dähnrich C, Probst C, Komorowski L, Saschenbrecker S, Schlumberger W, et al. Epitope mapping of BP230 leading to a novel enzyme-linked immunosorbent assay for autoantibodies in bullous pemphigoid. *Br J Dermatol* 2012; 166: 964–970.
7. Sitaru C, Dähnrich C, Probst C, Komorowski L, Blöcker I, Schmidt E, et al. Enzyme-linked immunosorbent assay using multimers of the 16th non-collagenous domain of the BP180 antigen for sensitive and specific detection of pemphigoid autoantibodies. *Exp Dermatol* 2007; 16: 770–777.
8. Hamada T, Nagata Y, Tomita M, Salmhofer W, Hashimoto T. Bullous pemphigoid sera react specifically with various domains of BP230, most frequently with C-terminal domain, by immunoblot analyses using bacterial recombinant proteins covering the entire molecule. *Exp Dermatol* 2001; 10: 256–263.
9. Iwata H, Kamio N, Aoyama Y, Yamamoto Y, Hirako Y, Owaribe K, et al. IgG from patients with bullous pemphigoid depletes cultured keratinocytes of the 180-kDa bullous

- pemphigoid antigen (type XVII collagen) and weakens cell attachment. *J Invest Dermatol* 2009; 129: 919–926.
10. Kitajima Y, Hirako Y, Owaribe K, Mori S, Yaoita H. Antibody-binding to the 180-kD bullous pemphigoid antigens at the lateral cell surface causes their internalization and inhibits their assembly at the basal cell surface in cultured keratinocytes. *J Dermatol* 1994; 21: 838–846.
 11. Ohtsuki Y, Yamanaka A, Ohyama H, Yamada E, Terada N, Fujita J, et al. Histochemical demonstration of aluminum and iron deposition in pulmonary bony tissues in three cases of diffuse pulmonary ossification. *Histol Histopathol* 2008; 23: 137–141.
 12. Kawahara Y, Matsumura K, Hashimoto T, Nishikawa T. Immunoblot analysis of autoantigens in localized pemphigoid and pemphigoid nodularis. *Acta Derm Venereol* 1997; 77: 187–190.
 13. Powell AM, Albert S, Gratian MJ, Bittencourt R, Bhogal BS, Black MM. Pemphigoid nodularis (non-bullous): a clinicopathological study of five cases. *Br J Dermatol* 2002; 147: 343–349.
 14. Fairley JA, Burnett CT, Fu CL, Larson DL, Fleming MG, Giudice GJ. A pathogenic role for IgE in autoimmunity: bullous pemphigoid IgE reproduces the early phase of lesion development in human skin grafted to nu/nu mice. *J Invest Dermatol* 2007; 127: 2605–2611.
 15. Messingham KN, Srikantha R, DeGueme AM, Fairley JA. FcR-independent effects of IgE and IgG autoantibodies in bullous pemphigoid. *J Immunol* 2011; 187: 553–560.