

## Induced Vitiligo due to Talimogene Laherparepvec Injection for Metastatic Melanoma Associated with Long-term Complete Response

Pablo IGLESIAS<sup>1#</sup>, Simone RIBERO<sup>1,2#</sup>, Alicia BARREIRO<sup>1</sup>, Sebastian PODLIPNIK<sup>1</sup>, Cristina CARRERA<sup>1</sup>, Josep MALVEHY<sup>1,3</sup> and Susana PUIG<sup>1,3</sup>

<sup>1</sup>Dermatology Department, Hospital Clinic Barcelona, University of Barcelona, Villarroel 170, ES-08036 Barcelona, Spain, <sup>2</sup>Medical Sciences Department, Section of Dermatology, University of Turin, Turin, Italy and <sup>3</sup>Centro de Investigación Biomédica en Red en Enfermedades Raras (CIBERER), Barcelona, Spain. E-mail: susipuig@gmail.com #Both authors contributed equally to this paper.

Accepted Oct 3, 2018; Epub ahead of print Oct 3, 2018

Talimogene laherparepvec (T-VEC) (Imlygic, Amgen) is the first oncolytic virus approved for use in therapy for metastatic melanoma. T-VEC provides a treatment option for patients with limited metastatic disease. T-VEC is a genetically modified, live, attenuated herpes simplex virus type 1 designed to replicate in tumour cells and promote an enhanced anti-tumour response (1) T-VEC is administered by injection into cutaneous, subcutaneous or nodal lesions, which are visible and/or palpable and/or visualized by ultrasonography (2).

Other local management options have been used to control metastatic disease in stage IIIB, but almost all have shown only a local effect and rapid disease relapse (3, 4).

With T-VEC, responses occurred in injected and uninjected lesions, including a greater than 50% decrease in size in 15% of uninjected visceral lesions.

The appearance of vitiligo has been described as an adverse event after administration of immune checkpoint inhibitors (5, 6). It has been reported as a marker of activity of the drug and long-term results, inducing clinicians to use it as a predictor of drug response (7). A T-VEC phase II study has reported 85% adverse events, all of which were grade 1 or 2. The appearance of vitiligo has been described in 3 patients out of 50 (8), although no details regarding duration and appearance have been reported.

### CASE REPORTS

We describe here the appearance of a vitiligo phenomenon in the context of T-VEC therapy. Both patients were enrolled in a clinical trial after progression (Amgen 20120325, Eudra 2013-005552-15). This trial consists of the injection of T-VEC in subcutaneous nodules of melanoma. We performed the injection under ultrasonography. The patients had no active autoimmune disease or any history of such disease in the clinical records (those would be exclusion criteria for enrolment in the trial).

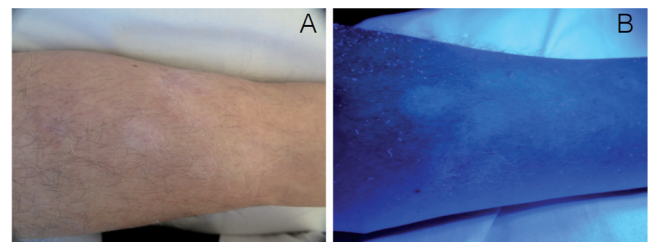
**Patient 1.** The first patient was a 47-year-old man who had had a nodular ulcerated 3.2-mm melanoma, *BRAF* mutated, excised 3 years previously. The sentinel lymph node had a metastatic deposit of 2 mm maximum tumour diameter and the 9 lymph nodes excised at the complete lymph node dissection (CLND) were negative. Six months after surgery he noticed the appearance of a nodule close to the wide local excision scar (1 year after diagnosis of the primary tumour) followed by other 5 lesions on the same leg, which were confirmed to be cutaneous metastases. Radiological evaluation confirmed the absence of any other tumour deposit and he was enrolled in the trial 20120325, a total volume of 3.5 ml T-VEC at 108 PFU/ml was administered in 4 lesions.

A total of 14 administrations every 3 weeks were needed to completely shrink the metastases and to achieve a complete response. He developed a flu-like reaction after each administration. Two months after the last drug administration, hypochromic maculae appeared in some of the treated lesions on his leg (**Fig 1**). The patient remains in complete remission at 20 months. The size of the vitiligo has been stable since its first appearance (Fig. 1B)

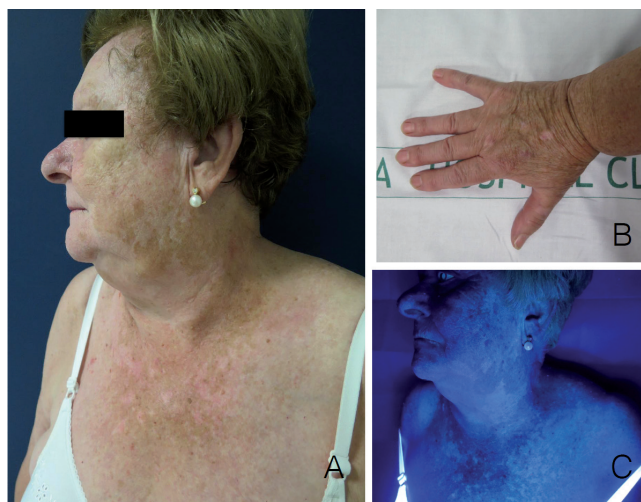**Patient 2.** The second patient was a woman of 80 years, who had a *BRAF* wild-type melanoma, 1.87-mm Breslow thickness, excised from her right leg. Sentinel lymph node (SLN) biopsy was not carried out. Two and a half years after the first diagnosis she developed a lymph node metastasis in the groin and a metastasis on the skin graft of the wide excision. She was submitted to isolated limb perfusion with melphalan and tumour necrosis factor (TNF)- $\alpha$  with a complete response. This was maintained for 14 months, when a new lesion (histologically confirmed) appeared on the same leg and she was treated with 26 cycles of T-VEC every 3 weeks, starting with an initial dose of 3 ml with a complete response. She developed a flu-like reaction after every administration. Two months after the last administration, some hypochromic areas appeared on her face, neckline and dorsum of her hands (**Fig. 2**). Seen under a Wood's lamp, they were well delimited and hypopigmented, suggestive of a vitiligo phenomenon. She remains in complete remission at 16 months. The vitiligo has been stable in size since its first appearance.

### DISCUSSION

T-VEC was US Food and Drug Administration (FDA) approved for recurrent unresectable cutaneous and subcutaneous melanoma in October 2015. In a recent phase IIIB study, adverse events occurred in 93% of patients, with the most common being fatigue, chills, and pyrexia; grade  $\geq 3$  adverse events occurred in 24% of the T-VEC-treated group (9).



**Fig. 1. Case 1.** (A) Well-defined hypochromic lesions with non-pigmented hairs on the pretibial area. Those lesions appeared at the sites of the previous melanoma metastases. (B) At 20 months from the complete response the vitiligo plaques were still visible and stable in size, as seen under Wood's lamp.



**Fig. 2. Case 2.** (A) Induced vitiligo after 2 months from the achievement of a complete response of melanoma metastases with T-VEC treatment. (B) Induced vitiligo on the dorsum of the hand. (C) Distribution of the induced vitiligo on the neck/chest and on the typical localization around the mouth, as seen under Wood's lamp.

We have described here the appearance of an immunological reaction after successful treatment with T-VEC. Interestingly, the vitiligo appeared both at the injection sites and at distance, thus reflecting the activity of the oncolytic virus, not only on the local immune cells, but also inducing an immune reaction against melanocytes at a distance. Usually those phenomena are more common with systemic drugs, when a systemic immune reaction has been observed (10). The fact that a local treatment could potentially induce a distant reaction should be considered as a systemic effect of the injected drugs.

Autoimmune phenomena have been described in untreated melanoma patients (11), but are more frequently observed in patients receiving immune checkpoint inhibitors, (5, 6, 12), being related to response to therapy and to a better outcome (7). In the cases described, the vitiligo was stable at the end of follow-up and the patients were both disease free at 16 and 20 months from the achievement of complete response. Long-term responses associated with vitiligo have been reported in mouse models and human melanoma patients (13–15).

Currently, T-VEC combined with other immune checkpoint inhibitors is under study in several countries; it is also being evaluated as neoadjuvant therapy for melanoma. These drugs can induce a wide spectrum of adverse effects, especially in the skin, so knowing those related to T-VEC is a matter of importance in melanoma practice. Moreover, both patients who developed vitiligo are in complete response after T-VEC treatment.

## ACKNOWLEDGEMENTS

The research at the Melanoma Unit in Barcelona is partially funded by Spanish Fondo de Investigaciones Sanitarias grants 12/00840,

PI15/00956 and 15/00716; CIBER de Enfermedades Raras of the Instituto de Salud Carlos III, Spain, co-financed by European Development Regional Fund “A way to achieve Europe” ERDF; AGAUR 2014\_SGR\_603 of the Catalan Government, Spain; by the European Commission under the 7<sup>th</sup> Framework Programme, Diagnostics; and a grant from “Fundació La Marató de TV3, 201331-30”, Catalonia, Spain and a Research Grant from Asociación Española Contra el Cáncer.

## REFERENCES

- Hu JC, Coffin RS, Davis CJ, Graham NJ, Groves N, Guest PJ, et al. A phase I study of OncoVEXGM-CSF, a second-generation oncolytic herpes simplex virus expressing granulocyte macrophage colony-stimulating factor. *Clin Cancer Res* 2006; 12: 6737–6747.
- Andtbacka RH, Kaufman HL, Collichio F, Milhem M, Collichio F, Delman KA, et al. Talimogene laherparepvec improves durable response rate in patients with advanced melanoma. *J Clin Oncol* 2015; 33: 2780–2788.
- Testori A, Ribero S, Bataille V. Diagnosis and treatment of in-transit melanoma metastases. *Eur J Surg Oncol* 2017; 43: 544–560.
- Fava P, Astrua C, Sanlorenzo M, Ribero S, Brizio M, Filippi AR, et al. Treatment of metastatic melanoma: a multi-disciplinary approach. *G Ital Dermatol Venereol* 2017; 152: 241–261.
- Sibaud V, Meyer N, Lamant L, Vigarios E, Mazieres J, Delord JP. Dermatologic complications of anti-PD-1/PD-L1 immune checkpoint antibodies. *Curr Opin Oncol* 2016; 28: 254–263.
- Lacouture ME, Wolchok JD, Yosipovitch G, Kähler KC, Busam KJ, Hauschild A. Ipilimumab in patients with cancer and the management of dermatologic adverse events. *J Am Acad Dermatol* 2014; 71: 161–169.
- Hodi FS, O'Day SJ, McDermott DF, Weber RW, Sosman JA, Haanen JB, et al. Improved survival with ipilimumab in patients with metastatic melanoma. *N Engl J Med* 2010; 363: 711–723.
- Senzer NN, Kaufman HL, Amatruda T, Nemunaitis M, Reid T, Daniels G, et al. Phase II clinical trial of a granulocyte-macrophage colony-stimulating factor-encoding, second generation oncolytic herpesvirus in patients with unresectable metastatic melanoma. *J Clin Oncol* 2009; 27: 5763–5771.
- Chesney J, Awasthi S, Curti B, Hutchins L, Linette G, Triozzi P, et al. Phase IIIb safety results from an expanded-access protocol of talimogene laherparepvec for patients with unresected, stage IIIB-IVM1c melanoma. *Melanoma Res* 2018; 28: 44–51.
- Ribero S, Longo C, Glass D, Nathan P, Bataille V. What is new in melanoma genetics and treatment? *Dermatology* 2016; 232: 259–264.
- Quaglino P, Marengo F, Osella-Abate S, Nardò T, Gado C, Novelli M, et al. Vitiligo is an independent favourable prognostic factor in stage III and IV metastatic melanoma patients: results from a single-institution hospital-based observational cohort study. *Ann Oncol* 2010; 21: 409–414.
- Scheibenbogen C, Hunstein W, Keilholz U. Vitiligo-like lesions following immunotherapy with IFN alpha and IL-2 in melanoma patients. *Eur J Cancer* 1994; 30A: 1209–1211.
- Byrne KT, Côté AL, Zhang P, Steinberg SM, Guo Y, Allie R, et al. Autoimmune melanocyte destruction is required for robust CD8+ memory T cell responses to mouse melanoma. *J Clin Invest* 2011; 121: 1797–1809.
- Hua C, Boussemart L, Mateus C, Routier E, Boutros C, Cazenave H, et al. Association of vitiligo with tumor response in patients with metastatic melanoma treated with pembrolizumab. *JAMA Dermatol* 2016; 152: 45–51.
- Phan GQ, Yang JC, Sherry RM, Hwu P, Topalian SL, Schwartzentruber DJ, et al. Cancer regression and autoimmunity induced by cytotoxic T lymphocyte-associated antigen 4 blockade in patients with metastatic melanoma. *Proc Natl Acad Sci U S A* 2003; 100: 8372–8377.