

Intralesional Interferon- α 2b Treatment of Basal Cell Carcinoma

KRISTIAN THESTRUP-PEDERSEN¹, ISA E. JACOBSEN² and GERDA FRENTZ²

¹Department of Dermatology, Marselisborg Hospital, Aarhus, and ²Department of Plastic Surgery, Rigshospitalet, Copenhagen, Denmark

Ten patients with histologically proven basal cell carcinoma were treated with sublesional injections of interferon- α 2b (Introna[®]), 1.5×10^6 units per injection, three times per week for 3 weeks. Six of the treated lesions cleared completely without further therapy. These lesions measured less than 19×19 mm. There was no relapse during an observation period of up to 21 months. Non-healing tumours were large ($> 20 \times 20$ mm) and two of them were of nodular type. Side effects were negligible, if present at all. Introna[®] seems to offer a valuable alternative treatment for selected cases of basal cell carcinoma, when excision or X-ray therapy cannot be performed.

(Accepted March 22, 1990.)

Acta Derm Venereol (Stockh) 1990; 70: 512–514.

K. Thestrup-Pedersen, Department of Dermatology, Marselisborg Hospital, DK-8000 Aarhus C, Denmark.

Basal cell carcinoma (BCC) is the commonest skin cancer in man. It occurs with increased frequency at older age and may arise in any region of the skin.

Three treatment modalities are routinely used: excision, curettage with cauterization, or X-ray irradiation (1–4).

Recently, interferon- α 2b (Introna[®]) has shown a beneficial effect following intralesional injections into basal cell skin tumours (5). This report presents our findings, including patients with multiple BCC.

MATERIALS AND METHODS

Patients

We studied 10 patients with histologically proven BCC (7 women, 3 men), in the age range 38–81 years (median 68 years). The treated skin cancers were on the back (5), chest (3), abdomen (1), and scalp (1). Six patients suffered from multiple BCC; 8 had carcinoma of the superficial spreading type; 2 had nodular BCC.

The size of the BCC varied from 6×7 mm up to 15×25 mm and 19×19 mm in 9 patients, and 45×60 mm in one patient. Duration before therapy was from 1 to 60 months (median 6 months). Five patients had psoriasis and 2 had previously been treated with arsenics, 4 with UV-light, 4 with tar baths, and 7 with soft X-rays.

Treatment

After giving informed consent, all patients underwent a 3-week treatment schedule, receiving intra-/sub-lesional injection of interferon- α 2b (Introna[®]) three times a week. The single dose was 1.5×10^6 units, giving a cumulative dosage of 13.5×10^6 . Two patients received higher dosages; one had a large 45×60 mm nodular BCC on the back and received 6×10^6 per injection, total 54×10^6 units, and the other had a 19×19 mm nodular BCC in the occipital region and received 3×10^6 units per injection, cumulative 27×10^6 units.

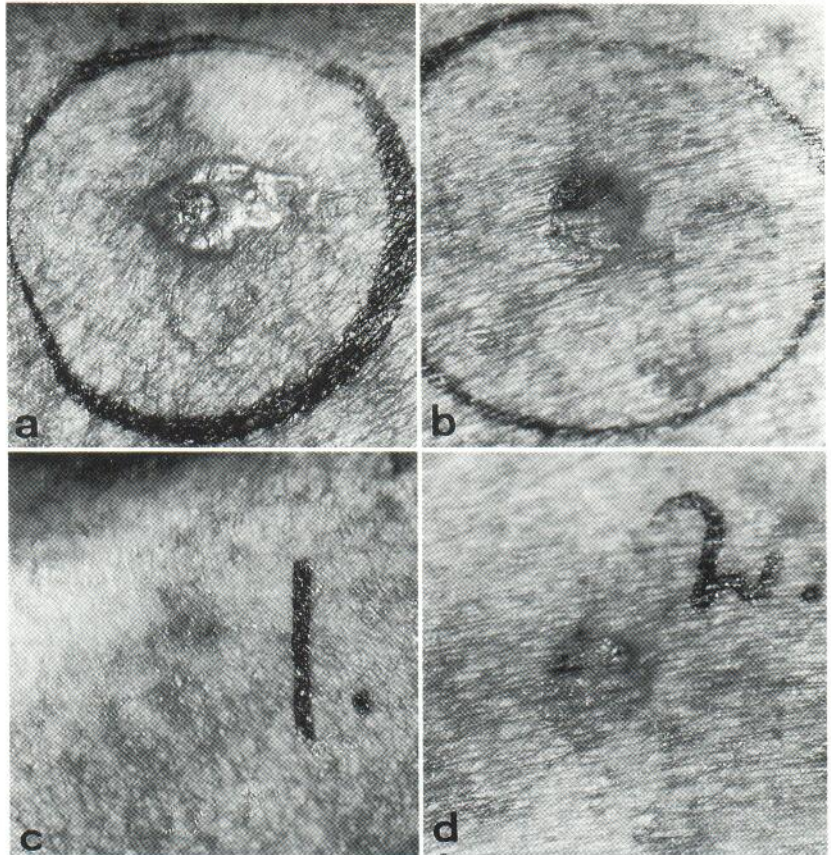
A follow-up check took place after 3 and up to 21 months; median observation period was 14 months.

RESULTS

The treated BCC disappeared completely in 6 patients after using Introna[®] alone. Generally, the size of cured BCC was less than 20 mm in diameter. Typically, the lesion showed less infiltration following a few injections. At 2 months' follow-up after stopping Introna[®], the clinical skin changes had faded, leaving very little redness and scaling, and no scar (Fig. 1). This slow disappearance continues during the ensuing months leaving no trace of BCC ultimately. Five of these 6 patients had multiple BCC. Only the injected BCC improved, leaving non-injected BCC unchanged (Fig. 1).

The remaining 2 patients showed some improvement of their BCC during therapy. The first patient had a large 45×60 mm nodular BCC on the back, which improved clinically, but where histological examination immediately following the last injection showed BCC. The tumour was then excised. The second patient had a 19×19 mm nodular BCC in the occipital region, which ulcerated during therapy and on repeated histological examination immediately following cessation of therapy showed squamous cell carcinoma. The tumour was excised, with skin transplantation. The third patient had a 25×25 mm BCC on the back, which showed initial clinical improvement. Biopsies immediately following therapy showed non-specific changes in the central area of the previous tumour region, but still BCC in the border area. Due to uncertainty of the regression of BCC, curettage and cauterization was performed. The last patient had multiple BCC, which did not

Fig. 1. Effect of Introna® injection in a patient with multiple basal cell carcinoma (BCC). (a, b) two lesions immediately prior to treatment. Only lesion (a) was injected. (c, d) same areas 2 months after cessation of treatment. The injected tumour (a) has completely vanished, while the non-injected tumour (b, d) remains unchanged.



improve clinically, and she was therefore treated with curettage immediately after Introna® was stopped.

All patients had minor, dose-related influenza-like side effects. However, none discontinued therapy. Two patients with psoriasis experienced a local

Koebner phenomenon; one had a sudden swelling at the injection site without evident signs of infection. All blood investigations proved normal.

Table I. Summary of studies using intralesional interferon therapy of basal cell carcinoma

Ref. no.	No. of pats	Single dosage (units × 10 ⁶)	Cumulative dosage	Duration of		CR	FA	SPF	NOD
				Therapy (weeks)	Follow-up (months)				
5	8	1.5	13.5	3	2	8	0	5	3
6	7	0.2	1.6	4	2-3	0	7	0	7
7	6	3.0	27.0	3	5-7	2	4	-	-
8	27	1.5	13.5	3	4	14	13	14	13
9	11	0.9	8.1	3	2	0	11		
*	10	1.5	13.5	3	3-21	6	4	8	2

CR: complete clearing; FA: failure, BCC removed using other treatment; SPF: superficial type of BCC; NOD: nodular type of BCC.

*present study.

DISCUSSION

Several studies have now reported a beneficial effect of interferon in the treatment of BCC, although there is still uncertainty about the amount of interferon required and the duration of therapy in order to achieve optimal results (Table I). Table I shows low dosages of interferon, e.g. 0.2×10^6 (gamma-interferon) or 0.9×10^6 , are insufficient. The most commonly used dosage is 1.5×10^6 and this appears to induce a cure in more than half of the patients. This dosage does not cause any significant side effects. Many of our patients only felt the side effects in connection with the first injection. Interferon- α is known to induce psoriasis, when given systemically (10). We experienced a psoriatic relapse in the injected area in 2 patients with psoriasis and a more universal flare-up in one patient.

The optimal length of therapy is unknown. Three weeks' treatment can certainly cure some of the lesions, though one has to realize that the effect of Introna[®] comes slowly following an initial improvement. It may take 2 months or more before the lesion has completely vanished. Also, the histological changes immediately following therapy may still show areas of BCC or non-specific inflammation. It is our impression that superficial lesions less than approximately 20 mm are adequately treated by following the present protocol. Larger lesions or nodular BCC may need an extended treatment period.

It is likely that Introna[®] augments the cytotoxicity of T cells in contact with BCC cells. Introna[®] is known to be able to potentiate natural killer cell activity (11). Recently, one of us has shown that the number of circulating T-suppressor-cells (Leu 2a+) is significantly increased in persons with multiple sun-induced skin cancers, maybe delaying or inhibiting a rejection of the skin tumours (12). This hypothesis is further supported by our recent finding that the number of circulating natural killer cells (Leu 11+) is diminished in these patients (13). The beneficial effect of Introna[®] might thus be due to its ability to increase the activity of the natural killer cells against the tumour. This hypothesis can also explain why primarily small and superficial tumours respond favourably.

The most convenient therapy for BCC is excision or curettage followed by cauterization. X-ray therapy requires up to 10 individual treatment sessions, and may cause sequelae such as scars from radioder-

matitis (3, 4). The scar formation following intralesional Introna[®] is negligible (see Fig. 1). Introna[®] therefore seems an ideal therapy for areas where excision may be difficult or scar formation unacceptable. Also, Introna[®] could be used before excision in order to reduce the size of the tumour.

This study confirms that Introna[®] is a curative treatment for patients with BCC, preferably with superficial BCC not larger than 20 mm in size. The side effects are few and in most patients negligible.

REFERENCES

1. Reymann F. 15 years' experience with treatment of basal cell carcinomas of the skin with curettage. *Acta Derm Venereol* (Stockh) 1985; suppl 120: 56-59.
2. Kopf AW. Computer analysis of 3531 basal cell carcinomas of the skin. *Int J Dermatol* 1979; 6: 267-282.
3. Reymann F, Kopp H. Treatment of basal cell carcinomas of the skin with ultrasoft X-rays. *Dermatologica* 1978; 156: 40-47.
4. Landthaler M, Hendel B, Schile-Luftmann K, Braun-Falco O. Röntgenweichstrahlentherapie von Lidbasaliomen. *Hautarzt* 1983; 34: 118-122.
5. Greenway HT, Cornell RC, Tanner DJ, Peets E, Bordin GM, Nagi C. Treatment of basal cell carcinoma with intralesional interferon. *J Am Acad Dermatol* 1986; 15: 437-443.
6. Tank B, Habets JMW, Naafs B, Damsma O, Stolz E, van Joost T. Intralesional treatment of basal cell carcinoma with low-dose recombinant interferon gamma. *J Acad Dermatol* 1989; 21: 734-735.
7. Reitamo S, Komulainen M, Lilius P, Grohn P. Treatment of basal cell carcinomas with intralesional interferon alpha-2b. *J Invest Dermatol* 1989; 93: 572 (abstract).
8. Boneschi V, Brambilla L, Mozzanica N, Cattaneo A, Finzi AF. Treatment of basal cell carcinomas with intralesional alpha 2b recombinant interferon. *J Invest Dermatol* 1989; 93: 542-543 (abstract).
9. Wickramasinghe L, Hindson TC, Wacks H. Treatment of neoplastic skin lesions with intralesional interferon. *J Am Acad Dermatol* 1989; 20: 71-74.
10. Quesada JR, Gutterman JU. Psoriasis and alpha-interferon. *Lancet* 1986; i: 1466-1468.
11. Herbermann RB, Ortaldo JR, Bonnard GD. Augmentation by interferon of human natural and antibody-dependent cell-mediated cytotoxicity. *Nature* 1979; 277: 221-223.
12. Frenz G, da Cunha Bang F, Munch-Petersen B, Wantzin GL. Increased number of circulating suppressor T-lymphocytes in sun-induced multiple skin cancers. *Cancer* 1988; 61: 294-297.
13. Frenz G, da Cunha Bang F, Geisler C. The distribution of the subsets of circulating lymphocytes is changed in multiple sun-induced skin cancers in preparation.