

Collagen in the Esophageal Mucosa of Patients with Progressive Systemic Sclerosis (PSS)

LENE HENDEL,¹ THORKIL AMMITZBØLL,¹ KAREN DIRKSEN,²
and MICHAEL PETRI³

University of Copenhagen. ¹Departments of Dermatology (with Connective Tissue Research Laboratories) and ²Radiology, Rigshospital, and ³Department of Histopathology, Sundby Hospital, Copenhagen, Denmark

Hen del L. Ammitzbo ll T. Dirksen K. Petri M. Collagen in the esophageal mucosa of patients with progressive systemic sclerosis (PSS). Acta Derm Venereol (Stockh) 1984; 64: 480-484.

Eighteen consecutive patients with an established diagnosis of Progressive Systemic Sclerosis (PSS) underwent different investigative procedures to determine possible esophageal involvement. Esophageal sclerosis was demonstrated by X-ray and manometry in 13 patients. In all patients endoscopic biopsies of esophageal mucosa were obtained. In all biopsies the concentrations of hydroxyproline, hydroxylysine and proline were determined. Patients suffering from PSS involving the esophagus were found to have a significantly higher concentration of collagen specific amino acids (hydroxyproline and hydroxylysine) in the esophageal mucosa (endoscopic obtainable biopsies) than patients with PSS not affecting the esophagus. *Key words: Esophageal manometry; Esophagoscopy; Hydroxyproline; Hydroxylysine; Scleroderma.* (Received February 5, 1984.)

L. Hendel, Department of Dermatology, University of Copenhagen, Rigshospital, DK-2100 Copenhagen, Denmark.

In patients with Progressive Systemic Sclerosis (PSS) an involvement of the gastrointestinal tract is often found.

Most frequently affected is the esophagus. The aim of the present study is to provide a biochemical method to distinguish esophageal involvement in the PSS syndrome. By measuring the concentration of collagen specific aminoacids we describe a biochemical profile of the esophageal mucosa.

MATERIAL

Eighteen consecutive patients, i.e. 17 females and one male, admitted to the University Hospital Department of Dermatology with an established diagnosis of generalized scleroderma (PSS), were examined in order to demonstrate esophageal involvement.

Excluded were only patients with interfering systemic diseases (i.e. diabetes mellitus). Eleven of the 18 patients suffered from dysphagia and heart burn.

Seventeen out of 18 patients were permanently treated with collagen biosynthesis inhibitors.

A combination of D-penicillamine and glutamine was used in 14 patients. Glutamine combined with hydralazine was used in one patient and combined with prednisone in one patient. One patient received glutamine alone (1). Mean age of the patients was 55 years, range 32-70 years.

Mean duration of the disease was 9.3 years, range 1-28 years.

METHODS

The investigative program included the following.

X-ray of the esophagus was done as a cine-radiographic examination of a barium swallow. The patient was asked to drink contrast material in small portions and was examined standing as well as in a horizontal position. While lying, the patient was examined in the prone and supine position as well as with the table in Trendelenburg position (2).

Impaired or absent peristalsis, dilatations with or without strictures were considered abnormalities due to PSS affection (3, 4). Hiatal hernia, gastroesophageal reflux and strictures only were noted but did not influence categorization.

Manometry. For the manometric study, a pressure probe consisting of two polyethylene catheters (Clay Adams, PE160, i.d. 1.14 mm, o.d. 1.57 mm) was used (5). Lower esophageal sphincter (LES) pressure gradient, esophageal peristalsis and upper esophageal sphincter (UES) gradient were evaluated. The pressure measurements were registered with an interval of 1 cm (intermittent withdrawal) and the patient was asked to swallow at every step (dry swallows) (5).

Again diminished-to-absent peristalsis in the lower 2/3 of the esophagus and/or a diminished LES pressure were considered diagnostic of PSS of the esophagus (3).

If any disagreement between radiology and manometry occurred it was decided to accept the manometric outcome for categorization (6).

Esophagoscopy and biopsy procedure. Esophagoscopy was performed in the morning after an overnight fast. An Olympus fiberoptic panendoscope (GIF-K or GIF-P₂) was used. Mucosal biopsies were removed circumferentially about 5 cm above LES.

If any evidence of esophagitis was noted biopsies from the inflamed mucosa were taken as well as biopsies from the most distal normal appearing mucosa. The latter biopsies were used for biochemical evaluation.

Biopsy evaluation

Histopathology. The biopsies were fixed in Lillies solution, stained with hematoxylin/eosin or Alcian Blue and examined under a light microscope. This examination was carried out in a blinded manner.

Biochemistry. Hydroxyproline (Hyp) and hydroxylysine (Hyl) are collagen specific amino acids. Proline (Pro) occurs in higher amount in collagen than in other proteins. Hyp, Hyl or Pro were assayed by a method developed in this laboratory (7, 8). The limits of detection are 9 nmol Hyp/mg, 1 nmol Hyl/mg, and 15 nmol Pro/mg. The reproducibility is demonstrated by a deviation on double estimations of approx. 2%.

The biopsies were extracted with acetone and ether and dried under vacuum. The defatted, dried tissue was hydrolysed in 6 N HCl at 118°C for 18 h and evaporated to dryness at 60°C at 50 mbar. The residue was dissolved in 0.046 M citrate-0.415 M phosphate buffer pH 7.0 and analysed for Hyp, Hyl and Pro in three AutoAnalyzers⁹.

Hyp was oxidised by chloramine T forming a pyrrole derivation which was colored with *p*-dimethylaminobenzaldehyde and quantitatively determined photometrically.

Hyl was oxidised by sodium meta-periodate and colored with *p*-aminobenzaldehyde before photometrical detection.

Pro was heated with ninhydrin reagent at 75°C and the chromogen was read at 515 nm.

Statistics

The Wilcoxon rank sum test for unpaired data was used for statistical analysis.

RESULTS

X-ray and manometry

According to our diagnostic criteria 13 out of 18 patients suffering from PSS had esophageal manifestations.

In one patient with normal esophageal manometry a hiatal hernia caused X-ray misinterpretation.

A grading of the esophageal involvement was not intended.

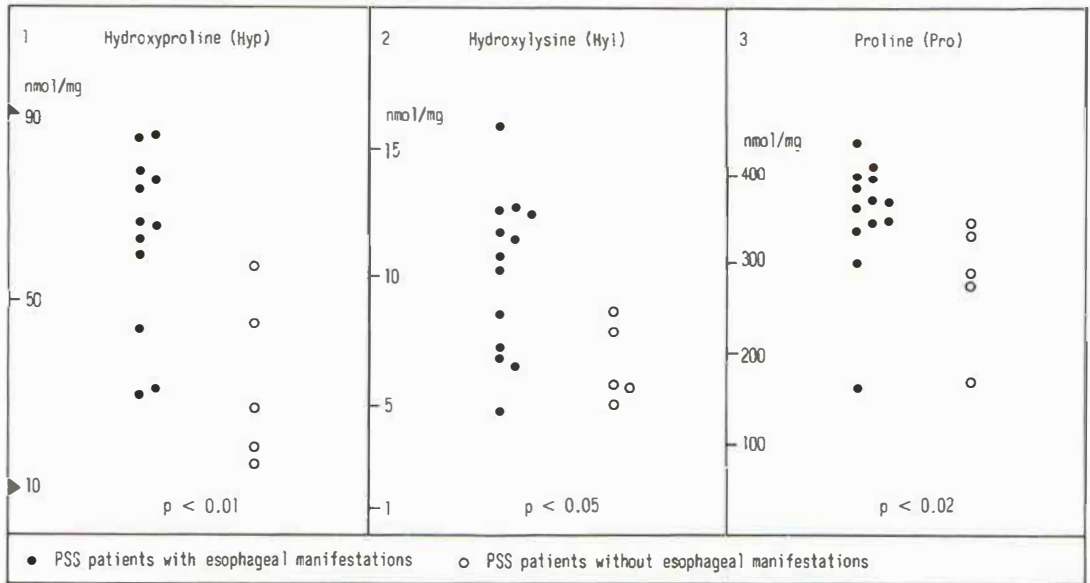
Histopathology

Routine histology showed all specimens to reach the level of the muscularis mucosa. No evidence of inflammation was observed. In three biopsies, all from esophagus affected by PSS, a slight mucosal fibrosis was demonstrated.

Biochemistry

A certain amount of collagen was demonstrated in the esophageal mucosa of PSS patients.

Patients with esophageal involvement demonstrated a significantly higher collagen



Figs. 1, 2 and 3 show the concentration of Hyp, Hyl and Pro, respectively, in the esophageal mucosa from PSS patients. The concentration is measured as nmol amino acid per mg defatted, dried mucosa. ● Refers to patients with PSS including esophageal manifestations. ○ Refers to patients with PSS without esophageal involvement. The determination of Hyp has slipped in one patient. A significant difference in Hyp, Hyl and Pro concentration between the two groups of patients is found. For statistical analysis the Wilcoxon rank sum test is used.

concentration in the esophageal mucosa than patients without esophageal involvement (Figs. 1, 2, 3).

No correlation between age or duration of disease and concentration of Hyp and/or Hyl and/or Pro in the esophageal mucosa was observed.

DISCUSSION

Esophageal manifestations are present in 70% of patients with PSS.

However, as many as one-half of these patients remain asymptomatic. On the other hand, if symptoms are present, abnormalities in esophageal radiographic or physiological studies are highly likely to be found (9).

Dysphagia and heartburn are the complaints most frequently noted.

Dysphagia is caused by dysmotility diagnostic for PSS, while heartburn is due to the gastroesophageal reflux, often complicating PSS of the esophagus (patulous LES, impaired peristalsis).

Several investigative procedures are useful in the diagnosis of esophageal PSS. Conventional X-ray examination (barium swallow) combined with cineradiography and manometry are common methods. Manometry is considered the most sensitive method for detecting impaired motility and diminished-to-absent tone in LES (6).

Endoscopy is unavoidable to detect and value therapy of esophagitis and to exclude malignancy but does not contribute to the diagnosis of PSS.

When dealing with surgical or autopsy (whole wall) specimens, histopathology may confirm the diagnosis of PSS. The gastrointestinal wall is atrophic rather than fibrotic, although fibrosis may occur (10). Atrophy as well as fibrosis are confined to the tunica

muscularis. Ultrastructural investigation of the whole esophageal wall contributes with information on damaged vasculature in the same area (11).

Up to the present day, histopathology (light microscopy of endoscopic mucosal biopsies) has been of no diagnostic or prognostic value. Electron microscopic examinations, however, have revealed fibrosis in the muscularis mucosa in the small intestine (12).

A biochemical evaluation, i.e. an estimation of the concentration of collagen specific amino acids in the esophageal mucosa has not previously been reported. Considering results from experimental work on the aorta, lamina propria might be the location for collagen depositions to take place (13).

It is generally accepted that the very severe esophagitis often seen as a complication in PSS simulates any other reflux esophagitis and is not facilitated by any special mucosal condition (10). It is accepted, too, that formation of esophageal strictures is based on chronic regurgitation and is not influenced by the basic illness. We question whether this notion is correct, knowing, as a new piece of information, that the mucosal collagen metabolism is altered.

We suspect that the pathogenesis of esophagitis and esophageal stricture formation in the PSS syndrome is much more complicated than hitherto assumed.

IN CONCLUSION

An altered collagen metabolism in the esophageal mucosa of PSS patients is demonstrated.

This discovery together with the electron microscopic detection of fibrosis in the muscularis mucosa indicate a complexity of changes in the wall of the gastrointestinal tract implying not only atrophy of functional tissue (smooth muscle) with fibrotic repair but formation of excess collagen as well.

ACKNOWLEDGEMENT

We want to thank Mr Ole Christensen for skilful technical assistance concerning the determination of tissue collagen and Mrs Inger Johansson for her typing the manuscript.

REFERENCES

1. Asboe-Hansen G. Treatment of generalized scleroderma with inhibitor of collagen synthesis. *Int J Dermatol* 1982; 21: 159-161.
2. Clements PV, Kadell B, Ippoliti A, Ross M. Esophageal motility in progressive systemic sclerosis. *Dig Dis Sci* 1979; 24: 639-644.
3. Cohen S, Laufer I, Snape WJ, Shiao Y, Levine GM, Jimenez S. The gastrointestinal manifestations of scleroderma: Pathogenesis and management. *Gastroenterology* 1980; 79: 155-166.
4. Gondos B. Roentgen manifestations in progressive systemic sclerosis. *Am J Roentgenol* 1960; 84: 235-247.
5. Aggestrup S, Sørensen A, Carstensen HE, Sørensen HR. Computerized 12-hour simultaneous ECG, pressure and pH-probe investigation of the esophagus. Method and reference values in healthy individuals. *Scand J Clin Lab Invest* 1981; 41: 749-756.
6. Wehrauch TR, Korting GW. Manometric assessment of oesophageal involvement in progressive systemic sclerosis, morphea and Raynaud's disease. *Br J Dermatol* 1982; 107: 325-332.
7. Blumenkrantz N. Automated triple assay for proline, hydroxyproline and hydroxylysine on one single sample. *Clin Biochem* 1980; 13: 177-183.
8. Blumenkrantz N, Asboe-Hansen G. Methods for analysis of connective-tissue macromolecules by determination of certain constituents. In: *Methods of Biochemical Analysis* (ed. D. Glick), vol. 24, pp. 39-91. Wiley, New York, 1977.
9. Poirier TJ, Rankin GB. Gastrointestinal manifestations of progressive systemic scleroderma based on a review of 364 cases. *Am J Gastroenterol* 1972; 58: 30-44.

10. D'Angelo WA, Fries VF, Masi A, Shulman LE. Pathologic observations in systemic sclerosis (scleroderma). *Am J Med* 1969; 46:428-440.
11. Russell LM, Friesen D, Henderson RD, Hanna WM. Ultrastructure of the esophagus in scleroderma. *Arthritis Rheum* 1982; 25:1117-1123.
12. Greenberger NV, Dobbins WO, Ruppert RD, Jesseph JE. Intestinal atony in progressive systemic sclerosis (scleroderma). *Am J Med* 1968; 4:301-308.
13. Collatz Christensen B. Studier over normalt og helende endothel. Thesis. FADL. Odense 1981.