

Keratoconus as a Possible Side-effect of Acitretin (Neotigason) Therapy

Sir,

A 47-year-old woman had a severe hyperkeratotic eczema of the palms for about 3 years. The patient had not responded to a variety of treatments, including potent corticosteroid ointments. The condition became incapacitating, and the patient was treated orally with acitretin (0.7 mg/kg/day). After a few weeks a marked clinical improvement was observed. But due to well-known retinoid side-effects – including hair loss, cheilitis, dry eyes and elevated se-cholesterol – the patient had her acitretin dose halved after 2 months. After another 2 months of therapy she developed brachial neuritis on the left side with severe pain around the shoulder, paralysis of the deltoid muscle, paresis of the biceps muscle and an absent biceps reflex. X-rays of the cervical spine showed no exostoses. Acitretin was stopped, and within 3 months the function of the left shoulder was restored to normal. Six months later acitretin therapy was reintroduced in a dose of 0.1 mg/kg/day due to a severe relapse of the skin disease, but 3 weeks later the patient complained of visual disturbances causing withdrawal of acitretin therapy.

An earlier routine ophthalmologic examination at the age of 28 had revealed an astigmatism of 3 diopters of the left eye. At the recent examination an astigmatism of 12 diopters of the left eye with a visual acuity of 20/40 was found. The slit lamp examination of the left eye showed pronounced keratoconus with marked corneal thinning of the inferior nasal quadrant (Fig. 1). Visual acuity and the results of the slit lamp examination of the right eye were normal. Ophthalmoscopic examination, visual fields, and intraocular pressures were normal on both eyes. There were a slight ptosis of the right eyelid and paresis of upward gaze on the right eye and decrease abductions on both eyes. Both pupils reacted to light. There was no sign of myasthenia gravis: The patient had normal strength of

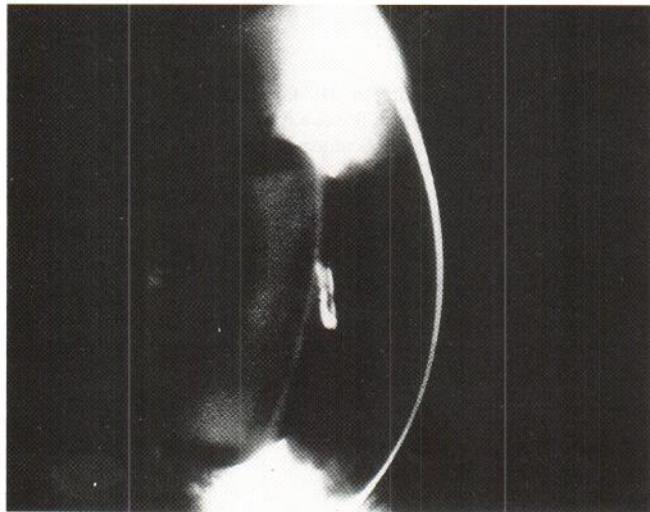


Fig. 1. Slit lamp examination of the left eye showing marked corneal thinning of the inferior nasal quadrant.

the facial muscle and the extremities, and plasma acetyl receptor antibodies were negative. CT-scan of the brain was normal. At a follow-up 12 months later, the keratoconus was unchanged and the patient is now wearing a haptic contact lens.

Fraunfelder et al. (1) reported that in 12 out of 237 patients treated with isotretinoin corneal opacities developed. In 4 cases the lesions were diffuse but included a diamond-shaped or triangular pattern with one base adjacent to the nasal corneoscleral limbus. Four patients wore contact lenses and had increased keratometric values, which, however, returned to normal within 10 months after cessation of therapy. Also, 3 cases of keratoconus were reported. To our knowledge, the present patient is the first reported case of keratoconus occurring during acitretin therapy.

Treatment with acitretin may be associated with musculo-skeletal complaints (2) and the appearance or growth of ligamentous or soft tissue calcifications (3). In the present case, it is not clear whether the development of brachial neuritis was related to the acitretin therapy.

It has been reported that retinoids are potent inhibitors of collagen gene expression, and that they also interfere with the collagen degradative pathway (4). The net result of collagen deposition is therefore dependent on the relative effect on the expression of genes encoding collagens, collagenase and its inhibitors. The decrease in cornea thickness may also be due to a decrease in the major constituent of the cornea, i.e. water. Theoretically, this could be achieved by alterations of the active regulation of the water migration in the cornea or by secondary changes in the composition on the glycosaminoglycans in the cornea ground substance.

Dermatologists should be aware of possible ocular side-effects, including cornea thinning, during retinoid therapy and a pretreatment evaluation of the visual function is suggested.

REFERENCES

1. Fraunfelder FT, LaBraico JM, Meyer SM. Adverse ocular reactions possibly associated with isotretinoin. *Am J Ophthalmol* 1985; 10: 534–537.
2. Gollnick H, Bauer R, Brindley C, et al. Acitretin versus etretinate in psoriasis. *J Am Acad Dermatol* 1988; 19: 458–469.
3. Kilcoyne RF. Effects of retinoids in bone. *J Am Acad Dermatol* 1988; 19: 212–216.
4. Uitto J, Olsen DR. Retinoid modulation of cutaneous extracellular matrix gene expression. In: Reichert U, Shroot B, eds. *Pharmacology of retinoids in the skin*. Basel: Karger, 1989: 37–44.

Received October 27, 1992

Frederik Grønhøj Larsen¹, Sven Rud Andersen², Kaare Weismann¹, Kim Julian³ and Peer Tfelt-Hansen⁴.

¹Department of Dermatology, Bispebjerg Hospital, University of Copenhagen, ²Eye Clinic, Farum, ³Department of Ophthalmology, Hvidovre Hospital, University of Copenhagen, and ⁴Department of Neurology, Bispebjerg Hospital, University of Copenhagen, Copenhagen, Denmark.