

ORIGINAL REPORT

IMPACT OF INTERNAL CAPSULE LESIONS ON OUTCOME OF MOTOR HAND FUNCTION AT ONE YEAR POST-STROKE

Sven K. Schiemanck, MD, PhD^{1,2,3}, Gert Kwakkel, PhD^{2,3,4}, Marcel W. M. Post, PhD^{2,3}, L. Jaap Kappelle, MD, PhD^{3,5} and Arie J. H. Prevo, MD, PhD^{2,3}

From the ¹Department of Rehabilitation, Academic Medical Center (AMC), Amsterdam, ²Center of Excellence for Rehabilitation Medicine, Rehabilitation Center De Hoogstraat, ³Rudolf Magnus Institute of Neuroscience, University Medical Center, Utrecht, ⁴Department of Rehabilitation, VU University Medical Centre, Amsterdam and ⁵Department of Neurology, University Medical Center Utrecht, The Netherlands

Objective: To investigate the association between damage to different levels of the corticofugal tract and long-term hand motor recovery.

Design: Prospective cohort study.

Patients: Seventy-five first-ever middle cerebral artery stroke survivors.

Methods: Hand motor function was assessed with the Fugl-Meyer Motor Assessment Scale at one year post-stroke. Localization of the corticofugal tract was assessed on axial magnetic resonance imaging slices using a corticofugal mask defining involvement of the motor cortex, corona radiata or internal capsule and combinations of these structures, adjusted for lesion volume.

Results: Longitudinal involvement of all 3 levels of the corticofugal tract and partial involvement of the internal capsule were associated with a significant probability of poor motor hand function recovery. The probability of regaining hand function ranged from 54% if the corticofugal tract was only partly affected to 13% if both motor cortex and internal capsule were affected.

Conclusion: At one year post-stroke, lesions of the internal capsule were associated with a significantly lower probability of return of isolated hand motor function than lesions of the cortex, subcortex and corona radiata. Since recovery of isolated hand and finger movements is important for regaining a functional upper limb in everyday living, these patients should be identified early post-stroke in order to evaluate specific hand function training.

Key words: cerebrovascular accident, magnetic resonance imaging, middle cerebral artery, motor activity, prognosis.

J Rehabil Med 2008; 40: 96–101

Correspondence address: Sven Schiemanck, Department of Rehabilitation, Academic Medical Center (AMC), Room A01.424, Meibergdreef 9, PO Box 22660, NL-1100 DD Amsterdam, The Netherlands. E-mail: S.K.Schiemanck@amc.uva.nl

Submitted December 5, 2006; accepted August 22, 2007.

INTRODUCTION

Studies using magnetic resonance imaging (MRI) suggest that the localization rather than the volume of an infarct is important

for predicting functional outcome after a stroke in the territory of the middle cerebral artery (MCA) (1, 2). Lesion localization may support clinicians in their understanding of the composition of found deficits. The impact of lesion localization has been found to be especially strong in stroke survivors with small infarcts (3). The localization of hemispheric infarction is particularly important for predicting the probability of motor recovery after stroke (1, 4). For example, Shelton & Reding (4) found, in 41 patients, that the probability of recovery of isolated upper limb movement in terms of the Fugl-Meyer motor score (5) decreases progressively with the involvement of the corona radiata or internal capsule. Patients with a purely cortical stroke were more likely to recover upper limb function than patients with purely subcortical or mixed cortical and subcortical stroke (4). Patients in whom the posterior limb of the internal capsule had been spared particularly tended to show more individuated and independent synergistic motor control of the upper paretic limb compared with those in whom the posterior limb of the internal capsule was affected (4). Unfortunately, the study by Shelton & Reding did not control for lesion volume, it restricted follow-up to the first 2 months after stroke, and focused on the movement control of the paretic arm and not the hand. The impact of lesion localization on long-term hand motor function, after correction for lesion volume, has not been investigated. Acknowledging that functional recovery of the upper limb is determined mainly by return of isolated function (6, 7), the aim of the present study was to investigate the predictive value of hemispheric stroke localization for the recovery of hand function one year post-stroke.

SUBJECTS AND METHODS

The study population comprised patients with a first-ever ischaemic stroke admitted to 1 of 6 participating stroke units in the Netherlands between 1999 and 2001. Details of the study population were described in a previous study on the prediction of long-term independency in activities of daily living after MCA stroke (2). Stroke was defined as a rapidly developing sign of focal or global disturbance of cerebral function with symptoms lasting 24 h or longer or leading to death, with no apparent cause other than vascular origin (8). Patients included in the present study had suffered a non-lacunar first-ever ischaemic MCA infarction, were between 18 and 85 years of age, and had a pre-morbid Barthel Index (BI) ≥ 18 and a stable neurological condition

one week after stroke. Participants were not treated with thrombolysis or neuroprotective agents and showed a visible lesion on the MRI scan as established by an independent neuro-radiologist. Patients with lesions outside the territory of the MCA, such as infra-tentorial infarcts, border-zone infarcts, infarcts in both hemispheres and lacunar infarcts (9, 10) were excluded from the analysis. Lacunar infarctions were defined as infarctions in the deep white matter of the brain, caused by an occlusion of small perforating arteries, with a diameter of 3–4 mm to a diameter of 15–20 mm located at the site of the basal ganglia, internal capsule, or corona radiata (9, 10). Finally, patients with pre-morbid cognitive limitations or co-morbidity influencing functional outcome were excluded.

After informed consent had been given, an MRI scan was obtained at a mean of 11 days (standard deviation (SD) 3.5 days) after stroke. Data about stroke severity (National Institutes of Health Stroke Scale (11) and Glasgow Coma Scale (12) at hospital admission were retrieved retrospectively from medical records (13). Patient characteristics, such as age, gender and marital status, were recorded, and one observer experienced in neurological examination (blinded for the neuro-imaging findings) assessed body functions and activities approximately 6 days after stroke. Cognitive functioning was assessed using the Mini Mental State Examination (14). Severity of paresis was measured with the Motricity Index (MI) (15) and sitting balance with the Trunk Control Test (16), whereas activity limitations were assessed with the BI (17) and the modified Rankin Scale (18). The research protocol was approved by the medical ethics committee of University Medical Center Utrecht.

Dependent variable

Motor recovery of the upper limb was assessed with the Fugl-Meyer upper limb motor score (FM-UL) of the Fugl-Meyer Motor Assessment Scale (5), one year after stroke (mean 377 days; SD 22 days). The FM-UL comprises 5 different stages, involving: (i) deep tendon reflexes, (ii) synergistic mass movements, (iii) gross non-synergy-dependent movements, (iv) fine isolated muscle movements, and (v) testing motor co-ordination of upper and lower limbs. For the present study, we used its hand motor score, investigating flexion of the fingers, extension of the fingers, hook grasp, lateral prehension grip, palmar prehension grip, cylindrical grasp and spherical grasp. The hand score ranged from 0 (plegic) to 14 (normal). The optimal cut-off value of the FM hand score (FM-HS) for hand recovery was based on existing data from a population of 102 patients with MCA infarct (19). On the basis of the findings of a previous study (19), the optimal cut-off point for dichotomization of the FM hand score into functional and non-functional return of hand motor function was determined with the Action Research Arm Test (20), with a cut-off value of 10 points (19). On the basis of the area under the curve the optimal dichotomization point for the FM-HS in our study was set at 3 points (area under the curve 0.99; standard error 0.01; $p < 0.01$; 95% confidence interval (CI) 0.98–1.00; sensitivity 1.00; 1 – specificity 0.098). Persons with an FM-HS of 0–3 were defined as patients with “poor” recovery of hand function, as they showed no voluntary hand function due to the inability to extend the fingers. Patients with an FM-HS of 3–14 were defined as showing “good” recovery, as they were able to extend their fingers and hence perform various manipulations with the hand (21, 22). All patients were assessed by the same researcher.

Independent variables

All scans were performed with a standard scanning protocol using 0.5, 1.0 or 1.5 Tesla MRI scans, with identical number of slices, thickness and gap. Scans were stored digitally and further analysed using a Philips Easy Vision Workstation®. Areas of abnormal hyper-intensity typical for recent cerebral infarction were traced on each slice of the T2-weighted and/or fluid-attenuated inversion recovery images. Surfaces of areas of abnormal hyper-intensity were summed and multiplied with slice thickness (6 mm) and interslice gap (1.2 mm) to calculate infarct volumes. Lesion volumes were added as a covariate in the statistical analysis in order to investigate the relationship between

lesion localization and outcome of hand motor function. Assessment of lesion localization and volume was performed de-identified and blinded for the patients’ clinical status and motor functioning, by a research fellow in collaboration with and under the auspices of an experienced neuroradiologist (2). Lesion localization was defined using Matsui & Hirano’s neuroanatomical atlas (23). The involvement of the descending motor tracts was assessed as follows. The pre-central gyrus was localized according to its neuroanatomical landmarks with the help of the brain atlas (23) using axial slices of the MRI scan. The pre-central gyrus is in front of the post-central gyrus from which it is separated by the central sulcus. The motor cortices were defined, and the white matter tracts descending were determined through the corona radiata to the internal capsule. We used templates (24) based on the Matsui & Hirano atlas (23) to classify for each patient which structures of ischaemic infarct were affected, i.e. (i) the motor cortex; (ii) the corona radiata, or (iii) the internal capsule (Fig. 1). For each axial slice of the brain, the anatomical structure related with (i) the motor cortex; (ii) the corona radiata, or (iii) the internal capsule was scored separately as 0 (not affected) or 1 (affected). In addition, we investigated whether combinations of the above structures were affected, viz. (i) motor cortex and corona radiata, (ii) corona radiata and internal capsule, (iii) motor cortex and internal capsule. Since most motor efferents are located in the posterior part and genu of the internal capsule (25, 26), the template for the internal capsule was divided into an anterior part (anterior limb) and a posterior part (genu and posterior limb).

Data analysis

The *t*-test was applied to compare the characteristics of those patients who dropped out of the study with those who were available for further analysis (SPSS, version 12.0.1 for Windows). Subsequently, bivariate logistic regression analyses were used to evaluate the predictive value of the involvement of specific localizations and combinations of structures of the corticofugal tract for poor or good motor recovery of hand function. Analyses of the relationship between ischaemic lesion localization and hand motor recovery were adjusted for lesion volume by adding lesion volume as a continuous covariate in the regression

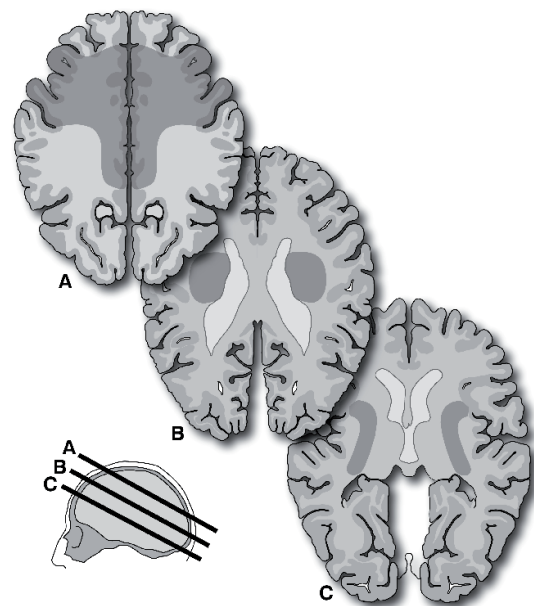


Fig. 1. Three examples of axial brain templates used to identify lesions in motor cortex (A), corona radiata (B) and internal capsule (C). (Localization of interest is shaded dark-grey). (Templates adapted from Matsui & Hirano (23)).

analysis. Since lesion volume was not normally distributed in our study population, data reflecting volume were logarithmic transformed. Bivariate odds ratios (ORs) and 95% CI were calculated. Subsequently, the probabilities of the odds were calculated using the equation $p = 1/(1 + \exp^{(B_0 + B_1X_1 + B_2X_2 + \dots + B_nX_n)})$ (19). In this multivariate logistic regression model represents “*p*” the probability of regaining dexterity. B represent regression coefficients for intercept (i.e. B_0) and included determinants in the model ranging from X_1 to X_n , respectively. Each hypothesis was tested 2-tailed with a significance level of 0.05.

RESULTS

Twenty-one of the 115 patients scanned were excluded because of their MRI findings. These patients had previous stroke lesions or lesions due to other neurological disorders ($n = 4$); infra-tentorial lesions ($n = 10$); infarctions in both hemispheres ($n = 5$); or a border-zone infarction ($n = 1$). In one patient, the MRI scan could not be evaluated due to movement artefacts. A further 19 patients were excluded from analysis due to death ($n = 9$), recurrent stroke ($n = 4$), co-morbidity that seriously affected functional outcome ($n = 2$), or refusal to participate in the follow-up assessment ($n = 4$). Baseline characteristics of the 13 patients with an MCA infarct who died or had a recurrent stroke were compared with those of the remaining 75 MCA patients who were available for further analysis. These 2 groups did not differ significantly in terms of age ($p = 0.19$); gender ($p = 0.63$); stroke severity in terms of the National Institutes of Health Stroke Scale (NIHSS; $p = 0.71$); lesion location ($p = 0.89$); mean lesion volume ($p = 0.87$); or hemisphere of stroke ($p = 0.83$).

Table I presents baseline characteristics, functional status and neuro-imaging variables of the 75 patients assessed at 6 days (mean 5.6 days; SD 2.6; range 1–13 days), and at one year post-stroke. Table II shows the place of dismissal of the patient after hospital care and the type of therapy received after stroke. Median Glasgow Coma Score at admission was 15 (interquartile range (IQR) 25–75%; 15–15), and median stroke severity at admittance was 12 (NIHSS; IQR 7–15), indicating that most patients had moderate neurological deficits. Median BI at 6 days after stroke was 8 out of 20 points (IQR 4–17). Seventy-two percent of the patients showed adequate sitting balance, while the median Motricity Index of the arm and leg were 50 and 75 points, respectively (Table I). At one year post-stroke, 33 patients (56%) were independent in terms of BI and 49 patients (65%) had good motor hand function in terms of the FM-HS.

Association between stroke localization and isolated hand motor function

Table II shows ORs and 95% CIs from bivariate logistic regression analysis of lesion localization and poor motor recovery of hand function, after adjusting for logarithmic transformed lesion volume. The corticofugal tract was affected in 55 of the 75 MCA stroke patients. Twenty-five (46%) of these 55 patients with involvement at one or more levels of the corticofugal tract showed poor hand recovery, whereas only one (5%) of the patients whose corticofugal tract was not affected ($n = 20$) (OR

Table I. Patient characteristics, functional status, neuro-imaging variables and functional outcome ($n = 75$)

Characteristics	Total
Gender, M/F	35/40
Age, years, mean (SD)	63 (15)
Having a partner, yes/no	53/22
Educational level, low/high	42/33
<i>Functional status (about 6 days after stroke)</i>	
GCS; median (IQR)	15 (15–15)
NIHSS; mean (SD)	11 (6)
Barthel Index (0–20), day 6; median (IQR)	8 (4–17)
MMSE; median (IQR)	26 (23–28)
<i>Motricity Index:</i>	
Arm; median (IQR)	50 (0–92)
Leg; median (IQR)	75 (14–100)
Modified Rankin; median (IQR)	3 (2–4)
Urinary incontinence, yes/no	34/41
Sitting balance, yes/no	54/21
<i>Neuro-imaging variables (about 11 days after stroke)</i>	
Number of days post-stroke before MRI; mean (SD)	11 (3.5)
Hemisphere, left/right	38/37
Median volume (IQR)	31.9 (6.3–91.2)
<i>Functional outcome (1 year after stroke)</i>	
<i>Fugl-Meyer Motor Assessment Scale:</i>	
Upper extremity score; median (IQR)	58 (7–65)
Lower extremity score; median (IQR)	29 (15–33)
Hand score; median (IQR)	12 (1–14)
Hand score (poor outcome 0 < 3; good outcome 1 ≥ 3)	26/49
<i>Motricity Index:</i>	
Arm; median (IQR)	83 (29–100)
Leg; median (IQR)	91 (50–100)

M/F: male/female; GCS: Glasgow Coma Scale; NIHSS: National Institutes of Health Stroke Scale; MMSE: Mini Mental State Examination; MRI: magnetic resonance imaging; IQR: interquartile range; 1st, 3rd percentile; SD: standard deviation.

1.48; 95% CI 0.62–3.49; $p = 0.38$) had poor hand function after one year. In our study population, 15 patients had involvement of all identified levels of the corticofugal tract (i.e. motor cortex, corona radiata and internal capsule) and showed a significant probability of poor hand function recovery (OR 16.25; 95% CI 2.97–88.91; $p = 0.01$). Patients in whom the internal capsule was partly affected on MRI had a significant probability of poor

Table II. Place of dismissal of the patient and type of therapy after hospital care

	%
<i>Dismissal after hospital care, to:</i>	
Home	35
Rehabilitation centre	37
Geriatric home	4
Nursing home	23
Other	1
<i>Physical and occupational therapy</i>	
None	8
Home	16
Outpatient rehabilitation centre	16
Clinical rehabilitation centre	32
Rehabilitation at nursing home (< 1 year)	15
Long-stay nursing home	13

hand recovery (OR 2.90; 95% CI 1.09–7.76; $p = 0.04$). The found OR of 2.9 presented in Table I indicates that the probability for no return or only some dexterity (i.e. poor dexterity) of the paretic limb at one year is 2.9 times more likely in those patients in which the CI is affected compared with those in which the CI is not affected. No differences in the probability of regaining hand function were found between involvement of the anterior part (anterior limb) (OR 7.54; 95% CI 2.03–27.97; $p = 0.01$) and the posterior part (genu and posterior limb) (OR 3.33; 95% CI 1.17–9.42; $p = 0.02$) of the internal capsule. Combining the infarcted structures of the corticofugal tract system (i.e. motor cortex and corona radiata, corona radiata and internal capsule or motor cortex and internal capsule) resulted in a significantly lower probability of hand function recovery if the internal capsule was affected (Table III).

DISCUSSION

The aim of the present study was to investigate the association between damage to different levels of the corticofugal tract and long-term hand motor recovery. The study shows that the return of hand function one year after stroke largely depends on the preservation of neuroanatomical areas known to represent the corticofugal tract of the upper limb. In particular, we found that the involvement of structures with a greater density of corticofugal tract fibres, i.e. the internal capsule, was associated with poor recovery of hand motor function at one year after MCA stroke. The probability of recovery of some or all of the hand function ranged from 51% for those patients in whom the motor cortex was affected, to only 13% for those patients in whom both motor cortex and internal capsule were affected. The findings of the present study also suggests that in humans, spared cerebral motor areas and descending pathways that remain might activate finger muscles, but cannot fully compensate for the highly selective control provided by the primary motor cortex and the crossed corticofugal tracts (22, 27, 28).

Our findings are in agreement with a previous study of stroke patients in an inpatient stroke rehabilitation centre, who had been admitted 2 weeks after an initial unilateral hemispheric ischaemic stroke (4). In that study the probability of recovery of proximal isolated upper limb movement at approximately 2 months after stroke decreased progressively with lesion location in the following order: cortex, corona radiata, and internal capsule. In contrast to the study by Shelton & Reding (4), we did not find a significant difference in recovery of the paretic hand between patients with involvement of the anterior or posterior limb of the internal capsule. A possible explanation is that our study could not differentiate properly between the anterior and posterior limb, due to extensive overlap of the lesions in these 2 regions, even after correction for lesion volume. Another explanation may be that we excluded patients with small isolated internal capsule involvement caused by small lacunar stroke. These patients are generally expected to have a good motor outcome because the internal capsule is only minimally affected. In addition, it should be noted that corticofugal parts of the hand representation of the rostral cingulated cortex and supplementary cortex pass through the middle and posterior parts of the anterior limb of the internal capsule in rhesus monkeys (26). Apart from the finding that anterior limb lesions also resulted in poor outcome for the upper limb, the findings of the present study are in agreement with existing knowledge about the anatomic localization and density of corticofugal fibres in the internal capsule from the primary motor cortex, dorsal pre-motor areas, supplementary cortex and rostral cingulated cortex (26). The corticospinal projection found in primates has been shown to be densest in the lateral motor area (26). As a consequence, motor deficit severity was found to be increased as a lesion occupies a progressively posterior location of the internal capsule (26). These findings have been confirmed by high-angular resolution of diffusion-weighted imaging and probabilistic fibre tractography in humans (27).

Future studies should focus on the recovery of isolated hand and finger movements, acknowledging that individual selective

Table III. Associations between ischaemic lesion location and hand motor recovery, adjusted for lesion volume, one year after middle cerebral artery stroke

Location	Structure unaffected, poor dexterity (%)	Structure affected, poor dexterity (%)	Odds ratio	Probability of good recovery† (%)	95% CI	<i>p</i>
<i>Corticofugal tract affected (n = 55)</i>						
Motor cortex	10/23 (44)	15/32 (47)	2.53	51	0.71–8.99	0.15
Corona radiata	4/17 (24)	21/38 (55)	1.12	40	0.37–3.38	0.84
Internal capsule	2/21 (10)	23/34 (68)	2.90	20	1.09–7.76	0.04**
<i>Internal capsule</i>						
anterior limb	5/29 (17)	20/26 (77)	7.54	21	2.03–27.97	0.01**
genu/posterior limb	4/25 (16)	21/30 (70)	3.33	21	1.17–9.42	0.02**
<i>Combinations of affected structures of the corticofugal tract (n = 55)</i>						
Motor cortex and corona radiata	10/29 (35)	15/26 (58)	1.32	40	0.40–4.36	0.65
Corona radiata and internal capsule	2/21 (9)	23/34 (68)	2.90	20	1.09–7.76	0.03*
Motor cortex and internal capsule	12/40 (30)	13/15 (87)	12.19	13	2.19–67.95	0.01**

* $p < 0.05$, ** $p < 0.01$.

Poor dexterity: Fugl-Meyer Motor Assessment Scale Hand Score 0–3. Good dexterity: Fugl-Meyer Motor Assessment Scale Hand Score ≥ 3 .

†Probability of good recovery: probability of regaining hand function at one year post-stroke.

95% CI: 95% confidence interval.

muscle activation of the hand and, in particular, achieving voluntary extension of the fingers (6) are important for regaining a functional upper limb in everyday living (7, 19). This is why we used a more specific hand motor test, evaluating isolated hand movements rather than gross upper limb movements and synergy-dependent movements. In addition, we used an optimal cut-off of 3 points for the FM-HS. This cut-off was chosen on the basis of existing knowledge about the probability of regaining dexterity after stroke on the Action Research Arm Test (19). Moreover, patients showing 3 points or higher on the FM-HS are able to perform finger manoeuvres beyond a synergistic massed grasp with the hand.

Our study had several limitations. First, patients were included within the first week after admission to a stroke unit, implying some selection of patients in our study population. Second, we used conventional MRI scanning, whereas modern neuro-imaging techniques (e.g. diffusion weighted imaging) would have allowed more sensitive localization of the lesion. Lesions assessed with T2 changes on MRI may not accurately assess neuronal damage, because the lesion may be patchy and oedema may have contributed to T2 signal hyper-intensity (29). Third, we assessed lesion localization with axial brain slices using templates of the corticofugal tract. Modern techniques using integrated visualization of functional and anatomical brain images (3D scanning) could have allowed more precise detection of brain infarction. Fourth, slices were relatively thick at 6 mm. Therefore, we may have failed to notice substantial pertinent anatomical structures. In particular, lesioned structures of the different anatomical parts of the internal capsule require further investigation using more detailed MRI scanning. Fifth, lesion localization was defined using a neuroanatomical atlas and defining the corticofugal tract. Nowadays, one can use automated methods to determine the brain lesion size as well as its cytoarchitectonic regions (30). Sixth, we have not included patients with lacunar infarcts. For patients with lacunar infarcts, especially, the impact of lesion localization would have been clearer, since the effect of lesion volume would have been less. Seventh, the adjustments made for the confounder of lesion volume in the derived logistic regression equations are applicable only for those who also have positive scores for outcome and for involvement of location. With that, the number of degrees of freedom by lack of positive events may be violated (31). The low numbers of events, and with that adjustments made for correcting lesion volume, may be seen as a limitation in the present study. Finally, we were not able to assess the specific amount of physical and occupational therapy that each patient received. The amount of hand therapy might have influenced long-term motor hand function of the patients.

Future studies should focus on the predictive validity of location on MRI for the outcome of upper limb function. In particular, studies investigating the neuroanatomical integrity of different parts of the corticofugal fibres after stroke, for example by transcranial magnetic stimulation (28) or tensor diffusion imaging (27), as well as the time-dependent dynamics of cortical reorganization by functional MRI (28) should provide more information about the brain's ability to compensate for

functional loss after stroke by recruiting alternative neuronal networks. Rehabilitation treatment seeks to improve function by adaptation to impairments and activity limitations. A better understanding of the mechanisms of impairment and recovery will encourage the development of new treatments. These processes could be studied in the working human brain with modern non-invasive techniques such as functional MRI (28) and transcranial magnetic stimulation (28). New techniques such as diffusion tensor tractography for non-invasive mapping of corticofugal fibres from multiple motor areas relevant for stroke recovery (27, 32) might be able to evaluate the recovery mechanism of the brain after injury (33).

In conclusion, at one year post-stroke, lesions of the internal capsule, alone or in combination, are associated with a significantly lower probability of isolated hand motor function than lesions in the cortex, subcortex and corona radiata. Since recovery of isolated hand and finger movements is important for regaining a functional upper limb in everyday living, these patients should be identified early post-stroke in order to evaluate specific hand function training.

ACKNOWLEDGEMENTS

SK Schiemanck was supported by a grant from the Netherlands Organization for Health Research and Development (ZON/MW). The Scientific Foundation of Rehabilitation Center De Hoogstraat financially supported this project. We thank ThD Witkamp, MD, neuroradiologist, for his help in analysing the MRI scans.

REFERENCES

1. Crafton KR, Mark AN, Cramer SC. Improved understanding of cortical injury by incorporating measures of functional anatomy. *Brain* 2003; 126: 1650–1659.
2. Schiemanck SK, Kwakkel G, Post MW, Kappelle LJ, Prevo AJ. Predicting long-term independency in activities of daily living after middle cerebral artery stroke: does information from MRI have added predictive value compared with clinical information? *Stroke* 2006; 37: 1050–1054.
3. Schiemanck SK, Post MW, Kwakkel G, Witkamp TD, Kappelle LJ, Prevo AJ. Ischemic lesion volume correlates with long-term functional outcome and quality of life of middle cerebral artery stroke survivors. *Restor Neurol Neurosci* 2005; 23: 257–263.
4. Shelton FN, Reding MJ. Effect of lesion location on upper limb motor recovery after stroke. *Stroke* 2001; 32: 107–112.
5. Sanford J, Moreland J, Swanson LR, Stratford PW, Gowland C. Reliability of the Fugl-Meyer assessment for testing motor performance in patients following stroke. *Phys Ther* 1993; 73: 447–454.
6. Fritz SL, Light KE, Patterson TS, Behrman AL, Davis SB. Active finger extension predicts outcomes after constraint-induced movement therapy for individuals with hemiparesis after stroke. *Stroke* 2005; 36: 1172–1177.
7. Wenzelburger R, Kopper F, Frenzel A, Stolze H, Klebe S, Brossmann A, et al. Hand coordination following capsular stroke. *Brain* 2005; 128: 64–74.
8. Stroke – 1989. Recommendations on stroke prevention, diagnosis, and therapy. Report of the WHO Task Force on Stroke and other Cerebrovascular Disorders. *Stroke* 1989; 20: 1407–1431.
9. Bamford JM, Warlow CP. Evolution and testing of the lacunar hypothesis. *Stroke* 1988; 19: 1074–1082.

10. Fisher CM. Lacunar strokes and infarcts: a review. *Neurology* 1982; 32: 871–876.
11. Brott T, Adams Jr HP, Olinger CP, Marler JR, Barsan WG, Biller J, et al. Measurements of acute cerebral infarction: a clinical examination scale. *Stroke* 1989; 20: 864–870.
12. Rocca B, Martin C, Viviani X, Bidet PF, Saint-Gilles HL, Chevalier A. Comparison of four severity scores in patients with head trauma. *J Trauma* 1989; 29: 299–305.
13. Kasner SE, Chalela JA, Luciano JM, Cucchiara BL, Raps EC, McGarvey ML, et al. Reliability and validity of estimating the NIH stroke scale score from medical records. *Stroke* 1999; 30: 1534–1537.
14. Folstein MF, Folstein SE, McHugh PR. “Mini-mental State”. A practical method for grading the cognitive state of patients for the clinician. *J Psych Res* 1975; 12: 189–198.
15. Collen FM, Wade DT, Bradshaw CM. Mobility after stroke: reliability of measures of impairment and disability. *Int Disabil Stud* 1990; 12: 6–9.
16. Duarte E, Marco E, Muniesa JM, Belmonte R, Diaz P, Tejero M, et al. Trunk control test as a functional predictor in stroke patients. *J Rehabil Med* 2002; 34: 267–272.
17. Mahoney FI, Barthel DW. Functional evaluation: the Barthel Index. *Md State Med J* 1965; 14: 61–65.
18. van Swieten JC, Koudstaal PJ, Visser MC, Schouten HJ, van Gijn J. Interobserver agreement for the assessment of handicap in stroke patients. *Stroke* 1988; 19: 604–607.
19. Kwakkel G, Kollen BJ, van der GJ, Prevo AJ. Probability of regaining dexterity in the flaccid upper limb: impact of severity of paresis and time since onset in acute stroke. *Stroke* 2003; 34: 2181–2186.
20. Lyle RC. A performance test for assessment of upper limb function in physical rehabilitation treatment and research. *Int J Rehabil Res* 1981; 4: 483–492.
21. Kwakkel G, Kollen B, Lindeman E. Understanding the pattern of functional recovery after stroke: facts and theories. *Restor Neurol Neurosci* 2004; 22: 281–299.
22. Lang CE, Schieber MH. Reduced muscle selectivity during individuated finger movements in humans after damage to the motor cortex or corticospinal tract. *J Neurophysiol* 2004; 91: 1722–1733.
23. Matsui T, Hirano A. An atlas of the human brain for computerized tomography. Tokyo: Igaku-Shoin; 1978.
24. Pineiro R, Pendlebury ST, Smith S, Flitney D, Blamire AM, Styles P, et al. Relating MRI changes to motor deficit after ischemic stroke by segmentation of functional motor pathways. *Stroke* 2000; 31: 672–679.
25. Fries W, Danek A, Scheidtmann K, Hamburger C. Motor recovery following capsular stroke. Role of descending pathways from multiple motor areas. *Brain* 1993; 116: 369–382.
26. Morecraft RJ, Herrick JL, Stilwell-Morecraft KS, Louie JL, Schroeder CM, Ottenbacher JG, et al. Localization of arm representation in the corona radiata and internal capsule in the non-human primate. *Brain* 2002; 125: 176–198.
27. Newton JM, Ward NS, Parker GJ, Deichmann R, Alexander DC, Friston KJ, et al. Non-invasive mapping of corticofugal fibres from multiple motor areas – relevance to stroke recovery. *Brain* 2006; 129: 1844–1858.
28. Ward NS, Newton JM, Swayne OB, Lee L, Thompson AJ, Greenwood RJ, et al. Motor system activation after subcortical stroke depends on corticospinal system integrity. *Brain* 2006; 129: 809–819.
29. Pendlebury ST, Blamire AM, Lee MA, Styles P, Matthews PM. Axonal injury in the internal capsule correlates with motor impairment after stroke. *Stroke* 1999; 30: 956–962.
30. Makale M, Solomon J, Patronas NJ, Danek A, Butman JA, Grafman J. Quantification of brain lesions using interactive automated software. *Behav Res Methods Instrum Comput* 2002; 34: 6–18.
31. Peduzzi P, Concato J, Kemper E, Holford TR, Feinstein AR. A simulation study of the number of events per variable in logistic regression analysis. *J Clin Epidemiol* 1996; 49: 1373–1379.
32. Konishi J, Yamada K, Kizu O, Ito H, Sugimura K, Yoshikawa K, et al. MR tractography for the evaluation of functional recovery from lenticulostriate infarcts. *Neurology* 2005; 64: 108–113.
33. Tuch DS, Reese TG, Wiegell MR, Wedeen VJ. Diffusion MRI of complex neural architecture. *Neuron* 2003; 40: 885–895.