

## SHORT COMMUNICATION

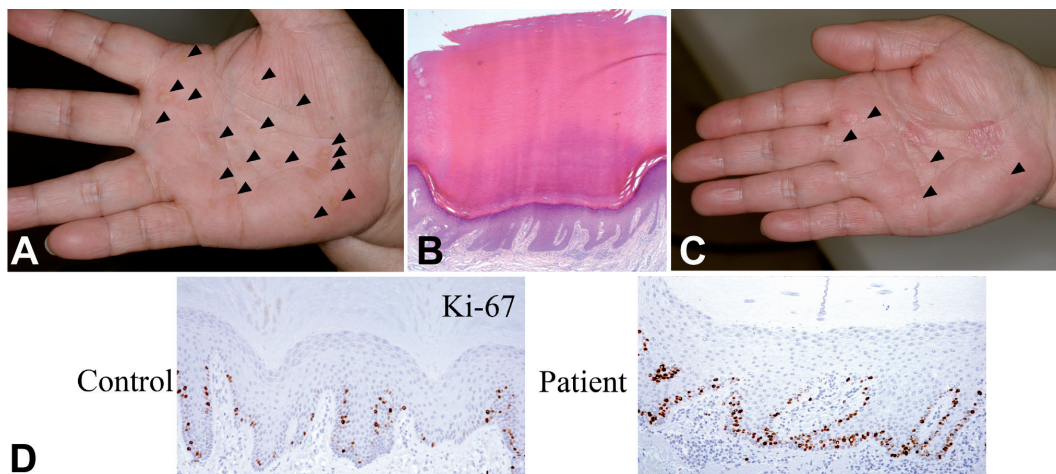
Punctate Palmoplantar Keratoderma Type 1: A Novel *AAGAB* Mutation and Efficacy of EtretinateToshifumi Nomura<sup>1</sup>, Akihiro Yoneta<sup>2</sup>, Elizabeth Pohler<sup>3</sup>, Shotaro Suzuki<sup>1</sup>, Rinko Osawa<sup>1</sup>, Osamu Mizuno<sup>1</sup>, Yuka Ohguchi<sup>1</sup>, Yukiko Nomura<sup>1</sup>, Toshiharu Yamashita<sup>2</sup>, W. H. Irwin McLean<sup>3</sup> and Hiroshi Shimizu<sup>1</sup>*Departments of Dermatology, <sup>1</sup>Hokkaido University Graduate School of Medicine, North 15 West 7, Kita-ku, Sapporo 060-8638, <sup>2</sup>Sapporo Medical University School of Medicine, Sapporo, Japan and <sup>3</sup>Centre for Dermatology and Genetic Medicine, College of Life Sciences and College of Medicine, Dentistry and Nursing, University of Dundee, Dundee, UK. E-mail: nomura@huhp.hokudai.ac.jp**Accepted Feb 26, 2014; Epub ahead of print Feb 27, 2014*

Punctate palmoplantar keratoderma type 1 (PPKP1, OMIM#148600), also known as the Buschke-Fischer-Brauer type, is a rare form of palmoplantar keratoderma that is autosomal dominantly inherited (1). PPKP1 is clinically characterised by multiple punctate hyperkeratotic papules affecting the palmar and plantar skin, with considerable phenotypic variation among patients (2). These circumscribed papules gradually coalesce and increase in number with age (2). The lesions typically start to appear in early adolescence but sometimes develop later in life. In 2012, linkage analysis and whole-exome sequencing identified heterozygous null mutations within *AAGAB* as a cause of PPKP1 (2, 3). *AAGAB* encodes  $\alpha$ - and  $\gamma$ -adaplin binding protein p34, which is involved in clathrin-mediated vesicle transport (2). Loss-of-function mutations in *AAGAB* result in haploinsufficiency of p34 (2). To date, 20 *AAGAB* null variants have been identified in Scottish, Irish, English, German, Tunisian, Chinese Mexican and Japanese populations (2–8). Here we report a Japanese case with PPKP1 carrying a novel *AAGAB* null mutation.

## CASE REPORT

An 80-year-old Japanese woman presented with numerous hyperkeratotic lesions on the palms and soles. They had gradually increased in number since the symptoms first emerged in the first

decade of life. She had a previous medical history of diabetes mellitus but was otherwise healthy. Physical examination showed hundreds of asymptomatic keratotic papules up to 5 mm in diameter on the palmoplantar regions (Fig. 1A). On the soles, the weight-bearing areas were mainly affected. Some of the papules were coalesced to form larger plaques. The patient had a family history of the disorder, with one of her 2 children also being affected. Histology of the papule sampled from the left palm showed hypergranulosis and hyperkeratosis with a well-defined central epidermal depression (Fig. 1B). Parakeratosis was not a feature. Immunohistochemical staining for Ki-67 showed continuous staining of the basal keratinocytes of the affected epidermis (Fig. 1C). Taken together, a diagnosis of PPKP1 was made. Mutation analysis of *AAGAB* was subsequently performed. In brief, genomic DNA of the patient was obtained from saliva using the Oragene DNA Self-Collection Kit (DNA Genotek, Kanata, ON, Canada) and all exons and exon-intron boundaries of *AAGAB* were amplified and sequenced as described previously (2). The patient gave written informed consent for mutation analysis in compliance with the Declaration of Helsinki Principles. This study was approved by the Medical Ethics Committee of the Hokkaido University Graduate School of Medicine. Mutation analysis of *AAGAB* revealed that the patient was heterozygous for a previously unreported frameshift mutation, c.174delC (Fig. S1<sup>1</sup>), in exon 2 of the gene. The 1-bp deletion results in a premature termination codon (PTC) at 51 amino acids downstream of the mutation (p.Asn59Ilefs\*51), presumably causing haploinsufficiency of *AAGAB*. This mutation was not detected in 50 ethnically matched control individuals.

<sup>1</sup><http://www.medicaljournals.se/acta/content/?doi=10.2340/00015555-1832>

**Fig. 1.** Numerous asymptomatic keratotic papules (arrowheads) on the palms (A). Hyperkeratosis and hypergranulosis with a well-defined central epidermal depression (H&E stain, original magnification  $\times 20$ ) (B). Significant decreases in the number of keratotic papules (arrowheads) and flattening of them were observed within a month after initiation of oral etretinate therapy (C). Immunohistochemical study shows a significant increase in the number of basal keratinocytes positive for Ki-67 in the patient's epidermis compared to control (anti-Ki-67 antibody, original magnification,  $\times 100$ ) (D).

Thus, the diagnosis of PPKP1 was further confirmed by genetic testing. Thirty mg/day of oral etretinate (Tigason®) dramatically reduced the number of keratotic papules in the patient within a month of initiation of therapy (Fig. 1C).

## DISCUSSION

In this study, we have identified a novel *AAGAB* null mutation. To our knowledge, this is the second PTC-causing mutation in *AAGAB* identified in the Japanese population. Thus, our results further support the recent discoveries which suggest that loss-of-function mutations in *AAGAB* cause PPKP1 (2–8). This study brings the total number *AAGAB* null variants to 21. However, previous studies have identified no genotype-phenotype correlations. Moreover, patients with PPKP1 have been reported to show diverse phenotypic severity, even when they carry a same PTC-causing mutation (2). The phenotypes differ among patients in the age of onset and in the severity of the palmoplantar skin lesions. Aging and environmental factors could play greater roles in determining the disease severity than could the context of the *AAGAB* mutation carried by patients. Indeed, the lesions have gradually increased in number with age in the present case.

The pathomechanism of PPKP1 has not been fully elucidated. In this study, we performed immunohistochemical staining for Ki-67 of the palmar skin of the patient and a control individual, and it showed a significant increase in the number of basal keratinocytes positively stained for the proliferation marker in the patient (Fig. 1D). These data are consistent with the results previously reported by Pohler et al. (2) and Kiritsi et al. (7) and further indicate that the hyperkeratosis seen in PPKP1 is a hyperproliferative hyperkeratosis rather than a retention hyperkeratosis.

Although our patient has not developed any malignancies, there are several reports of malignancy occurring in association with PPKP1 (9), suggesting a causal link between malignancy and *AAGAB* mutations. However, further investigations using a larger case series are warranted to confirm this finding.

$\alpha$ - and  $\gamma$ -adaptin binding protein p34 is involved in clathrin-mediated pathway that plays a crucial role in the endocytosis and recycling of receptor tyrosine kinases (RTKs) (10). Notably, almost complete knockdown of *AAGAB* in HaCaT cells was shown to result in markedly increased expression of epidermal growth factor receptor (EGFR) and Axl which are RTKs highly expressed in the skin (2, 5). Therefore, *AAGAB* null mutations may increase the half-life of several RTKs in basal keratinocytes via impaired clathrin-dependent pathways, leading to a hyperproliferation hyperkeratosis. In contrast, Kiritsi et al. (7) reported that primary keratinocytes derived from a PPKP1 patient harbouring the heterozygous splice-site mutation c.870+1G>A showed no significant increase in expression of EGFR nor of phosphorylated EGFR compared with primary normal human keratinocytes, and those authors speculated that haploinsufficiency of

p34, i.e. an approximately 50% reduction in p34, may be insufficient to cause EGFR overexpression. Further studies are warranted to clarify the pathogenesis of PPKP1.

Therapeutic options for PPKP1 are currently limited, but it is of note that oral etretinate effectively resolved the lesions in our case. As there are only a few case reports that show the efficacy of etretinate or acitretin in treating PPKP1 (11), this study gives further evidence that systemic retinoids are effective against this intractable disease.

## ACKNOWLEDGEMENTS

This work was supported by Grants-in-Aid for Young Scientists (B) 25860925 (T. Nomura) and (B) 24791130 (R. Osawa), both from the Japan Society for the Promotion of Science. The Centre for Dermatology and Genetic Medicine was supported by grants from The Wellcome Trust (092530/Z/10/Z and 098439/Z/12/Z).

*The authors declare no conflicts of interest.*

## REFERENCES

1. Itin PH, Fistarol SK. Palmoplantar keratoderms. *Clin Dermatol* 2005; 23: 15–22.
2. Pohler E, Mamai O, Hirst J, Zamiri M, Horn H, Nomura T, et al. Haploinsufficiency for *AAGAB* causes clinically heterozygous forms of palmoplantar keratoderma. *Nat Genet* 2012; 44: 1272–1276.
3. Giehl KA, Eckstein GN, Pasternack SM, Praetzel-Wunder S, Ruzicka T, Lichtner P, et al. Nonsense mutations in *AAGAB* cause punctate palmoplantar keratoderma type Buschke-Fisher-Brauer. *Am J Hum Genet* 2012; 91: 754–759.
4. Li M, Yang L, Shi H, Guo B, Dai X, Yao Z, et al. Loss-of-function mutation in *AAGAB* in Chinese families with punctate palmoplantar keratoderma. *Br J Dermatol* 2013; 169: 168–171.
5. Pohler E, Zamiri M, Harkins CP, Salas-Alanis JC, Perkins W, Smith FJ, et al. Heterozygous mutations in *AAGAB* cause type 1 punctate palmoplantar keratoderma with evidence for increased growth factor signaling. *J Invest Dermatol* 2013; 133: 2805–2808.
6. Cui H, Gao M, Wang W, Xiao R, Chen G, Zhang Q, et al. Six mutations in *AAGAB* confirm its pathogenic role in Chinese punctate palmoplantar keratoderma patients. *J Invest Dermatol* 2013; 133: 2631–2634.
7. Kiritsi D, Chmel N, Arnold AW, Jakob T, Bruckner-Tuderman L, Has C. Novel and recurrent *AAGAB* mutations: clinical variability and molecular consequences. *J Invest Dermatol* 2013; 133: 2483–2486.
8. Li M, Dai X, Cheng R, Yang L, Yao Z, Liu J. A novel 5-bp deletion mutation in *AAGAB* gene in a Chinese family with punctate palmoplantar keratoderma. *Acta Derm Venereol* 2014; 94: 339–340.
9. Stevens HP, Kelsell DP, Leigh IM, Ostlere LS, MacDermot KD, Rustin MHA. Punctate palmoplantar keratoderma and malignancy in a four-generation family. *Br J Dermatol* 1996; 134: 720–726.
10. Sigismund S, Argenzio E, Tosoni D, Cavallaro E, Polo S, Di Fiore PP. Clathrin-mediated internalization is essential for sustained EGFR signaling but dispensable for degradation. *Dev Cell* 2008; 15: 209–219.
11. Erkek E, Erdogan S, Tuncez F, Kurtipek GS, Bagci Y, Ozoguz P, et al. Type 1 hereditary punctate keratoderma associated with widespread lentigo simplex and successfully treated with low-dose oral acitretin. *Arch Dermatol* 2006; 142: 1076–1077.