

SHORT COMMUNICATION

Successful Treatment of Multicentric Reticulohistiocytosis with Adalimumab, Prednisolone and Methotrexate

Sei-ichiro Motegi¹, Yukio Yonemoto², Shinya Yanagisawa², Sayaka Toki¹, Akihiko Uchiyama¹, Kazuya Yamada¹ and Osamu Ishikawa¹Departments of ¹Dermatology, and ²Orthopaedic Surgery, Gunma University Graduate School of Medicine, 3-39-22 Showa, Maebashi, Gunma 371-8511, Japan. E-mail: smotegi@gunma-u.ac.jp

Accepted Jun 11, 2015; Epub ahead of print Jun 15, 2015

Multicentric reticulohistiocytosis (MRH) is a rare systemic disorder belonging to non-Langerhans cell histiocytosis, which is characterized by severe destructive arthritis and multiple skin nodules. It is thought that proinflammatory cytokines, such as tumour necrosis factor- α (TNF- α), interleukin 1 β (IL-1 β), IL-6 and IL-12 secreted by monocytes and macrophages, may be associated with the pathogenesis of skin lesions and destructive arthritis in MRH, and that the inhibition of these cytokines may be useful for therapy (1, 2). There are several case reports of successful or unsuccessful treatments using anti-TNF- α reagents, such as infliximab (3–6), etanercept (7–9) and adalimumab (10, 11). We report here a case of MRH that was resistant to combination therapy of prednisolone, methotrexate (MTX) and golimumab (another anti-TNF- α drug administered subcutaneously every 4 weeks), but finally responded to prednisolone, MTX and adalimumab.

CASE REPORT

A 54-year-old Japanese woman visited our hospital in August 2002, presenting with multiple nodules on her hands and fingers. She had noticed nodules on her index finger in 1998, and

multiple firm, pale-reddish papules and subcutaneous nodules gradually appeared on the dorsal aspect of both hands, forearms, upper arms, toes, face and scalp. She developed severe arthralgia in the fingers, wrist, shoulder and knee joints. The patient's family and past history were unremarkable. Routine laboratory tests, including blood cell counts and C-reactive protein levels, were within the normal ranges. Antinuclear antibody and rheumatoid factor were negative. Serum matrix metalloproteinase-3 level was elevated (159.2 ng/ml, normal 17.3–59.7 ng/ml). Serum IL-6 level was within the normal limit. Histological examination of the nodules on her finger revealed multinucleated giant cells throughout the dermis, containing eosinophilic and fine granular ground-glass cytoplasm. Plane X-ray of the hands revealed progressive erosions with pencil-in-cup deformities, spur formations and subluxations of the distal and proximal interphalangeal joints and metacarpal phalangeal joints of all fingers (Fig. 1C, D). Computed tomography of the whole body and fluorodeoxyglucose-positron emission tomography (FDG-PET) scan revealed no internal malignancies. Based on these findings, a diagnosis of MRH was established. Treatment with oral prednisolone was started in October 2002 (maximum dose 30 mg/day). Since the skin and joint lesions did not improve, the prednisolone dose was tapered to 5–10 mg/day. Treatment with oral MTX (4–6 mg/week) was started in July 2006; however, the number and size of multiple nodules increased. Golimumab (50 mg), a human monoclonal antibody to TNF- α , was administered subcutaneously every 4 weeks beginning in March 2013 with continuation of prednisolone

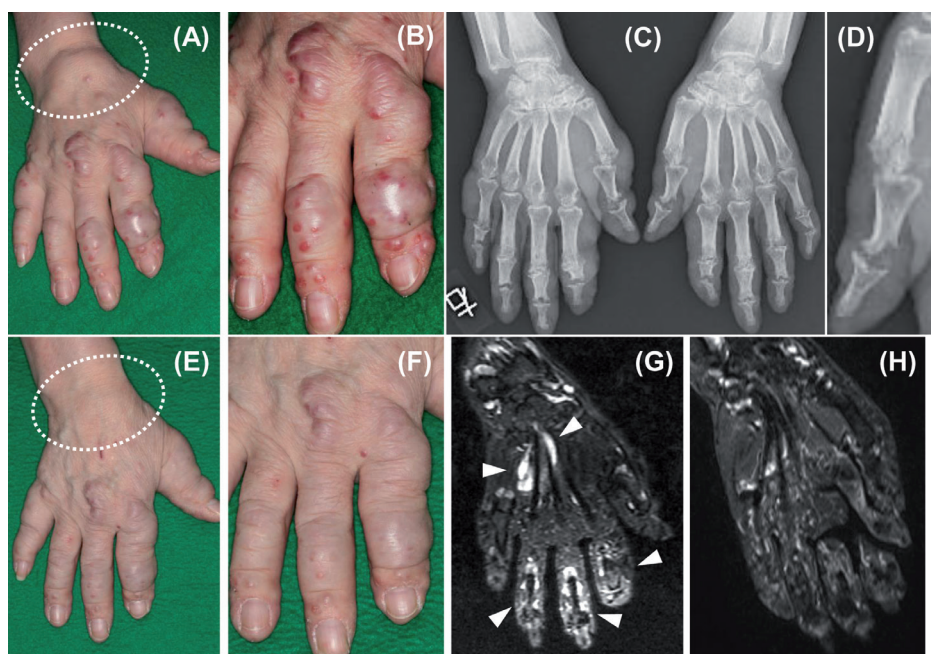


Fig. 1. (A, B, E, F) Clinical photographs of the right hand. (A, B) Before treatment with adalimumab. Multiple papules and subcutaneous nodules are visible on all fingers, and swelling of the right wrist (dotted circle). (E, F) Ten months after starting adalimumab. Multiple nodules of fingers significantly decreased, and swelling of the right wrist disappeared. (C, D, G, H) Imaging of the hands. (C, D) Plane X-ray of the hands. Progressive erosions with pencil-in-cup deformities, spur formations and subluxations of the distal and proximal interphalangeal joints and metacarpal phalangeal joints of all fingers (D: High magnification image of bones in left thumb). (G, H) Magnetic resonance (MRI) with short-tau inversion recovery (STIR) of the right hand. (G) Before treatment with adalimumab. High signal intensities in tendons of the flexor palmar and digital muscles. (H) Ten months after starting adalimumab. High signal intensities in the tendons of the flexor palmar and digital muscles had disappeared.

and MTX. Although the combination therapy was continued for 12 months, the number and size of multiple cutaneous and subcutaneous nodules on all fingers increased, arthralgia was exacerbated, and swelling of the right wrist developed (Fig. 1A, B). Magnetic resonance imaging (MRI) with short-tau inversion recovery (STIR) of the right hand revealed high signal intensities in the tendons of the flexor palmar and digital muscles (Fig. 1G). Golimumab was therefore replaced with adalimumab (40 mg every other week) with continuation of prednisolone (6 mg/day) and MTX (6 mg/week) in February 2014. Twelve weeks later, the multiple skin lesions gradually improved. Ten months after starting adalimumab therapy, the number and size of multiple nodules in the fingers decreased significantly, and the swelling of the right wrist and severe pain disappeared (Fig. 1E, F). In addition, the high signal intensities in the tendons of the flexor palmar and digital muscles, previously observed on MRI with STIR, in the right hand disappeared (Fig. 1H). Since the skin lesions have not completely remitted, we plan to continue the present combination therapy.

DISCUSSION

The pathogenesis of MRH remains unknown. Immunohistochemical analyses demonstrated the presence of histiocytes of a monocyte-macrophage origin and high levels of expression of proinflammatory cytokines, such as TNF- α , IL-1 β and IL-6, in local lesions (1). In addition, Bennassar et al. (2) reported elevated serum TNF- α , IL-1 β and IL-6 levels were in a patient with MRH, that decreased after treatment with prednisolone and MTX, along with an improvement in symptoms. These findings suggest that the production of these proinflammatory cytokines by histiocytes might be involved in the pathogenesis of MRH.

Various treatments have been reported, including non-steroidal anti-inflammatory agents, prednisolone, isoniazid, MTX, cyclosporine, cyclophosphamide, alendronate and minocycline, alone or in combination (3, 12). In addition, sun-protective clothing and sunscreens are recommended to prevent the development of skin eruptions, via the ultraviolet light-induced Köbner phenomenon (13). To the best of our knowledge, there are currently 10 reported cases of MRH that have been treated with anti-TNF agents, such as infliximab (3–6), etanercept (7–9) and adalimumab (10, 11), but the clinical outcome is controversial. Shannon et al. (10) reported an improvement in joint lesions after combination therapy with adalimumab (40 mg every other week), prednisolone, cyclosporine and mycophenolate mofetil. Yeter and Arkfeld (11) reported that skin lesions were improved by treatment with MTX and etanercept, but joint lesions were not; however switching to adalimumab in place of etanercept and adding minocycline resulted in a sustained improvement in both the skin

and joint symptoms. In the current case, replacement of golimumab with adalimumab (in combination with prednisolone and MTX) resulted in a significant improvement in both skin and joint symptoms, suggesting that adalimumab could be a treatment of choice for MRH. Since both golimumab and adalimumab are human monoclonal antibodies to TNF- α , the reason for their discrepant efficacy in MRH is unknown.

The authors declare no conflicts of interest.

REFERENCES

- Gorman JD, Danning C, Schumacher HR, Klippel JH, Davis JC Jr. Multicentric reticulohistiocytosis: case report with immunohistochemical analysis and literature review. *Arthritis Rheum* 2000; 43: 930–938.
- Bennassar A, Mas A, Guilbert A, Julià M, Mascaró-Galy JM, Herrero C. Multicentric reticulohistiocytosis with elevated cytokine serum levels. *J Dermatol* 2011; 38: 905–910.
- Macía-Villa CC, Zea-Mendoza A. Multicentric reticulohistiocytosis: case report with response to infliximab and review of treatment options. *Clin Rheumatol* 2014 Apr 15. [Epub ahead of print]
- Sellam J, Deslandre CJ, Dubreuil F, Arfi S, Kahan A. Refractory multicentric reticulohistiocytosis treated by infliximab: two cases. *Clin Exp Rheumatol* 2005; 23: 97–99.
- Lee MW, Lee EY, Jeong YI, Choi JH, Moon KC, Koh JK. Successful treatment of multicentric reticulohistiocytosis with a combination of infliximab, prednisolone and methotrexate. *Acta Derm Venereol* 2004; 84: 478–479.
- Kalajian AH, Callen JP. Multicentric reticulohistiocytosis successfully treated with infliximab: an illustrative case and evaluation of cytokine expression supporting anti-tumor necrosis factor therapy. *Arch Dermatol* 2008; 144: 1360–1366.
- Lovelace K, Loyd A, Adelson D, Crowson N, Taylor JR, Cornelison R. Etanercept and the treatment of multicentric reticulohistiocytosis. *Arch Dermatol* 2005; 141: 1167–1168.
- Matejicka C, Morgan GJ, Schlegelmilch JG. Multicentric reticulohistiocytosis treated successfully with an anti-tumor necrosis factor agent: comment on the article by Gorman et al. *Arthritis Rheum* 2003; 48: 864–866.
- Kovach BT, Calamia KT, Walsh JS, Ginsburg WW. Treatment of multicentric reticulohistiocytosis with etanercept. *Arch Dermatol* 2004; 140: 919–921.
- Shannon SE, Schumacher HR, Self S, Brown AN. Multicentric reticulohistiocytosis responding to tumor necrosis factor-alpha inhibition in a renal transplant patient. *J Rheumatol* 2005; 32: 565–567.
- Yeter KC, Arkfeld DG. Treatment of multicentric reticulohistiocytosis with adalimumab, minocycline, methotrexate. *Int J Rheum Dis* 2013; 16: 105–106.
- Satoh M, Oyama N, Yamada H, Nakamura K, Kaneko F. Treatment trial of multicentric reticulohistiocytosis with a combination of prednisolone, methotrexate and alendronate. *J Dermatol* 2008; 35: 168–171.
- Taniguchi T, Asano Y, Okada A, Sugaya M, Sato S. Ultraviolet light-induced Köbner phenomenon contributes to the development of skin eruptions in multicentric reticulohistiocytosis. *Acta Derm Venereol* 2011; 91: 160–163.