

CLINICAL REPORT

Levocetirizine for Treatment of Immediate and Delayed Mosquito Bite Reactions

Ari KARPPINEN¹, Henriikki BRUMMER-KORVENKONTIO², Leena PETMAN³, Hannu KAUTIAINEN⁴, Jean-Pierre HERVÉ⁵ and Timo REUNALA^{1,3}

¹Department of Dermatology, University and University Hospital of Tampere, Tampere, ²National Institute of Public Health, Helsinki, ³University Hospital for Skin and Allergic Diseases, Helsinki, ⁴Rheumatism Foundation Hospital, Heinola, Finland, and ⁵Institut de Recherche pour le Développement, Laboratoire de Lutte contre les Insectes Nuisibles, Montpellier, France

People frequently experience whealing and delayed papules from mosquito bites. Various antihistamines have previously been tried for the treatment of this condition. We performed a double-blind, placebo-controlled, cross-over study with levocetirizine 5 mg and matched placebo in 30 adults who were sensitive to mosquito bites. On the third treatment day the subjects received two *Aedes aegypti* bites on the forearm. The size of the bite lesions and the intensity of pruritus (visual analogue scale) were measured. Bite symptoms could be analysed in 28 subjects at 15 min and in 8 subjects at 24 h. Levocetirizine decreased the size of wheals by 60% ($p < 0.001$) and accompanying pruritus by 62% ($p < 0.001$) compared with placebo. The effect of levocetirizine increased in a linear fashion with the size of wheals and was most significant in the subjects with largest bite lesions. Levocetirizine also decreased the size of 24-h bite lesions by 71% ($p = 0.008$) and accompanying pruritus by 56% ($p = 0.016$). These results show that prophylactic levocetirizine 5 mg is an effective treatment for both immediate and delayed mosquito bite symptoms and is especially effective in subjects with large wheals. Key words: mosquito allergy; antihistamine; levocetirizine; wheal; delayed bite lesion; pruritus.

(Accepted January 10, 2006)

Acta Derm Venereol 2006; 86: 329–331.

Timo Reunala, Department of Dermatology, Tampere University Hospital, PO Box 2000 FIN-33521 Tampere, Finland. E-mail: timo.reunala@uta.fi

Sensitization to mosquito bites occurs commonly in childhood, and bite reactivity often persists for years (1). In heavily exposed areas, such as Nordic countries in Europe, Canada and Japan, most subjects have IgE anti-saliva antibodies and react to the bites of *Aedes* mosquitoes (2–4). The most common bite reactions are immediate wheals and delayed bite papules, but systemic reactions may also occur (5). Repellents are widely used against mosquitoes, and sensitive persons can also take oral antihistamines to minimize cutaneous reactions (6). Previously, cetirizine and ebastine have been shown to

decrease whealing and accompanying pruritus in placebo-controlled trials (7–9). Levocetirizine, whose affinity to H1-receptors is two-fold higher than that of cetirizine, is known to give good control of symptoms in allergic rhinitis and chronic urticaria (10, 11).

In the present study we examined the effect of levocetirizine against immediate and delayed mosquito bite reactions.

MATERIALS AND METHODS

Patients

Thirty mosquito bite sensitive adults (27 women, 3 men; mean age 37.5 years, age range 19–64 years) volunteered for the study. The majority was physicians, nurses or other staff of the Tampere and Helsinki University Hospitals. All subjects had experienced harmful mosquito bite reactions in the field and at inclusion they all showed at least 5-mm diameter wheal from the bite of *Aedes aegypti* laboratory mosquito. Nine subjects had a history of atopic dermatitis, allergic rhinitis or asthma.

The study was approved by the Ethics Committees of the Tampere University Hospital, and informed consent was obtained from all subjects.

Levocetirizine administration and mosquito exposure

The study was performed in a double-blind, cross-over manner with levocetirizine 5 mg and placebo capsules made and randomized in the pharmacy of Helsinki University. Each drug was taken daily at 08.00 a.m. for 4 days followed by 3 days without any drugs. The bite exposure was performed with *A. aegypti* laboratory mosquitoes in both drug periods between 12.00 a.m. and 15.00 a.m. on day 3. Two mosquitoes in a cage were allowed to feed on the forearm. The size of the bite reactions were measured at 15 min and 24 h, as previously described (9). Pruritus was evaluated using a 100-mm visual analogue scale (VAS) ranging from 0 (no pruritus) to 100 (very intense pruritus). All adverse events were recorded during the study.

Comparison between levocetirizine and placebo was made using Wilcoxon's signed rank test with Hommel's adjusted p -value (12).

RESULTS

Twenty-nine subjects completed the study according to the protocol. One subject dropped out in the first drug period due to respiratory infection. Another subject was

excluded from the analysis due to very small wheals (<5 mm diameter) when on placebo treatment. As a result, 28 subjects were analysed for delayed symptoms the 15 min bite lesions and 8 subjects, all of whom had >5 mm diameter, in the 24 h bite lesions.

Levocetirizine 5 mg significantly decreased ($p < 0.001$) the size of 15 min wheals and the accompanying pruritus compared with placebo (Fig. 1). The median wheal size was reduced by 60%, from 68 mm² (25% quartiles 34 and 104 mm²) in the placebo to 27 mm² (20, 40) in the levocetirizine group. Twenty-four subjects (86%) showed a decrease in the size of wheals. Levocetirizine effect increased in a linear fashion ($r = -0.91$; 95% confidence interval (CI) from -0.96 to -0.82) and was most significant in subjects with large wheals (Fig. 2).

Levocetirizine reduced accompanying pruritus at 15 min by 62% and median VAS scores were 8 (25% quartiles 7 and 9) in the placebo and 3 (1, 5) in the levocetirizine group (Fig. 1). The effect on pruritus was

seen in 27 (96%) of the levocetirizine-treated subjects, but this effect showed no correlation with severity of pruritus (data not shown).

In the 8 subjects with delayed bite lesions, levocetirizine 5 mg decreased the size of the 24 h bite lesions by 71%. Median size was 240 mm² (range 28–690 mm²) in the placebo and 71 mm² (range 0–460 mm²) in the levocetirizine treatment group ($p = 0.008$). Accompanying pruritus was reduced by 56% and the mean VAS score was 4.75 (range 2–8) in the placebo and 2.0 (range 0–6) in the levocetirizine group ($p = 0.016$).

There was no significant difference in adverse effects between the two treatment groups. Five subjects on levocetirizine and two on placebo experienced mild (6 subjects) to moderate (1 subject) somnolence.

DISCUSSION

This placebo-controlled, cross-over study in 28 mosquito bite sensitive adult subjects showed that prophylactic levocetirizine 5 mg had a significant effect on the immediate wheals and the accompanying pruritus caused by *A. aegypti* laboratory mosquitoes. Symptoms were reduced by 60%, which is in good agreement with the results found with cetirizine 10 mg and ebastine 10 mg in our previous study (9). The marked effect of these potent antihistamines is not unexpected, since whealing from mosquito bites is a type I allergic reaction mediated by IgE anti-saliva antibodies and histamine (13). An interesting finding in the present study was the observation that the effect of levocetirizine increased in a linear fashion with the size of wheals and was most significant in the subjects with largest lesions. Our previous study (12) with cetirizine, ebastine and loratadine did not show such a clearly defined trend and we are not aware of any previous reports showing this kind of linearly increasing effect of levocetirizine on the IgE-mediated response, either in the skin or nasal mucosa.

Many mosquito bite sensitive subjects develop disturbing delayed bite papules, especially at the onset of mosquito season, which appear 4–6 h after the bites and may persist for several days (1). In this study 8 subjects had large 24 h bite lesions and levocetirizine significantly decreased their size and the intensity of accompanying pruritus. Our previous study in the field with cetirizine 10 mg showed similar effects, whereas a trial with laboratory mosquitoes failed to produce sufficient data for detailed analysis (7, 9). When the delayed mosquito bite lesions develop, a strong influx of eosinophils is seen at 2 h and that of lymphocytes at 24 h (14). Whether levocetirizine affects the trafficking of eosinophils by reducing the release of eotaxin and other mediators similarly to the action reported for cetirizine (15, 16), needs to be confirmed in further mosquito bite studies.

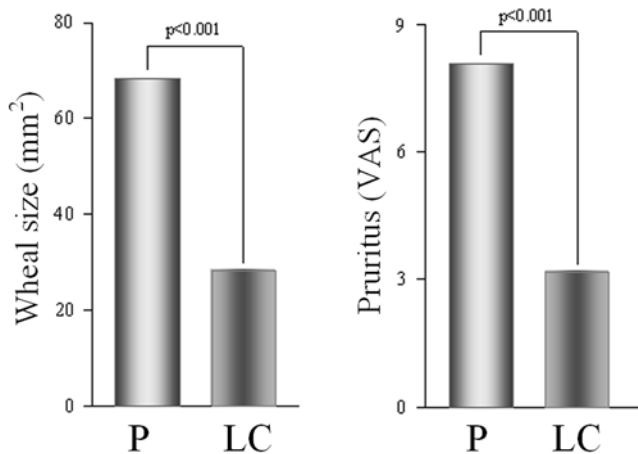


Fig. 1. Wheal size (left) and accompanying pruritus (right) in 28 mosquito-bite sensitive subjects treated with levocetirizine (LC) 5 mg and placebo (P). VAS = visual analogue scale, in cm.

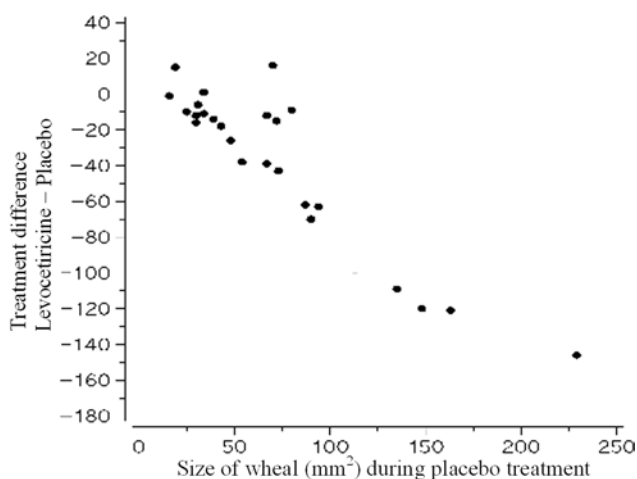


Fig. 2. Treatment difference between levocetirizine 5 mg and placebo in mm² compared with the size of the wheal in placebo treatment in 28 mosquito-bite sensitive subjects.

In practice, the relief of itching, which was observed in almost every subject in the present study is the most important finding. Mosquito bite sensitive subjects often suffer from bites throughout the mosquito season (17). A 60% decrease in immediate, and especially in delayed, itching is of great help. Decrease in itching reduces scratching, which in turn diminishes the risk of erosions and secondary bacterial infections. Somnolence is also of clinical importance when considering the effects of second-generation antihistamines (18). In the present study, a few subjects experienced somnolence, but there was no significant difference between the levocetirizine and placebo groups, a finding that is in agreement with a study performed in chronic urticaria (11).

In conclusion, the present placebo-controlled study performed in adult mosquito bite sensitive subjects showed that prophylactic levocetirizine 5 mg is an effective and well-tolerated drug in the treatment of both immediate and delayed mosquito bite symptoms.

ACKNOWLEDGEMENTS

We thank Mrs Pirkko Burri for her help in rearing mosquitoes and all volunteers from our staff for participating in the study. This study was supported by a grant from the Tampere University Hospital Research Fund.

There were no conflicts of interest in performing this study.

REFERENCES

1. Reunala T, Brummer-Korvenkontio H, Palosuo T. Are we really allergic to mosquito bites? *Ann Med* 1994; 26: 301–306.
2. Konishi E. Distribution of immunoglobulin G and E antibody levels to salivary gland extracts of *Aedes albopictus* (Diptera: Culicidae) in several age groups of a Japanese population. *J Med Entomol* 1990; 27: 519–522.
3. Reunala T, Brummer-Korvenkontio H, Palosuo K, Miyanji M, Ruiz-Maldonado R, Löve A, et al. Frequent occurrence of IgE and IgG4 antibodies against saliva of *Aedes communis* and *Aedes aegypti* mosquitoes in children. *Int Arch Allergy Immunol* 1994; 104: 366–371.
4. Peng Z, Simons FE. Cross-reactivity of skin and serum specific IgE responses and allergen analysis for three mosquito species with worldwide distribution. *J All Clin Immunol* 1997; 100: 192–198.
5. Peng Z, Beckett AN, Engler RJ, Hoffman DR, Ott NL, Simons FER. Immune responses to mosquito saliva in 14 individuals with acute systemic allergic reactions to mosquito bites. *J Allergy Clin Immunol* 2004; 114: 1189–1194.
6. Fradin MS. Mosquitoes and mosquito repellents: a clinician's guide. *Ann Intern Med* 1998; 128: 931–940.
7. Reunala T, Brummer-Korvenkontio H, Karppinen A, Coulie P, Palosuo T. Treatment of mosquito bites with cetirizine. *Clin Exp Allergy* 1993; 23: 72–75.
8. Karppinen A, Petman L, Jekunen A, Kautiainen H, Vaalasti A, Reunala T. Treatment of mosquito bites with ebastine: a field trial. *Acta Derm Venereol* 2000; 80: 114–116.
9. Karppinen A, Kautiainen H, Petman L, Burri P, Reunala T. Comparison of cetirizine, ebastine and loratadine in the treatment of immediate mosquito-bite allergy. *Allergy* 2002; 57: 534–537.
10. Bachert C, Bousquet J, Canonica GW, Durham SR, Klimek L, Mullol J, et al. Levocetirizine improves quality of life and reduces costs in long-term management of persistent allergic rhinitis. *J Allergy Clin Immunol* 2004; 114: 838–844.
11. Kapp A, Wedi B. Chronic urticaria: clinical aspects and focus on a new antihistamine, levocetirizine. *J Drugs Dermatol* 2004; 3: 632–639.
12. Hommel G. A stagewise rejective multiple test procedure based on modified Bonferroni test. *Biometrika* 1988; 75: 383–386.
13. Horsmanheimo L, Harvima IT, Harvima RJ, Brummer-Korvenkontio H, Francois G, Reunala T. Histamine and leukotriene C4 release in cutaneous mosquito bite reactions. *J Allergy Clin Immunol* 1996; 98: 408–411.
14. Karppinen A, Rantala I, Vaalasti A, Palosuo T, Reunala T. Effect of cetirizine on the inflammatory cells in mosquito bites. *Clin Exp Allergy* 1996; 26: 703–709.
15. Thompson L, Blaylock MG, Sexton DW, Campbell A, Walsh GM. Cetirizine and levocetirizine inhibit eotaxin-induced eosinophil transendothelial migration through human dermal or lung microvascular endothelial cells. *Clin Exp Allergy* 2002; 32: 1187–1192.
16. Menzies-Gow A, Ying S, Phipps S, Kay AB. Interactions between eotaxin, histamine and mast cells in early microvascular events associated with eosinophil recruitment to the site of allergic skin reactions in humans. *Clin Exp Allergy* 2004; 34: 1276–1282.
17. Palosuo K, Brummer-Korvenkontio H, Mikkola J, Sahi T, Reunala T. Seasonal increase in human IgE and IgG4 antisaliva antibodies to *Aedes* mosquito bites. *Int Arch Allergy Immunol* 1997; 114: 367–372.
18. Mann RD, Pearce GL, Dunn N, Shakir S. Somnolence with 'non-sedating' antihistamines: four prescription-event monitoring studies in general practice. *BMJ* 2000; 320: 1184–1187.