

## Renal Failure Associated with Blue Toe Syndrome: Effective Treatment with Intravenous Prostaglandin E-1

Kazuya Minatohara

Department of Dermatology, Toride Kyodo General Hospital, 2-1-1, Hongo Toride-City, Ibaraki-Prefecture 302-0022, Japan. E-mail; wabain@yahoo.co.jp  
Accepted January 12, 2006.

Sir,

Blue toe syndrome is caused by any one of several disorders, including cardiac embolism, hyperviscosity syndrome, hypercoagulable states, and vasculitis. Cholesterol crystal embolism (CCE) is known to be another major cause of this syndrome, which is associated with pain and a bluish discoloration of the toes (1). Its course is limited to the lower limbs and appears relatively benign, but a disseminated cholesterol embolism is a life-threatening condition (2). Renal failure is the most common fatal complication of CCE. We report here a case of blue toe syndrome associated with a CCE together with severe renal dysfunction, which was successfully treated with prostaglandin E-1 (PGE-1).

### CASE REPORT

A 77-year-old man was referred to our department with a 1-month history of painful small ulcers bilaterally on the fifth toe and livedo reticularis, fishnet-like erythema on the toes (Fig. 1) and soles. He had ischaemic heart failure and underwent percutaneous transluminal coronary angioplasty (PTCA) in April 2005. Both his toes became mottled purple of livedo reticularis, accompanied by pain. Blood urea nitrogen (BUN)

subsequently increased to 15.0  $\mu\text{mol/l}$  and serum creatinine to 274.0  $\mu\text{mol/l}$  over the normal values within 2 months after PTCA.

Among the laboratory tests conducted in June, the results of an analysis of anti-phospholipid antibodies, pro-thrombin time, and activated partial thromboplastin were normal. Tests for antinuclear antibody, cryoglobulin, and anti-neutrophil cytoplasmic antibody produced negative results. The ankle-brachial pressure index was normal. Echocardiography did not reveal a cardiac source of embolism. Thoraco-abdominal computed tomography showed an irregular aorta with no aneurysm. An excision biopsy of the right fifth toe obtained from the area of a purplish erythema showed a cholesterol crystal cleft within the lumen of a small artery (Fig. 2). A renal biopsy was not performed. Based on these histological findings and on the clinical features, a diagnosis of CCE was made.

In July, BUN and creatinine levels rose to 18.9  $\mu\text{mol/l}$  and 415.5  $\mu\text{mol/l}$ , respectively. Treatment with an intravenous infusion of PGE-1, 10  $\mu\text{g/day}$  given every other day, was initiated. BUN and creatinine levels fell to 13.2  $\mu\text{mol/l}$  and 335.9  $\mu\text{mol/l}$ , respectively, after a period of 2 months. Renal failure did not progress to a level that would have required haemodialysis; livedo reticularis was eliminated; and the ulcers on both fifth toes healed. The PGE-1 treatment is currently maintained.

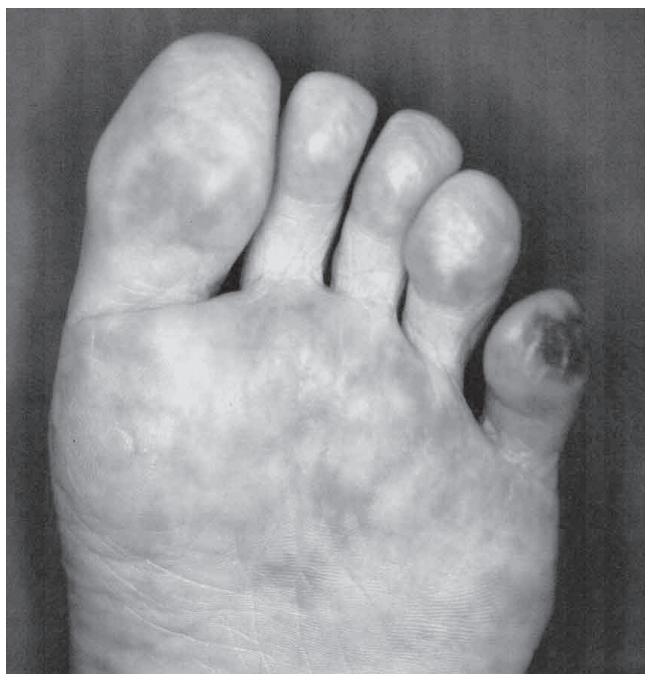


Fig. 1. Ulcer and livedo reticularis on the toes.

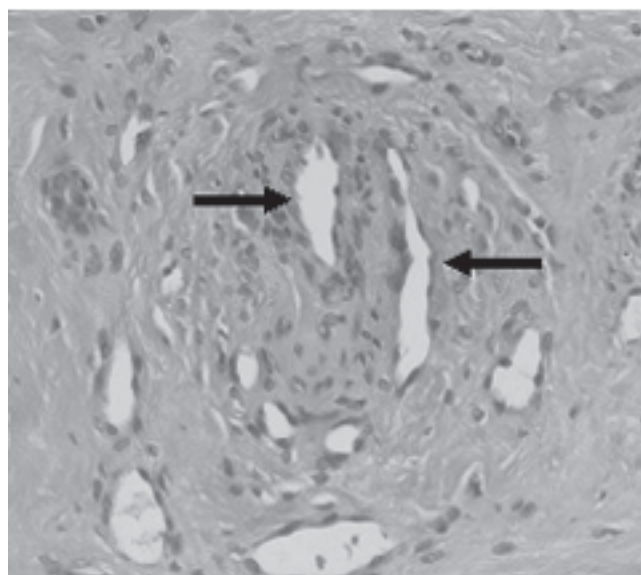


Fig. 2. The skin biopsy specimen contained cholesterol crystal clefts (arrows) within the occluded small vessel.

## DISCUSSION

CCE is a systemic disease caused by distal showering of cholesterol crystals after angiography, arterial catheterization, or major vessel surgery (3). The localized cutaneous presentation is known as blue toe syndrome. Renal insufficiency is the most common and the severest systemic complication, and progressive renal dysfunction is one of the major causes of death. Cholesterol emboli may also occur in patients treated with oral anticoagulants (4). It is known that warfarin potassium can produce blue toe syndrome. If such a patient takes warfarin, the medication should be suspended immediately (2, 5).

CCE may be diagnosed from the clinical symptoms following a PTCA procedure, and a skin biopsy showing cholesterol crystals in a small artery is crucial for the diagnosis (6, 7).

Various therapies have been attempted, including administration of corticosteroids and anti-platelet agents, but no treatment is known to be currently available. In many cases, renal failure from CCE requires haemodialysis (8). Funabiki et al. reported that up to 50% of the patients with CCE required dialysis and 33.3% succumbed (8).

PGE-1, a vasodilator, anti-platelet agent and a stimulator of angiogenesis, has been used for the treatment of arterial occlusive diseases (9, 10). Some patients with CCE have been treated with PGE-1, but its efficacy is controversial (10). Radauceanu et al. (12) reported that prostacyclin (prostaglandin I-2) was beneficial for cutaneous manifestations of CCE. Although the efficacy of treatment with PGE-1 in renal failure due to CCE has not been reported before, it was effective enough to prevent our patient from requiring haemodialysis. Administration of PGE-1 may be recommended as the initial treatment to prevent deterioration of renal function in the systemic type of CCE.

## REFERENCES

1. Ji-Tseng Fang, Chiu-Ching Huang. Blue toe syndrome associated with rapidly progressive glomerulonephritis: ultimately revealed essential mixed cryoglobulinemia. *Renal Failure* 1997; 19: 177–181.
2. Nakamoto S, Kaneda T, Inoue T, Matumoto T, Onoe M, Kitayama H, et al. Disseminated cholesterol embolism after coronary artery bypass grafting. *J Card Surg* 2001; 16: 410–413.
3. Fukumoto Y, Tsutsui H, Tsuchihashi M, Masumoto A, Takeshita A. The incidence and risk factors of cholesterol embolization syndrome, a complication of cardiac catheterization: a prospective study. *J Am Coll Cardiol* 2003; 42: 217–218.
4. Rauh G, Spengel FA. Blue toe syndrome after initiation of low-dose oral anticoagulation. *Eur J Med Res* 1998; 3: 278–280.
5. Moll S, Huffman J. Cholesterol emboli associated with warfarin treatment. *Am J Hematol* 2004; 77: 194–195.
6. Bashore TM, Gehrig T. Cholesterol emboli after invasive cardiac procedure. *J Am Coll Cardiol* 2003; 42: 217–218.
7. Zatsuchini J, Patel HK. The “blue toe” syndrome with renal atheroembolism and failure. *Angiology* 1985; 36: 209–214.
8. Funabiki K, Masuoka H, Shimizu H, Emi Y, Mori T, Ito M, Nakano T. Cholesterol crystal embolization after cardiac catheterization: a case report and a review of 36 cases in the Japanese literature. *Jpn Heart J* 2003; 44: 767–774.
9. Nishimura T, Nario K, Hosoi H. Effects of intravenous administration of prostaglandin E(1) and lipo-prostaglandin E(1) on cochlear blood flow in guinea pigs. *Eur Arch Otorhinolaryngol* 2002; 259: 253–256.
10. Mehrabi MR, Serbecic N, Tamaddon F, Kaun C, Huber K, Pacher R, et al. Clinical and experimental evidence of prostaglandin E1-induced angiogenesis in the myocardium of patients with ischemic heart disease. *Cardiovasc Res* 2002; 56: 214–224.
11. Milio G, Mina C, Cospite, Almasio PL, Novo S. Efficacy of the treatment with prostaglandin E-1 in venous ulcers of the lower limbs. *J Vasc Surg* 2005; 42: 304–308.
12. Radauceanu A, Avignon A, Ribstein J, Monnier L. Use of a prostacyclin analogue in cholesterol crystal embolism. *Diabet Med* 1998; 15: 262–263.