

CLINICAL REPORT

The Prevalence of Skin Disorders in Norwegian Paediatric Renal Transplant Recipients

Jan Cezary SITEK¹, Trine TANGERAAS², Anna BJERRE² and Per HELSING¹
Departments of ¹Dermatology, and ²Pediatrics, Oslo University Hospital, Oslo, Norway

A few key publications report on the frequency of skin disorders in paediatric organ transplant recipients in Southern and Central Europe presenting cumulative incidences. We aimed to estimate frequencies of skin disorders both as cumulative incidences and prevalence data, and describe skin problems in paediatric renal transplant recipients in a Norwegian renal transplant population. Clinical examination and review of post-transplant skin diseases were conducted in 70 patients having performed renal transplantation before the age of 16 in the period 1983–2006. Viral warts were a common and persistent problem, whereas bacterial and fungal infections in the skin were few. Drug-related skin disorders were rather frequent, but usually reversible on dose reduction or change of medication. Pre-malignant and malignant skin disorders appeared only in patients >30 years of age. Relatively high cumulative incidences and low prevalence data of most skin disorders were found in the examined patient cohort. Key words: children; immunosuppression; organ transplant recipients; skin disorders.

Accepted Aug 18, 2013; Epub ahead of print Nov 28, 2013

Acta Derm Venereol 2014; 94: 421–424.

Jan Cezary Sitek, Department of Dermatology, Oslo University Hospital, PO Box 4950 Nydalen, NO-0424 Oslo, Norway. E-mail: jsitek@ous-hf.no

The transplant population is steadily increasing as a result of both surgical and medical developments. Long-term morbidity and mortality of patients and grafts are improving, reflecting effective immunosuppressive regimens. The drawback of effective immunosuppression is an increased risk of infections (1) and cancer (2), in particular skin malignancies (3). This risk is increasing with time after transplantation (3, 4), putting paediatric organ transplant recipients (OTRs) at special risk. In addition, immunosuppressive medication may predispose to other skin problems as acne, hypertrichosis and gingival hyperplasia in paediatric OTRs (5, 6).

During the last 10 years, only 2 studies have described skin disorders in children with organ transplants; both studies describing the cumulative incidences (5, 6). The study by Euvrard et al. (5) describes skin diseases in 145 patients (117 renal transplant recipients (RTRs))

transplanted in childhood with a follow-up period up to 10 years. The other paper by Fortina et al. (6) reports 217 patients (168 RTRs) aged <18 years at transplantation followed up to 28 years after transplantation.

During the period 1970–2006, 251 renal transplantations were performed in 178 children in Norway. Children born after 1983 were invited to participate in a study, aiming to investigate long-term patient and graft survival (7), as well as cardiorespiratory fitness (8) and mental health (9) in paediatric RTRs. A part of the study was planned to describe the prevalence and cumulative incidences of skin disorders in this population. The Department of Dermatology at Oslo University Hospital keeps a specific outpatient clinic for OTRs. Our impression is that the paediatric OTR population runs a lower risk of skin disorders than previously reported (5, 6). This study aims at giving prevalence data, as well as cumulative incidences, to better describe the magnitude of skin problems in the paediatric RTR population.

MATERIALS AND METHODS

All patients were recruited from the HENT study (ClinicalTrials.gov NCT01008306). The patients were identified through the Norwegian Renal Registry, having their first renal transplant before 16 years of age in the period 1983–2006. Living recipients were invited to participate in a cross-sectional study involving a 2-day comprehensive medical investigational program, including an examination by a dermatologist.

A total of 70 patients were enrolled from May 2008 to June 2009, 68 patients having performed renal transplantation only and 2 patients having performed combined renal and liver transplantation. Seventy-three percent of the patients had received a kidney from a living donor. In the period 1983–1999, paediatric RTRs were treated with cyclosporine, either in conjunction with steroids, or as a triple regimen including azathioprine. From the year 2000, induction therapy with basiliximab was introduced, and the mainstay treatment was corticosteroids and inhibitors of calcineurin (tacrolimus after 2002).

Participants were interviewed by a nurse specialised in dermatology, registering previous skin disorders after transplantation in an extensive, structured questionnaire. Medical records and the questionnaire were reviewed by the dermatologist, adding current skin disorders after a total skin examination. Children <18 years and some older individuals were accompanied by a parent. Prior to study inclusion informed consent was obtained from participants if older than 16 years, or their parents younger than 16 years of age. All frequency data are presented as numbers and percentages.

The study protocol was approved by the Regional Ethical Committee and the study conducted in accordance with the Helsinki declaration.

RESULTS

Seventy patients were included, 61% male, 38 <19 years of age, with mean age at the time of investigation of 20.5 (3–41) years. Mean age at the time of transplantation was 8.9 (1–16) years; mean follow-up time for the group was 11.6 (2–29) years. Fifty-three percent of the participants were currently on a triple regimen, while the remaining patients were treated with 1 or 2 immunosuppressants (Table I).

Data are presented both in terms of self-reported cumulative incidences (questionnaire and interview) and prevalence data (clinical examination) (Table II).

Infectious diseases

Skin infections were the dominant disorder, both in terms of cumulative incidence and prevalence of disease. Six patients (8.6%) reported having no previous or current viral, fungal or bacterial skin disease. Current skin infection was present in 54.2% of the patients.

Fifty-two patients (74.3%) reported former or chronic problems with warts after transplantation (Fig. 1A). A cumulative incidence of 11.4% was observed for both condylomas and mollusci, condylomas being more prevalent in patients >20 years of age (Table II).

Fungal infections were rare in this population. No actual disease was observed, but some patients reported having had dermatophyte, candida and pityrosporum infections in the past (Table II).

Former bacterial infections were reported in 18.6% of patients, including impetigo contagiosa, folliculitis, facial furuncles, gingivitis, paronychias and long-standing

Table I. Patient characteristics of 70 paediatric renal transplant recipients

Characteristic	All patients (n=70)	≤18 years (n=38)	>18 years (n=32)
Age at first transplantation ^a	8.9 (± 4.8) 0.8–15.9	8.1 (± 0.6) 0.8–15.7	11.7 (± 3.6) 0.8–15.9
Age of allograft ^a	11.6 (± 7.8) 1.9–28.9	6.0 (± 3.6) 1.9–16.0	18.1 (± 6.3) 7.7–28.9
Age at investigation ^a	20.5 (± 10.1) 2.9–41.4	12.6 (± 4.2) 2.9–18.9	29.9 (± 6.4) 19.3–41.4
Treatment protocol, % (n)			
Mono/duo	47.1 (33)	68.4 (26)	22.0 (7)
Triple	52.9 (37)	31.6 (12)	78.0 (25)
Living donor, % (n)			
Yes	74.3 (52)	84.2 (32)	62.5 (20)
No	25.7 (18)	15.8 (6)	37.5 (12)
No of transplants, % (n)			
1	68.6 (48)	86.8 (33)	46.9 (15)
2	25.7 (18)	13.2 (5)	40.6 (13)
≥3	5.7 (4)	0	12.5 (4)

^aAge in years, mean age (95% confidence interval).

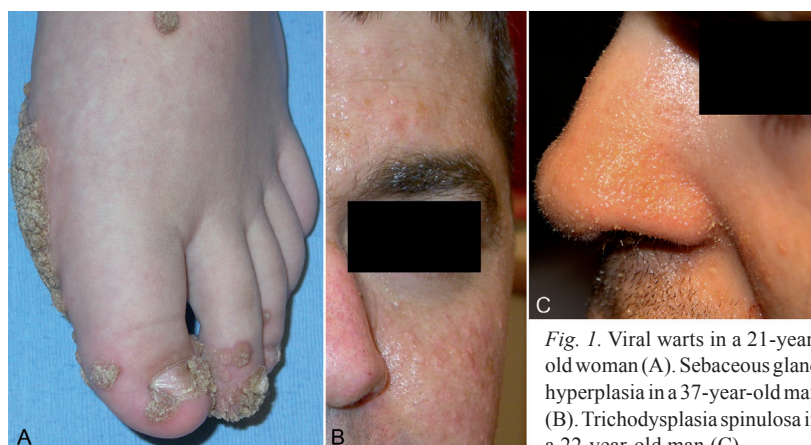


Fig. 1. Viral warts in a 21-year-old woman (A). Sebaceous gland hyperplasia in a 37-year-old man (B). Trichodysplasia spinulosa in a 22-year-old man (C).

skin infections after insect-bites. One patient showed signs of bacterial infection on examination, diagnosed as bacterial folliculitis (Table II).

Drug induced skin disorders

Drug induced skin disorders were frequent and mainly attributed to the use of steroids and cyclosporine (Table II).

Striae distensa (24.3%) and acne (18.6%) were the most frequent disorders discovered on examination, mainly attributed to the use of prednisolone. Cushingoid facies was found in 3 patients (4.3%). Hypertrichosis and gingival hyperplasia are common side effects of cyclosporine, and rather frequently reported as a serious

Table II. Cumulative incidence (CumI) and point prevalence (PP) of skin disorders in paediatric renal transplant recipients

	CumI, n=70 % (n)	PP, n=70 % (n)
Infectious diseases		
Viral warts	74.3 (52)	48.6 (34)
Condylomas	11.4 (8)	5.7 (4)
Mollusci	11.4 (8)	5.7 (4)
Herpes simplex virus infections	30 (21)	2.9 (2)
Varicella zoster virus infection	12.9 (9)	0
Pityriasis versicolor	2.9 (2)	0
Dermatophyte infections	8.6 (6)	0
Candidal infection (oropharyngeal)	2.9 (2)	0
Bacterial skin infections	18.6 (13)	1.4 (1)
Drug induced		
Striae distensa	not applicable	24.3 (17)
Sebaceous gland hyperplasia	not applicable	8.6 (6)
Acne	not applicable	18.6 (13)
Cushingoid facies	not applicable	4.3 (3)
Hypertrichosis, serious	20 (14)	1.4 (1)
Gingival hyperplasia, serious	7.1 (5)	0
Precancerous and cancer lesions (skin)		
Actinic keratosis	4.3 (3)	1.4 (1)
Keratoacanthoma	1.4 (1)	0
Carcinoma <i>in situ</i>	1.4 (1)	0
Basal cell carcinoma	1.4 (1)	0
Squamous cell carcinoma/malignant melanoma	0	0
Other		
Naevi count >50	not applicable	15.7 (11)
Eczema (atopic, irritative)		22.9 (16)
Xerosis symptomatic		14.3 (10)

problem in this cohort with a cumulative incidence of 20% and 7.1%, respectively. Most of these problems were managed by dose reduction or by switching to tacrolimus. Sebaceous gland hyperplasia was found exclusively in adults over 22 years of age (Fig. 1B).

Skin precancerous/cancer lesions

Precancerous and cancer lesions were reported in 5 patients (7.1%), all being >30 years of age.

Three patients (4.3%) had been treated for actinic keratoses, one for keratoacanthoma and one for carcinoma *in situ*, all histology proven. One of these had also been treated for 5 basal cell carcinomas. Stucco-like keratoses were observed in all 5 patients. No patients had a history of squamous cell carcinoma, melanoma or other skin associated cancers (Table II).

Miscellaneous

Other skin complaints were registered, being mostly symptomatic dry skin (14.3%) and eczema (22.9%). Approximately half of the subjects (49%) had a total naevi count less than 25 (Table II).

Less frequent findings included pitted keratolysis, trichodysplasia spinulosa (Fig. 1C) and acral acanthosis nigricans.

DISCUSSION

Viral warts were the predominant skin disorder, with high reported cumulative incidence and prevalence on examination. Other rather frequent current disorders were acne and striae distensa. However, our results show that most paediatric RTRs had relatively few skin complaints and few current disorders, indicating that most conditions are manageable.

The present study differs on several aspects from the previous studies. Our study population of 70 RTRs is smaller than the studies by Euvrard et al. (5) ($n=145$) and Fortina et al. (6) ($n=217$). Our follow-up time after transplantation is longer, with mean age of allograft being 11.6 years, as compared to 6.6 years and 1 month–10 years in the studies by Fortina et al. and Euvrard et al., respectively. In addition, these studies only reported on cumulative incidences.

Viral warts were quite frequent, showing cumulative incidence of 74.2%. Viral warts are relatively common also among Scandinavian secondary school pupils. Prevalences of 20% have been reported among adolescents (10) as compared to a prevalence of 45% in our study population below 18 years of age. Warts were predominantly located on hands and feet, with increasing involvement of hands with age. Both high cumulative incidence and prevalence show that viral warts in the transplant population are difficult to treat. Most patients had tried different treatment strategies, including repetitive liquid

nitrogen cryotherapy, imiquimod under occlusion and laser therapy, however with a low success rate. Onset of viral warts in formerly naive patients was 1.6 years after transplantation (Table III). In patients ≤ 18 years of age, absence of viral wart infection was exclusively seen in patients following the mono or duo immunosuppressive treatment protocol (Table IV). These observations may indicate that intensity of immunosuppressive therapy is of importance for the development of viral warts.

The occurrence of both mollusci and condylomas was also higher than previously reported (5, 6). Both conditions were actively searched for in our study and may easily be overlooked by routine examination without specifically addressing the condition. Mollusci debuted primarily during adolescence whereas condylomas typically occurred in adult age (Table III). Similarly to viral warts both conditions seem hard to eradicate, as half of patients reporting previous infection presented current disease, which may be due to immunosuppression.

Nearly 1/3 of the patients reported having suffered from herpes simplex infection, with median onset 1.7 years after transplantation. Herpes simplex virus (HSV) is however also common in the general population with a British study reporting a 17–27% HSV-1 prevalence in children aged 1–14 years (11). Among the 8 naive patients reporting varicella zoster infection, median onset was 5.7 years post-transplant, one patient experiencing multiple episodes (Table III).

Pityriasis versicolor was a frequent finding in previously referred studies, with cumulative incidences of 20.7% and 14.5%, respectively (5, 6). No patients in our cohort were diagnosed with ongoing fungal infection. A possible explanation could be different climate conditions (12).

Bacterial skin infections were rare in this cohort; impetigo and folliculitis being the most frequent complaints, but none experiencing recurrent episodes. Median onset was more than 10 years after transplantation (Table III).

A considerable part of the paediatric RTRs reported drug related skin manifestations on examination, which

Table III. Debut of skin diseases after renal transplantation in disease-naive paediatric renal transplant recipients

Skin diseases (in order of frequency)	Age (years) at debut	Age (years) of allograft at debut
	Median	Median
Viral warts, $n=38$	11.8	1.6
Herpes simplex virus infection, $n=15$	13	1.7
Striae distensa, $n=13$	14	1.8
Condylomas, $n=8$	22	10
Mollusci, $n=8$	12.5	5.8
Varicella zoster virus infection, $n=8$	18	5.7
Bacterial infection, $n=6$	22.5	10.9
Sebaceous gland hyperplasia, $n=4$	31	18.8
Dermatophyte infection, $n=4$	12.5	2.5
Actinic keratosis, $n=3$	30	18
Oropharyngeal candida, $n=2$	25	13
Pityriasis versicolor, $n=2$	15.5	3.1
Basal cell carcinoma, $n=1$	32	20
Carcinoma <i>in situ</i> , $n=1$	36	24

Table IV. *Viral wart infection and immunosuppressive regime in paediatric renal transplant recipients (≤ 18 years of age at investigation time)*

	Mono/dual therapy ^a n=26	Triple therapy ^b n=12	p-value ^c
Warts never, n	13	0	0.004
Warts present/past, n	13	12	ns

^atacrolimus- or cyclosporinebased therapy. ^bcyclosporine-, tacrolimus- and/or mycophenolat mofetilbased therapy. ^cFisher exact test. ns: not significant

is in accordance with previous studies (5, 6, 13, 14). Striae distensa and acne, considered side effects of steroids, were the dominant findings. Striae was found in almost 1/4 of the patients. Some patients reported onset of striae before transplantation, frequently attributed to high-dose corticosteroid treatment due to their primary kidney disease. Interestingly, a similar prevalence value (27%) was found in healthy Scandinavian adolescents (10), indicating that age and puberty may well be as important as corticosteroid treatment for the development of striae in this age group. Nearly 1/5 of the patients had acne on examination. A discrimination between drug- and adolescence-associated acne was not performed, which makes comparison with previous studies difficult.

Current cyclosporine-related skin disorders were few. A rather high frequency of hypertrichosis and serious gingival hyperplasia was reported, but these conditions were reversible on dose reduction or discontinuation of cyclosporine, and only one patient had serious hypertrichosis on examination. Sebaceous gland hyperplasia was observed exclusively among adult patients of both sexes, with median onset 18.8 years after transplantation (Table III).

Development of pre-malignant and malignant skin lesions is a major concern in the transplant population, and should be of special concern in the paediatric population, since risk of precancerous lesions and cancer is related to time after transplantation and total immunosuppressive load (3, 4). We found precancerous and cancerous lesions only in adult patients with onset when they were between 30–40 years of age (Table III). Whether these observations are higher than expected is unclear as standardised incidence ratios are not obtainable due to lack of national age-specific incidence rates for actinic keratosis, basal cell carcinoma and carcinoma *in situ*. Longer follow-up time may explain the higher frequency of these lesions in our cohort, as may constitutional differences. Our study population most likely has lighter skin phototypes compared to participants in the South European studies, which increases the risk of skin cancers. However, the limited number of patients restricts conclusions. The patient with 5 basal cell carcinomas has been examined for Gorlin-Goltz syndrome, presenting no other clinical signs of this disease.

Limitations to this study are the rather few patients compared to previous studies (5, 6), and that data on cumulative incidence is largely based on self-report or

comparant information. Further, our prevalence data are based on a sample of the total paediatric RTR population and could be subject to sampling bias.

In conclusion, our study adds important information on skin disorders in paediatric RTRs. Current status show that prevalence of skin disorders is generally low, with an exception for viral warts and certain steroid-induced skin manifestations. The development of pre-malignant and malignant skin lesions in adult age is still a major concern, and preventive strategies should be addressed at follow-up.

ACKNOWLEDGEMENTS

The authors thank dr Cato Mørk for his contribution during the early phases of the study. We also thank nurses Liv Irene Eikefjord and Anita Jacobsen for their contribution to collecting patient data.

REFERENCES

- Boyle J, MacKie RM, Briggs JD, Junor BJ, Aitchison TC. Cancer, warts, and sunshine in renal transplant patients. A case-control study. *Lancet* 1984; 1: 702–705.
- Webster AC, Craig JC, Simpson JM, Jones MP, Chapman JR. Identifying high risk groups and quantifying absolute risk of cancer after kidney transplantation: a cohort study of 15,183 recipients. *Am J Transplant* 2007; 7: 2140–2151.
- Jensen P, Hansen S, Møller B, Leivestad T, Pfeffer P, Simonsen S, et al. Skin cancer in kidney and heart transplant recipients and different long-term immunosuppressive therapy regimens. *J Am Acad Dermatol* 1999; 40: 177–186.
- Lindelöf B, Sigurgeirsson B, Gäbel H, Stern RS. Incidence of skin cancer in 5356 patients following organ transplantation. *Br J Dermatol* 2000; 143: 513–519.
- Euvrard S, Kanitakis J, Cochat P, Cambazard F, Claudy A. Skin diseases in children with organ transplants. *J Am Acad Dermatol* 2001; 44: 932–939.
- Fortina AB, Piaserico S, Alaibac M, Caforio AL, Brandolisio L, Peserico A, et al. Skin disorders in patients transplanted in childhood. *Transpl Int* 2005; 18: 360–365.
- Tangeraas T, Bjerre A, Lien B, Kyte A, Monn E, Reisaeter AV, et al. Long-term outcome of pediatric renal transplantation: the Norwegian experience in three eras 1970–2006. *Pediatr Transplant* 2008; 12: 762–768.
- Tangeraas T, Midtvedt K, Cvancarova M, Hirth A, Fredrikson PM, Bjerre A, et al. Cardiorespiratory fitness in young adults with a history of renal transplantation in childhood. *Pediatr Nephrol* 2011; 26: 2041–2049.
- Diseth TH, Tangeraas T, Reinjfjell T, Bjerre A. Kidney transplantation in childhood: mental health and quality of life of children and caregivers. *Pediatr Nephrol* 2011; 26: 1881–1892.
- Larsson PA, Lidén S. Prevalence of skin diseases among adolescents 12–16 years of age. *Acta Derm Venereol* 1980; 60: 415–423.
- Smith JS, Robinson NJ. Age-specific prevalence of infection with herpes simplex virus types 2 and 1: A global review. *J Infect Dis* 2002; 186: S3–28.
- Gupta AK, Bluhm R, Summerbell R. Pityriasis versicolor. *J Eur Acad Dermatol Venereol* 2002; 16: 19–33.
- Halpert E, Tunnessen WW Jr, Fivush B, Case B. Cutaneous lesions associated with cyclosporine therapy in pediatric renal transplant recipients. *J Pediatr* 1991; 119: 489–491.
- Menni S, Beretta, Piccinno R, Ghio L. Cutaneous and oral lesions in 32 children after renal transplantation. *Pediatr Dermatol* 1991; 8: 194–198.